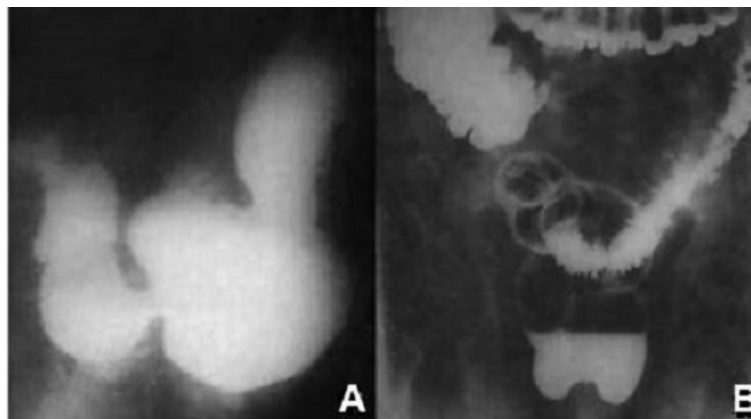


## Photoclinic



**Figure 1.** Upper and Lower Radiographic Study with Barium Contrast Showing Gastric Hypotonia, Delayed Emptying, Dilatation, and Morphologic Change (A); Moderate Cecal and Rectosigmoid Dilations, and Diverticulosis (B).

A 57-year-old Brazilian man from a poor rural area came to our outpatient service with a longstanding history of weakness, anorexia, loss of weight, epigastric pain, and intestinal obstipation. Episodes of postprandial pain were sometimes intense and alleviated by taking the prone position or following either belching or vomiting. Usual self-medication included analgesics and diverse homemade herbal teas. He was a farmworker, smoker (10 pack-years) and alcohol drinker, living in an adobe house and very far from access to an adequate health service. His physical examination revealed emaciation with body mass index: 16.5 kg/m<sup>2</sup>, pale mucosa, and borborygmi in the epigastric region. The

rest of examination was unremarkable. Except for mild anemia, routine laboratory tests were within the normal range. Plain chest radiography and electrocardiogram were within normal parameters. Upper and lower gastrointestinal radiographic study with barium contrast showed gastric hypotonia, delayed emptying, dilatation, and morphologic change (Figure 1A) in addition to moderate cecal and rectosigmoid dilations, and diverticulosis (Figure 1B). Taken as a whole, the described data were useful to characterize the final clinical diagnosis. Complementary laboratory determinations confirmed the etiology of this condition.

**What is your diagnosis?  
See the next page for your diagnosis.**

Received: August 28, 2020, Accepted: October, 4, 2020, ePublished: January 1, 2021

**Vitorino Modesto dos Santos, MD, PhD<sup>1</sup>; Lister Arruda Modesto dos Santos, MD<sup>2</sup>; Jânio Wagner Pinheiro Lopes, MD<sup>3</sup>**

<sup>1</sup>Medicine Department, Armed Forces Hospital and Catholic University, Brasília-DF, Brazil

<sup>2</sup>General Surgery Department, State Worker's Hospital, São Paulo-SP, Brazil

<sup>3</sup>Radiology Service, Armed Forces Hospital, Brasília-DF, Brazil

\*Corresponding Author: Vitorino Modesto dos Santos, MD, PhD; Armed Forces Hospital, Estrada do Contorno do Bosque s/n, Cruzeiro Novo, CEP 70.658-900, Brasília-DF, Brasil. Tel: +55 61-39662103; Fax: +55 61-32331599. Email: vitorinomodesto@gmail.com

Cite this article as: dos Santos VM, dos Santos LAM, Lopes JWP. Photoclinic. Arch Iran Med. 2021;24(1):84-85. 10.34172/aim.2021.12.

## Photoclinic Diagnosis

### Hourglass stomach in Chagas disease

#### Authors' Contribution

VMS and LAMS participated on the conception and design, collection and interpretation of data, literature search, and writing and review of the manuscript. JWPL involved in radiology interpretation and reworking the manuscript.

#### Conflict of Interest Disclosures

The authors had full freedom of manuscript preparation and there were no potential conflicts of interest.

#### Ethical Statement

In writing the manuscript, the authors followed the policy of the Committee on Publication Ethics (COPE).

#### Funding

There was no grant support.

#### Acknowledgments

The authors would like to thank Almir José Batista, a specialized photographer in Medical Imaging Documentation from Brasília-DF, Brazil for the images that illustrate this manuscript.

#### References

1. Figueirêdo SS, Carvalho TN, Nóbrega BB, Ribeiro FAS, Teixeira KS, Ximenes CA. Caracterização radiográfica das manifestações esofagogastrointestinais da doença de chagas. *Radiol Bras.* 2002;35(5):293-297. doi: 10.1590/S0100-39842002000500009.
2. Lopes ER, Rocha A, Meneses ACO, Lopes MAA, Fatureto MC, Lopes CP, et al. Prevalência de megas em necropsias realizadas no Triângulo Mineiro no período de 1954 a 1988. *Rev Soc Bras Med Trop.* 1989;22(4):211-215. doi: 10.1590/S0037-86821989000400008.
3. Cabrine-Santos M, dos Santos VM, de Lima MA, de Abreu ME, Lages-Silva E, Ramirez LE. Genitourinary changes in hamsters infected and reinfected with *Trypanosoma cruzi*. *Mem Inst Oswaldo Cruz.* 2003;98(4):523-8. doi: 10.1590/s0074-02762003000400018.
4. dos Santos VM, de Lima MA, Cabrine-Santos M, de Stefani Marquez D, de Araújo Pereira G, Lages-Silva E, et al. Functional and histopathological study of the pancreas in hamsters (*Mesocricetus auratus*) infected and reinfected with *Trypanosoma cruzi*. *Parasitol Res.* 2004;94(2):125-33. doi: 10.1007/s00436-004-1183-8.
5. Lidani KCF, Andrade FA, Bavia L, Damasceno FS, Beltrame MH, Messias-Reason IJ, et al. Chagas disease: from discovery to a worldwide health problem. *Front Public Health.* 2019;7:166. doi: 10.3389/fpubh.2019.00166.
6. Brinton W. Royal Free Hospital: Five ulcers of the stomach: with hypertrophy and dilatation from a cicatrix occupying the pylorus, and hour-glass contraction from a cicatrix in the lesser curvature. *Assoc Med J.* 1856;4(203):989-92. doi: 10.1136/bmj.s3-4.203.989.
7. Moir A. Hour glass stomach. *Can Med Assoc J.* 1922;12(1):20-24.
8. Nayak BS, Kumar N, Bincy M, Mishra S, Rao S, Shetty SD, et al. An atypical "Hourglass" stomach due to the presence of an unusual incisure at the greater curvature. *Online J Health Allied Sci.* 2017;16(1):1-3.
9. Swargam N. Hour-glass constriction of stomach - a cadaveric study with surgical explanation. *Int J Adv Res.* 2019;7(5):625-629. doi: 10.21474/IJAR01/9082.