

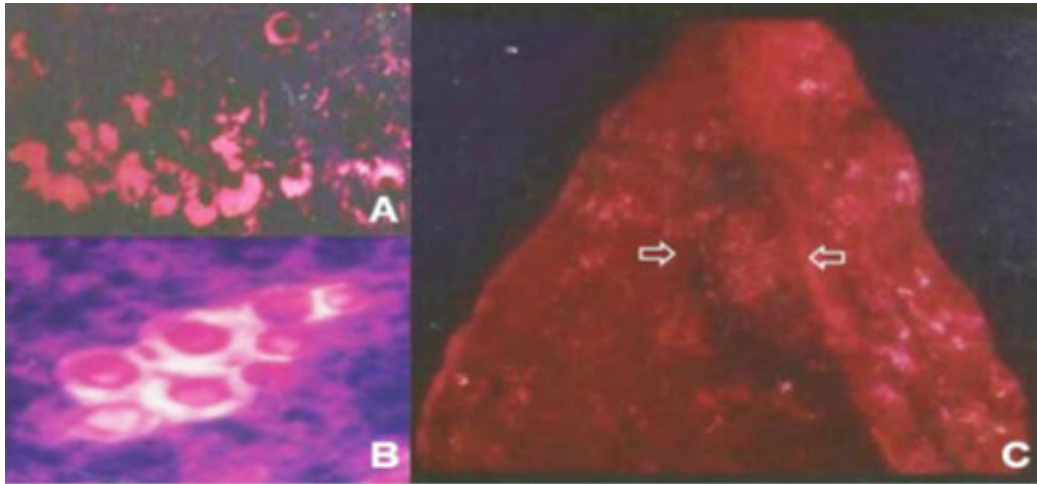
Photoclinic

Figure 1. Macroscopic View of the Pulmonary Specimen, and the Microbiological Findings. (A and B) Photomicrography of pulmonary specimens revealing spherical structures strongly highlighted by metachromatic toluidine blue staining and presenting thick clear capsules; and (C) Gross view of the excised pulmonary segment with a delimited spongy lesion (arrows).

A previously healthy 46-year-old male referred to the hospital with low-grade fever and loss of appetite, as well as a productive cough with clear expectoration for three months. He was a chronic smoker (20 pack-years) and worked in close contact with soil and poultry. On admission, he was eutrophic and the rest of his physical examination was unremarkable. Routine laboratory exploration yielded results within normal ranges. Additionally, sputum examination was negative for microorganisms and malignant cells. On the other hand, plain chest radiography revealed nodularity in the right lower lobe (not shown). With clinical suspicion of primary malignant lesion associated with smoking, a percutaneous

pulmonary biopsy was performed and the samples were sent for histopathological evaluation. Microscopy with Hematoxylin and eosin (H&E) staining showed oval to round thick-walled microorganisms within the alveoli surrounded by conspicuous non-stained clear mucoid capsules, whereas melanin was detected in the cell wall of these agents by Fontana-Masson method. Microorganisms were metachromatically stained by toluidine blue staining, except their capsules (Figures 1A and 1B), and the etiological diagnosis was established. The nodular lesion of the lung was excised (Figure 1C), and the patient underwent long-term antimicrobial treatment.

**What is your diagnosis?
See the next page for your diagnosis.**

Received: June 7, 2018, Accepted: July 7, 2019, ePublished: October 1, 2019

Vitorino Modesto dos Santos, VM, MD, PhD^{1*}

¹Catholic University and Armed Forces Hospital, Brasília-DF, Brazil.

***Corresponding Authors:** Vitorino Modesto dos Santos, VM, MD, PhD; Armed Forces Hospital, Estrada do Contorno do Bosque s/n, Cruzeiro Novo, CEP 70.658-900, Brasília-DF, Brazil. Tel: +55-61 39662103, Fax: +55-61 32331599, Email: vitorinomodesto@gmail.com

Cite this article as: dos Santos VM. Photoclinic. Arch Iran Med. 2019;22(10):629-630.

■ Photoclinic Diagnosis

Pulmonary Cryptococcosis

Here, a healthy immunocompetent male patient is described with nonspecific clinical manifestations and nodularity in the lung, raising the hypothesis of cancer. Primary lung cancer was the major initial concern because of the antecedent tobacco use. Non-invasive evaluation did not clear the diagnostic challenges, but histopathological studies of lung biopsy samples detected the presence of *Cryptococcus* spp. within the alveoli. The pulmonary nodule was then properly resected by thorascopic segmentectomy and the patient underwent a postoperative course of fluconazole (400 mg daily, for 6 months). Currently, he remains without symptoms and under periodic clinical and imaging follow-up.

Cryptococcosis is a severe mycosis that affects immunocompromised individuals, with pulmonary, meningeal, and systemic involvement.¹⁻⁴ With lower frequency, pulmonary cryptococcosis has been also described in immunocompetent hosts, and may present a diagnostic challenge based on clinical and imaging findings alone.¹⁻⁴ As nodular lesions are more common in this picture, primary and metastatic tumors are major differential diagnoses.¹⁻⁴ Therefore, invasive procedures might be necessary to avoid misdiagnosis and late diagnosis.¹⁻⁴ Routine investigations should include sputum smear and cultures; computed tomography (CT) and PET-CT of the thorax; panel of immunodeficiency conditions in general, and HIV infection in special.¹⁻⁴ Immunosuppressive drugs and smoking can also have a role.¹⁻⁴ Serological tests for cryptococcal antigen and search for this agent in tissues, sputum, blood, urine and cerebrospinal fluid are useful tools to confirm the suspected diagnosis of cryptococcosis.¹⁻⁴ The metachromatic dyes more frequently utilized are basic or cationic, including the toluidine blue (blue-purple-red) which, in this case, revealed the yeast forms of *Cryptococcus* spp. The patient

was probably infected via the respiratory route in his usual environment, because the fungus may be commonly found in soil and bird droppings.¹⁻⁴ This pulmonary cryptococcosis was diagnosed in an immunocompetent individual and successfully managed by surgery in addition to fluconazole for 6 months.¹⁻³

Authors' Contribution

The author participated in the conception and design, collection and interpretation of data, literature search, and writing and review of the manuscript.

Conflict of Interest Disclosures

The author had full freedom of manuscript preparation and there were no potential conflicts of interest.

Ethical Statement

In writing the manuscript, the author followed the policy of the Committee on Publication Ethics (COPE). An informed consent was obtained from the patient for photographs and publication of this photoclinic.

Funding

There was no grant support for this study.

References

1. Anandpara KM, Aswani Y, Hira P. Large solitary pulmonary cryptococcoma mimicking lung carcinoma in an immunocompetent patient. *Malays J Med Sci*. 2018;25(1):114-8. doi: 10.21315/mjms2018.25.1.13.
2. Kanjanapradit K, Kosjerina Z, Tanomkiat W, Keeratichananont W, Panthuwong S. Pulmonary cryptococcosis presenting with lung mass: report of 7 cases and review of literature. *Clin Med Insights Pathol*. 2017;10:1179555717722962. doi: 10.1177/1179555717722962.
3. Yu JQ, Tang KJ, Xu BL, Xie CM, Light RW. Pulmonary cryptococcosis in non-AIDS patients. *Braz J Infect Dis*. 2012;16(6):531-9. doi: 10.1016/j.bjid.2012.07.004.
4. Xie X, Xu B, Yu C, Chen M, Yao D, Xu X, et al. Clinical analysis of pulmonary cryptococcosis in non-HIV patients in south China. *Int J Clin Exp Med*. 2015;8(3):3114-9.



© 2019 The Author(s). This is an open-access article distributed under the terms of the Creative Commons Attribution License (<http://creativecommons.org/licenses/by/4.0>), which permits unrestricted use, distribution, and reproduction in any medium, provided the original work is properly cited.