

## Case Report

# A Rare Cytogenetic Variant of Monosomy 18p Syndrome as a Consequence of Whole-Arm Translocation between Chromosomes 13 and 18

Moeinadin Safavi, MD<sup>1\*</sup>, Mohammad Taghi Haghi Ashtiani, MD<sup>1</sup>; Reza Shervin Badv, MD<sup>2</sup>; Aileen Azari-Yam, MD<sup>1</sup>; Mohammad Vasei, MD<sup>1\*</sup>

<sup>1</sup>Molecular Pathology and Cytogenetics Division, Pathology Department, Children's Medical Center, Tehran University of Medical Sciences, Tehran, Iran

<sup>2</sup>Pediatric Neurology Department, Children's Medical Center, Tehran University of Medical Sciences, Tehran, Iran

## Abstract

Monosomy 18p syndrome is one of the prototypical examples of autosomal terminal deletions. This deletion can be the consequence of *de novo* deletions, malsegregation of a balanced parental translocation, cryptic subtelomeric deletions or ring chromosome 18. The present case is a rare cytogenetic variant of monosomy 18 as a consequence of whole-arm translocation between chromosomes 13 and 18 which has been reported only three times previously.

**Keywords:** 18p deletion syndrome, Genetic, Translocation

**Cite this article as:** Safavi M, Haghi Ashtiani MT, Badv RS, Azari-Yam A, Vasei M. A rare cytogenetic variant of monosomy 18p syndrome as a consequence of whole-arm translocation between chromosomes 13 and 18. Arch Iran Med. 2019;22(10):627-628.

Received: December 13, 2018, Accepted: September 1, 2019, ePublished: October 1, 2019

## Introduction

Monosomy 18p is the first described partial monosomy in live offspring with an incidence of 1 in 50 000. Its usual clinical presentation includes intellectual disability, short stature, round face, ptosis and short philtrum.<sup>1</sup> Here, we present a rare cytogenetic variant of the 18p deletion syndrome which merits attention.

## Case Report

The patient was a 1.5-year-old boy with seizure and congenital heart disease. He was the first child of non-consanguineous parents. He had dysmorphic facial features including brachycephaly, hypertelorism, ptosis, protruding eyes, and hypodontia. He also had global developmental delay, especially prominent delayed speech. His congenital heart anomalies included patent ductus arteriosus, pulmonary atresia, and ventricular septal defect. His seizure occurred in the neonatal period and repeated once. His brain magnetic resonance imaging (MRI) revealed no structural abnormalities.

Cytogenetic study on peripheral blood revealed an unbalanced translocation between the long arms of chromosome 13 and chromosome 18 leading to deletion of the short arm of chromosome 18 (Figure 1).

## Discussion

The patient was a 1.5-year-old boy with deletion of 18p

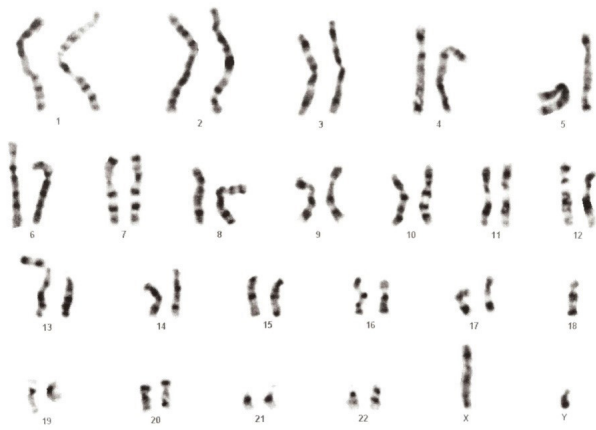
as a consequence of unbalanced translocation between chromosomes 13 and 18 and typical manifestations of monosomy 18p syndrome.

Monosomy 18p syndrome is one of the prevalent terminal deletions and it has been reported more than 150 times.<sup>1</sup> Deletion of chromosome 18 short arm can be either complete or partial.<sup>2</sup> It can have different cytogenetic mechanisms including *de novo* deletions (two thirds), malsegregation of a balanced parental translocation, ring chromosomes, cryptic subtelomeric deletions, inheritance of 18p deletion from one of the parents, or unbalanced whole-arm translocation as the present case.<sup>3-6</sup>

Monosomy 18p in association with whole-arm translocation has been described in more than 20 patients previously. Only three cases of whole-arm translocation (13;18) associated with monosomy 18 p have been registered in literature. The first case was a patient with large ears, asymmetric face and polysplenia.<sup>7</sup> The second case was a 7-year-old girl with the typical presentation of monosomy 18p syndrome including mental retardation, short stature, prominent ears, ptosis and dental caries.<sup>8</sup> The last one was a female with midline defects.<sup>9</sup> The present case showed the usual manifestations of the monosomy 18p syndrome in addition to congenital heart disease which is not common in this syndrome.

Whole-arm translocation between chromosomes 13 and 18 can be the underlying cytogenetic aberration in

\*Corresponding Authors: Moeinadin Safavi, MD; Molecular Pathology and Cytogenetics Division, Pathology Department, Children's Medical Center, Tehran University of Medical Sciences, Tehran, Iran. Email: safavi\_moeinadin@yahoo.com  
Mohammad Vasei MD, Molecular Pathology and Cytogenetics Division, Pathology Department, Children's Medical Center, Tehran University of Medical Sciences, Tehran, Iran. Email: mvasei@tums.ac.ir



**Figure 1.** Cytogenetic Study on Peripheral Blood Revealed 45,XY,der(13;18)(q10;q10).

monosomy 18p syndrome. Congenital heart disease and seizure should be considered as occasional manifestations of monosomy 18p syndrome.

#### Authors' Contribution

MS, MHA, RB, AA, and MV: drafting the manuscript and diagnosing the syndrome.

#### Conflict of Interest Disclosures

None.

#### Ethical Statement

Informed consent was obtained from the patient's guardian.

#### References

1. Turleau C. Monosomy 18p. *Orphanet J Rare Dis.* 2008;3:4. doi: 10.1186/1750-1172-3-4.
2. Schaub RL, Reveles XT, Baillargeon J, Leach RJ, Cody JD. Molecular characterization of 18p deletions: evidence for a breakpoint cluster. *Genet Med.* 2002;4(1):15-9. doi: 10.1097/00125817-200201000-00003
3. Horsley SW, Knight SJ, Nixon J, Huson S, Fitchett M, Boone RA, et al. Del (18p) shown to be a cryptic translocation using a multiprobe FISH assay for subtelomeric chromosome rearrangements. *J Med Genet.* 1998;35(9):722-6. doi:10.1136/jmg.35.9.722
4. Stankiewicz P, Brozek I, Hélias-Rodzewicz Z, Wierzbica J, Pilch J, Bocian E, et al. Clinical and molecular-cytogenetic studies in seven patients with ring chromosome 18. *Am J Med Genet.* 2001;101(3):226-39. doi: 10.1002/1096-8628(20010701)101:3<226::aid-ajmg1349>3.0.co;2-#
5. Misceo D, Ørstavik KH, Lybæk H, Sandvig I, Ormerod E, Houge G, et al. Inheritance of a terminal 7.1 Mb 18p deletion flanked by a 2.3 Mb duplication from a physically normal mother. *Am J Med Genet A.* 2009;149A(12):2877-81. doi: 10.1002/ajmg.a.33106.
6. Wang JC, Nemana L, Kou SY, Habibian R, Hajianpour MJ. Molecular cytogenetic characterization of 18; 21 whole arm translocation associated with monosomy 18p. *Am J Med Genet.* 1997;71(4):463-6.
7. Einfeldt SE, Muneer RS, Rennert OM. Polysplenia associated with monosomy 18p. *Am J Hum Genet.* 1983;35(6):130.
8. Thompson RW, Peters JE, Smith SD. Intellectual, behavioral, and linguistic characteristics of three children with 18p-syndrome. *J Dev Behav Pediatr.* 1986;7(1):1-7.
9. Taine L, Goizet C, Wen ZQ, Chateil JF, Battin J, Saura R, et al. 18p monosomy with midline defects and a de novo satellite identified by FISH. *Ann Genet.* 1997;40(3):158-63.