

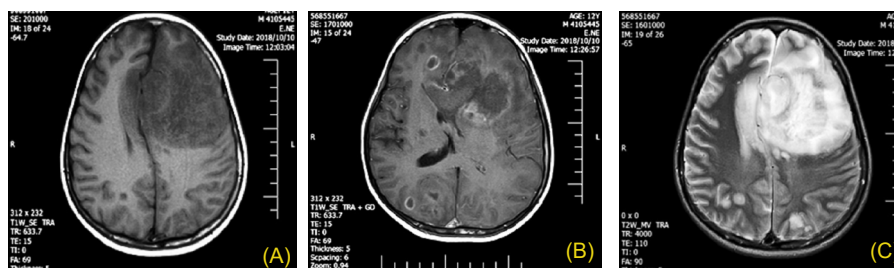Photoclinic

Figure 1. (A) T1 weighted MRI images revealed multiple hypointense brain lesions with a random distribution. (B) Post contrast T1 weighted MRI image showed multiple ring enhanced brain lesions. (C) T2 weighted brain images exhibited multiple hyperintense brain lesions with hypointensity at the periphery.

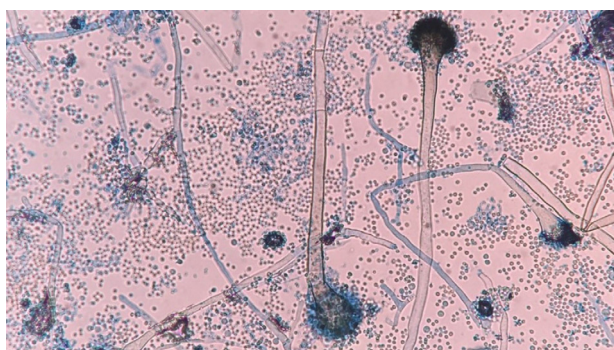


Figure 2. Culture of brain abscess on Sabouraud Dextrose Agar revealed organisms with fruiting heads and conidia (Lactophenol aniline blue).

The patient was a 12-year-old boy who presented with loss of consciousness and right hemiparesis four days after liver transplantation. The patient had received immunosuppressive drugs like methylprednisolone 1 g daily on the first three days of transplantation and 2 mg/

kg/d afterward, tacrolimus 4 mg daily from the second day after transplantation and mycophenolate mofetil 500 mg daily from the second day after transplantation. Paraclinical evaluation revealed leukocytosis, anemia, thrombocytopenia, and elevated erythrocyte sedimentation rate. Brain MRI revealed multiple brain abscesses in both frontal and parietal lobes which were hypointense in T1 weighted images with peripheral edema, and hyperintense in T2 weighted images along with hypointensity in periphery and showed ring enhancement in post contrast T1 weighted images (Figures 1A-C).

Subsequently, a burr hole was placed on left frontal lobe after general anesthesia and brain abscess was cannulated and pus-like fluid was evacuated. The pus-like fluid cytological smear revealed hyaline branching hyphae and its culture showed organisms with fruiting heads composed of round vesicles covered by the phialides and conidia (Figure 2). In spite of treatment with voriconazole and amphotericin B, the patient expired in intensive care unit after 50 days.

**What is your diagnosis?
See the next page for your diagnosis.**

Received: March 12, 2019, Accepted: May 15, 2019, ePublished: August 1, 2019

Moeinadin Safavi, MD^{1*}; Mehrzad Mehdizadeh, MD²; Zohreh Habibi, MD³; Hosein Alimadadi, MD⁴; Nasir Fakhar, MD⁵; Sepehr Haghghi, MD²; Meisam Sharifzadeh, MD^{6*}

¹Pathology Department, Children Medical Center, Tehran University of Medical Sciences, Tehran, Iran. ²Radiology Department, Children Medical Center, Tehran University of Medical Sciences, Tehran, Iran. ³Neurosurgery Department, Children Medical Center, Tehran University of Medical Sciences, Tehran, Iran. ⁴Pediatrics Gastroenterology Department, Children Medical Center, Tehran University of Medical Sciences, Tehran, Iran. ⁵Department of General Surgery, Tehran University of Medical Sciences, Tehran, Iran. ⁶Children's Medical Center, Pediatrics Center of Excellence, Tehran University of Medical Sciences, Tehran, Iran.

*Corresponding Authors: Meysam Sharifzadeh, MD; Children's Medical Center, Tehran University of Medical Sciences, Tehran, Iran. Email: meysamsharifzadeh49@gmail.com

Moeinadin Safavi, MD; Children's Medical Center, Tehran University of Medical Sciences, Tehran, Iran. Email: moein.safavi@gmail.com, msafavi@sina.tums.ac.ir

Cite this article as: Safavi M, Mehdizadeh M, Habibi Z, Alimadadi H, Fakhar N, Haghghi S, et al. Photoclinic. Arch Iran Med. 2019;22(8):476-477.

■ Photoclinic Diagnosis

Cerebral Aspergillosis

The frequency of opportunistic fungal infection has increased as a consequence of immunosuppressive drug usage, acquired immunodeficiency syndrome, and malignancy. Different fungi like *Candida*, *Aspergillus*, *Mucorales*, *Zygomycetes*, and *Cryptococcus* have the potential to affect the brain.¹ The hematologic spread is the routine pathway of CNS fungal infections, however, direct extension from the bones and sinuses to brain may occur.² Clinical manifestations of brain aspergillosis are nonspecific including deteriorated mental status, hemiparesis and seizure with or without concomitant fever.³

Characteristic radiologic findings, especially in magnetic resonance imaging, include single or multiple lesions with hemorrhagic infarction.² Homogenous or ring-like contrast enhancement is usually identified. The hallmark of *Aspergillus* mass is low signal intensity which is often observed at the periphery of the lesion as the consequence of ferromagnetic elements like iron magnesium and manganese.^{4,5}

Authors' Contribution

MS involved in pathology interpretation, image preparation and drafting the manuscript. MM and SH involved in radiology interpretation, reviewing the manuscript and drafting. ZH, HA,

NF, and MSH involved in patient management and drafting the manuscript.

Conflict of Interest Disclosures

The authors have no conflicts of interest.

Ethical Statement

An informed consent was obtained from the parents of patient for photographs and publication of this photoclinic.

References

1. Azarpira N, Esfandiari M, Bagheri MH, Rakei S, Salari S. Cerebral aspergillosis presenting as a mass lesion. *Braz J Infect Dis*. 2008;12(4):349-51.
2. Tempkin AD, Sobonya RE, Seeger JF, Oh ES. Cerebral aspergillosis: radiologic and pathologic findings. *Radiographics*. 2006;26(4):1239-42. doi: 10.1148/rg.264055152.
3. Almutairi BM, Nguyen TB, Jansen GH, Asseri AH. Invasive aspergillosis of the brain: radiologic-pathologic correlation. *Radiographics*. 2009;29(2):375-9. doi: 10.1148/rg.292075143.
4. Siddiqui AA, Shah AA, Bashir SH. Craniocerebral aspergillosis of sinonasal origin in immunocompetent patients: clinical spectrum and outcome in 25 cases. *Neurosurgery*. 2004;55(3):602-11. doi: 10.1227/01.neu.0000134597.94269.48
5. Marzolf G, Sabou M, Lannes B, Cotton F, Meyronet D, Galanaud D, Cottier JP, Grand S, Desal H, Kreutz J, Schenck M. Magnetic resonance imaging of cerebral aspergillosis: imaging and pathological correlations. *PLoS One*. 2016;11(4):e0152475. doi: 10.1371/journal.pone.0152475.

