

Case Report

A Patient with Trisomy 4p and Monosomy 10q

Maryam Sobhani, PhD¹; Parisa Tahmasebi, PhD²; Fatemeh Nasiri, MSc¹; Mitra Rahnama, BS¹; Roxana Karimi-Nejad, PhD³; Mohammad Amin Tabatabaiefar, PhD^{4,5*}

¹Iranian Blood Transfusion Research Center, High Institute for Research and Education in Transfusion Medicine, Tehran, Iran

²Department of Biology, Faculty of Sciences, Ilam University, Ilam, Iran

³Kariminejad & Najmabadi Pathology and Genetics Center, Tehran, Iran

⁴Department of Genetics and Molecular Biology, School of Medicine, Isfahan University of Medical Sciences, Isfahan, Iran

⁵Pediatric Inherited Diseases Research Center, Research Institute for Primordial Prevention of Noncommunicable Disease, Isfahan University of Medical Sciences, Isfahan, Iran

Abstract

Translocations are the most common structural abnormality in the human genome. Carriers of balanced chromosome rearrangements exhibit increased risk of abortion or a chromosomally-unbalanced child. The present study was carried out in 2017 at the Iranian Blood Transfusion Research Center. This study reported a rare chromosomal disorder with 4p duplication and 10q distal deletion syndrome which is associated with various complications at birth. Defects included the following characteristics: dysmorphic facial characteristic, hand or foot anomalies, growth retardation, developmental delay, strabismus, heart defects and renal anomalies. Cytogenetic analysis and array CGH were performed and, for the first time, we reported a patient with trisomy 4p16.3p12 and monosomy 10q26.3. The patient was found to have: arr 4p16.3p12 (37,152–45,490,207) x3, 10q26.3 (134,872,562–135,434,149) x1 genomic imbalances.

Keywords: Array CGH, Dysmorphic features, Intellectual disability, Monosomy 10q26.3, Trisomy 4p16.3, Unbalanced chromosome translocations

Cite this article as: Sobhani M, Tahmasebi P, Nasiri F, Rahnama M, Karimi-Nejad R, Tabatabaiefar MA. A patient with trisomy 4p and monosomy 10q. Arch Iran Med. 2019;22(7):414–417.

Received: August 31, 2018, Accepted: May 12, 2019, ePublished: July 1, 2019

Introduction

Carriers of balanced translocations are at risk of producing unbalanced gametes in their offspring during gametogenesis. Due to the meiotic segregation of chromosomes in meiosis during gametogenesis, there is a possibility of transmitting a combination of the two rearranged chromosomes resulting in genetic material imbalance. 4p duplication and distal 10q deletion syndromes which are uncommon chromosomal disorders are associated with numerous defects at birth. 4p duplication syndrome is also referred to as trisomy 4p. Typical facial manifestations include: small head, prominent glabella, abnormal ears, pointed chin, short neck and dental irregularities.^{1,2} Strabismus is prevalent in children suffering from 4p duplication syndrome, but most of them have normal vision. Furthermore, clinical signs include growth retardation, psychomotor retardation, unusual shape of hands and feet with clenched carvel fingers, and heart and renal anomalies.^{2,3}

Also, frequent infections of the respiratory tract which lead to chronic inflammatory lung disease are common. Bronchitis, asthma and recurrent inflammation of the larynx cause frequent closure of airways.¹

However, patients with distal 10q deletion syndrome (monosomy10q) exhibit phenotypic manifestations

such as facial dysmorphisms, developmental delay, postnatal growth retardation, psychomotor delay, learning disabilities, mental retardation, digital anomalies such as syndactyly, cardiac defects, and genitourinary defects.⁴

Here, we report a patient with trisomy 4p16.3p12 and monosomy10q26.3. To the best of our knowledge, this karyotype has not been previously reported. The gain (up to 141 genes) and loss (16 genes) of these genetic materials is compatible with 4p duplication syndrome and distal 10q deletion syndrome.

Case Report

The patient, a 6-year-old girl, is the second child of healthy, non-consanguineous parents from Iran's Sistan and Baluchestan province. She was born after a normal pregnancy. At birth, her head circumference was 31 cm with 38 cm length. Her body weight at birth was 2300 kg. Congenital heart disease was shown as a ventricular septal defect. She showed facial dysmorphic features such as: small chin, strabismus, enlarged ears, and damaged teeth. She had shown developmental delay and began walking alone at 24 months of age. She had curved fingers (clinodactyly) connected together (Figure 1). Also, she had unilateral cataract, severe respiratory allergy and gastric reflux. Magnetic resonance imaging (MRI) of the

*Corresponding Author: Mohammad Amin Tabatabaiefar, PhD; Department of Genetics and Molecular Biology, School of Medicine, Isfahan University of Medical Sciences, Isfahan 81746-73461, Iran and Pediatric Inherited Diseases Research Center, Research Institute for Primordial Prevention of Noncommunicable Disease, Isfahan University of Medical Sciences, Isfahan, Iran. Tel/Fax: 098- 0-31 3792 9144; Email: tabatabaiefar@med.mui.ac.ir

brain was normal. However, psychologists diagnosed her obsession, anxiety and masochism. Chromosomes for G-banding analysis were obtained from peripheral white blood cells of the patient and her parents using standard procedure. Informed consent was obtained from the family. The procedures were in accord with Isfahan University of Medical Sciences ethics committee.

The whole genome oligo Array CGH (Agilent, Santa Clara, CA) was performed using CYTOCHIP ISCA 8X60K version2 (Kariminejad-Najmabadi Pathology and Genetics Center, Iran) and analyzed using Blue Fuse Multi software per manufacturer's protocol. Cytogenetic analysis of the patient revealed 46, XX, der(10)t(4;10)(p12;q26.3) (Figure 2A). G-banding analysis of the mother showed 46 chromosomes with a balanced translocation between the short arm of chromosome 4 and the long arm of chromosome 10. Moreover, her karyotype was 46, XX,t(4;10)(p12;q26.3) (Figure 2B). The father's karyotype was normal. The array CGH results showed that the patient had the following genomic imbalances: (GRCh37) arr4p16.3p12 (37,152-45,490,207) x3, 10q26.3 (134,872,562-135,434,149) x 1. A 4.5 Mb genomic gain at 4p16.3p12 (Figure 2C) and 561.6 Kb terminal deletion at 10q26.3 compatible with trisomy 4p16.3p12 and 561.6 Kb loss of 10q26.3 compatible with monosomy of 10q26.3 were detected.

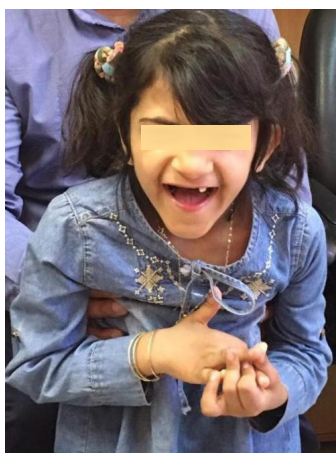

Figure 1. The Facial Features and Curved Fingers of the Patient.

Discussion

This is the first time that the case of a patient with trisomy 4p16.3p12 and monosomy10q26.3 syndrome is reported. 4p trisomy is a disorder which was explained by Gonzalez et al.¹ Imbalance on the short arm of chromosome 4 leads to a variety of distinct clinical symptoms such as: mental retardation, microcephaly, prenatal and postnatal growth retardation and low-set ears which are considered as a non-specific symptoms and related to gene dosage impairment. However, other distinct phenotypic features are associated with segmental aneuploidy.² Multiple anomalies include: special face appearance, unusual hands and feet, hypertonia or hypotonia, scoliosis, gastrointestinal abnormalities, frequent respiratory problems, seizures, congenital heart defects and renal anomalies.^{1,5} This chromosomal anomaly is caused by parental balanced translocation or de novo duplication through a complicated mechanism; but it is frequently caused by parental balanced translocation.^{3,5} In the case of our patient, the mother has normal phenotype and carries balanced translocation. This syndrome is only identified by cytogenetic analysis. Various studies show that patients who are trisomic for the distal two-thirds of the short arm of the chromosome 4, exhibit an overlapping phenotypic expression.^{2,3}

In this study, the duplication in 4p16.3p12 was observed in the patient overlapping with 141 OMIM genes. It is difficult to confirm that one specific gene is responsible for the specific phenotype, but some genes in this region were more likely to exhibit dosage sensitivity such as: fibroblast growth factor receptor 3 (*FGFR3*) [MIM* 134934] and msh homeobox 1 (*MSX1*) [MIM* 142983]. Regarding the growth alterations, the *FGFR3* gene, which physiological negative regulator of bone growth and a cause of at least 14 human disorders, may be a candidate gene for the anomalous growth in patients with 4p duplication. Also, mutations in the *MSX1* gene are associated with ectodermal dysplasia 3, orofacial cleft 5 and tooth agenesis. Therefore, *MSX1* may be one of the candidate genes for facial dysmorphism in patients with 4p duplication.²

Location and size of the deletion at the end of 10q is variable. However, the patients share characteristics such




Figure 2. (A) Patient karyotype with 46, XX, der(10)t(4;10)(p12;q26.3) and (B) her mother's karyotype with 46, XX, t(4;10)(p12;q26.3). (C) Expanded chromosome 4 of array CGH showing a duplicated segment of 4p12.15.1→4p16.3.

as special facial appearance, variable congenital defects and neurobehavioral manifesting.⁶⁻⁸ Despite the clinical heterogeneity in 10q deletion syndrome [MIM# 609625], some of the characteristics are broad nasal bridge, prominent nose, hypertelorism, asymmetric face, growth retardation, learning disabilities, digital anomalies and psychiatric problems.^{6,9,10} The clinical manifestations and size of the 10q26 deletions of patients from the previous studies and the present one are summarized in Table 1. Our patient has distal deletion in 10q26.3 resulting the loss of 16 genes (DECIPHER; <https://decipher.sanger.ac.uk>) among which 12 genes are listed in OMIM (<http://www.omim.org/>). OMIM genes contain: *GPR12* (MIM: *612302), *UTF1* (MIM: *604130), *VENTX* (MIM: *607158), *ADAM8* (MIM: *602267), *DRD1IP* (MIM: *604647), *PRAP1* (MIM: *609776), *ECHS1* (MIM: *602292), *SPRN* (MIM: *610447), *CYP2E1* (MIM: *124040), *SYCE1* (MIM: *611486), *KNDC1* (MIM: *616237), *PAOX* (MIM: *61585). Basically, terminal deletions are more common at the 10q25 or 10q26 breakpoints.^{4,9} It is noteworthy that no clear association between the size and location of deletion and severity of phenotypes has been observed. Most of the symptoms observed in our patient are shared by both of the mentioned syndromes. Yet, behavioral problems which are mostly significant include anxiety, obsession and masochism. Involvement of long arm of chromosome 10 in psychiatric disorders has been observed in several genome wide association studies.¹¹

These disorders which include inattention, hyperactivity, and impulsivity are categorized under attention-deficit hyperactivity disorder (ADHD) [MIM #143465].¹² The behavioral phenotype, observed in our patient and

10q 26 deletion patients in other studies, indicate the role of candidate genes which control neurobehavioral functions.¹² The best candidate is Dopamine Receptor D1 Interacting Protein (*DRD1IP*) gene, also known as *CALY* gene [MIM*604647], which encodes the expressed single transmembrane protein in the brain. Recently, it has been shown that the expression level of *CALY* gene is associated with neurobehavioral abnormalities in various animal models.¹² Therefore, it seems that haploinsufficiency in *CALY* gene can be partially responsible for behavioral phenotypes seen in 10q deletion syndrome.⁶

Initially, Chang et al reported a patient with 10q deletion syndrome with cataract.⁴ Our case is the second one. In most cases, cataract has unknown etiology. However, it may be genetic or due to systematic abnormalities or metabolic diseases. Our patient had no history of injury, metabolic diseases, or ocular inflammation. A recent study shows that some systematic disorders including inherited diseases associated with cataract include an abnormal gene locus at 10q.^{4,13} Our case report also supports the viewpoint that a defect in the genes on 10q can play a role in causing psychiatric disorders and cataract.

Authors' Contribution

MAT planned the study, supervised the procedures and interpreted the experimental results, MS and PT performed the genetic counseling of the family, contributed in the analysis of the results, and prepared the draft, FN and MR carried out the karyotyping, RK performed and analyzed array CGH. All the authors helped in the revisions, and approval of the final draft.

Conflict of Interest Disclosures

The authors declare no conflicts of interest.

Table 1. Clinical Features in Patients with 10q26 Deletions in the Present Study and Previous Studies

| Feature | Yatsenko et al (2009) ¹⁰ | Chang et al (2013) ⁴ | Choucair et al (2015) ⁸ | Plaisancié et al (2014) ⁶ | Lin et al (2016) ⁷ | Present Study |
|-------------------------------|-------------------------------------|---------------------------------|------------------------------------|--------------------------------------|-------------------------------|---------------|
| Total number of patients | 5 | 1 | 1 | 4 | 2 | 1 |
| Deletion size (Mb) | 3.51-17.22 | * | 4.5 | 4.96-7.09 | 13.04-14.04 | 0.5616 |
| Gender | 3 M, 2 F | 1 F | 1 M | 4 F | 2 F | F |
| Prominent/broad nasal bridge | 5/5 | 1/1 | 1/1 | 4/4 | 2/2 | |
| Developmental delay | 4/5 | 1/1 | 1/1 | 4/4 | 2/2 | + |
| Strabismus | 2/5 | | 1/1 | | 2/2 | + |
| Clinodactyly | 2/5 | 1/1 | | 3/4 | | + |
| Ear anomalies | 4/5 | 1/1 | 1/1 | 4/4 | 2/2 | + |
| cataract | | 1/1 | | | | + |
| Hearing loss | 1/5 | 1/1 | | | | |
| Microcephaly | 4/5 | | 1/1 | 3/4 | | |
| Congenital heart defect | 3/5 | 1/1 | | | 2/2 | + |
| Genital anomalies | 1/5 | | 1/1 | | | |
| Behavioral problems | 3/5 | | | 4/4 | 2/2 | + |
| Urinary tract/renal anomalies | 2/5 | 1/1 | | | | |

* This study was used FISH method. Patient had a 10q interstitial deletion, del(10)(q26.1q26.3).

+ Means observed these Features in our Patient

Ethical Statement

All procedures in this study were approved by Isfahan University of Medical Sciences ethics committee. Informed consent was obtained from the family.

Acknowledgement

This work was partially supported by a grant (grant no. 195122) from Isfahan University of Medical Sciences.

References

- Gonzalez CH, Sommer A, Meisner LF, Elejalde BR, Opitz JM, Francke U. The trisomy 4p syndrome: case report and review. *Am J Med Genet.* 1977;1(2):137-156. doi: 10.1002/ajmg.1320010202.
- Wu D, Zhang H, Hou Q, Wang H, Wang T, Liao S. Genotype/phenotype analysis in a male patient with partial trisomy 4p and monosomy 20q due to maternal reciprocal translocation (4; 20): A case report. *Mol Med Rep.* 2017;16(5):6222-7. doi: 10.3892/mmr.2017.7390.
- Carmany EP, Bawle EV. Microduplication of 4p16. 3 due to an unbalanced translocation resulting in a mild phenotype. *Am J Med Genet A.* 2011;155(4):819-24. doi: 10.1002/ajmg.a.33916.
- Chang Y-T, Chou I-C, Wang C-H, Chin Z-N, Kuo H-T, Lin C-C, et al. Chromosome 10q deletion del (10)(q26. 1q26. 3) is associated with cataract. *Pediatr Neonatol.* 2013;54(2):132-6. doi: 10.1016/j.pedneo.2012.10.010.
- Puvabanditsin S, Herrera-Garcia G, Gengel N, Hussein K, February M, Mayne J, et al. Partial trisomy 4p and partial monosomy 13q: case report and a literature review. *J Genet Couns.* 2016;27(1):35.
- Plaisancie J, Bouneau L, Cances C, Garnier C, Benesteau J, Leonard S, et al. Distal 10q monosomy: new evidence for a neurobehavioral condition? *Eur J Med Genet.* 2014;57(1):47-53. doi: 10.1016/j.ejmg.2013.11.002.
- Lin S, Zhou Y, Fang Q, Wu J, Zhang Z, Ji Y, et al. Chromosome 10q26 deletion syndrome: Two new cases and a review of the literature. *Mol Med Rep.* 2016;14(6):5134-40. doi: 10.3892/mmr.2016.5864.
- Choucair N, Abou Ghoch J, Fawaz A, Mégarbané A, Chouery E. 10q26. 1 Microdeletion: Redefining the critical regions for microcephaly and genital anomalies. *Am J Med Genet A.* 2015;167(11):2707-13. doi: 10.1002/ajmg.a.37211.
- Irving M, Hanson H, Turnpenny P, Brewer C, Ogilvie CM, Davies A, et al. Deletion of the distal long arm of chromosome 10; is there a characteristic phenotype? A report of 15 de novo and familial cases. *Am J Med Genet A.* 2003;123(2):153-63. doi: 10.1002/ajmg.a.20220.
- Yatsenko S, Kruer M, Bader P, Corzo D, Schuette J, Keegan C, et al. Identification of critical regions for clinical features of distal 10q deletion syndrome. *Clin Genet.* 2009;76(1):54-62. doi: 10.1111/j.1399-0004.2008.01115.x.
- Consortium C-DGotPG. Identification of risk loci with shared effects on five major psychiatric disorders: a genome-wide analysis. *The Lancet.* 2013;381(9875):1371-9. doi: 10.1016/S0140-6736(12)62129-1.
- Loos M, Pattij T, Janssen MC, Counotte DS, Schoffelmeer AN, Smit AB, et al. Dopamine receptor D1/D5 gene expression in the medial prefrontal cortex predicts impulsive choice in rats. *Cereb Cortex.* 2010;20(5):1064-70. doi: 10.1093/cercor/bhp167.
- Trumler AA. Evaluation of pediatric cataracts and systemic disorders. *Curr Opin Ophthalmol.* 2011;22(5):365-79. doi: 10.1097/ICU.0b013e32834994dc.