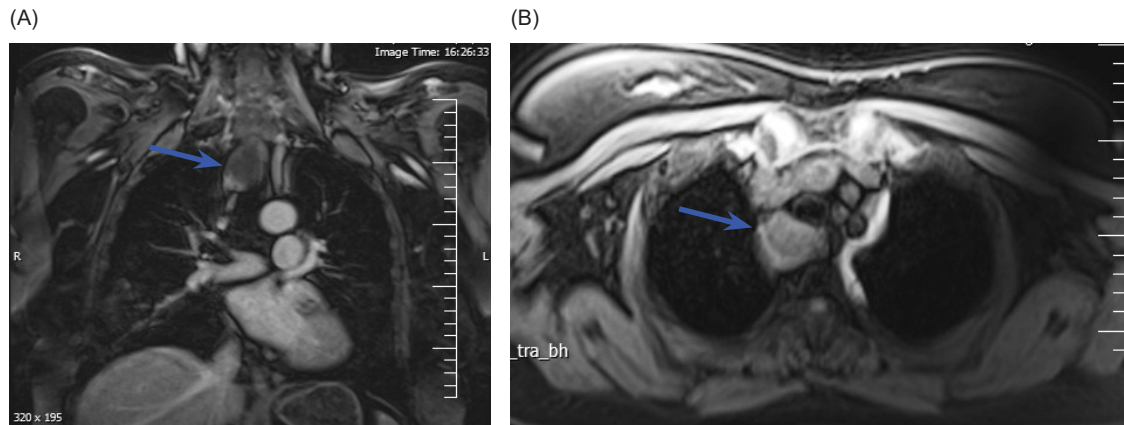


**Photoclinic**

**Figure 1.** (A, B) MRI Revealing Well-Defined Solid-Cystic Lesion in Superior Posterior Mediastinum, Posterior to Trachea About 33 × 24 mm.

A 67-year-old woman was referred to the emergency department with nausea, vomiting, polydipsia, and polyuria. She had a history of type 2 diabetes and hypertension with chronic kidney disease and parathyroidectomy due to parathyroid adenoma 9 years ago. On admission, vital signs were stable (BP: 130/80 mm Hg, PR: 70 beats/min, RR: 13/min). Neck examination revealed that the thyroid gland was normal size without nodules and neck Lymphadenopathy was not found. Laboratory tests revealed: anemia (Hb: 11 g/dL; normal range, 13.5–17.5 g/dL); hypercalcemia (Ca: 13 mg/dL; normal range, 8.4–10.2 mg/dL); elevated serum level of intact parathyroid hormone (PTH) (291 Pg/mL; normal range, 10–65 pg/mL); phosphate (2.5 mg/mL; normal range, 2.2–4.4); blood urea nitrogen (BUN) (40 mg/mL; normal range, 7–18 mg/dL); thyroid-stimulating hormone (TSH) (3.7  $\mu$ u/mL; normal range, 0.5–5  $\mu$ u/mL); T<sub>4</sub> (7  $\mu$ g/dL; normal range,

5–12  $\mu$ g/d); 25(OH) VitD (180 nmol/mL; normal range, 75–200 nmol/dL). Technetium Tc 99m sestamibi scan showed persistent radiotracer uptake in the right middle of the mediastinum. On magnetic resonance imaging (MRI) solid-cystic lesion in the superior posterior mediastinum, posterior to trachea was about 33 × 24 mm (Figure 1). After fluid resuscitation, loop diuretic, and calcitonin treatment, open thoracotomy was performed. She is asymptomatic and has normal serum calcium and PTH levels on regular follow-up.

Parathyroid adenoma is one of the most common causes of primary hyperparathyroidism.<sup>1</sup> The occurrence of parathyroid adenomas outside the parathyroid gland is usually explained by their embryonic development. Therefore, abnormal parathyroid gland can occur on any part of the pathway of parathyroid embryonic development.<sup>2</sup> Primary hyperparathyroidism is 3 times more common

**What is your diagnosis?  
See the next page for your diagnosis.**

Received: November 23, 2017, Accepted: October 7, 2018, ePublished: November 1, 2018

**Mahbube Ebrahimpur, MD<sup>1</sup>; Mohammad Reza Mohajeri-Tehrani, MD<sup>1</sup>; Mahnaz Pejman Sani, MD<sup>2\*</sup>**

<sup>1</sup>Endocrinology and Metabolism Research Center of Tehran University of Medical Sciences, Tehran, Iran

<sup>2</sup>Department of Internal Medicine, Shariati Hospital, Tehran University of Medical Sciences, Tehran, Iran

\*Corresponding Author: Mahnaz Pejman Sani, Department of Internal Medicine, Shariati Hospital, Tehran University of Medical Sciences, Tehran, Iran. Tel: +98 21 88220037, Fax: +98 21 88220052; Email: mpsani@sina.tums.ac.ir

**Cite this article as:** Ebrahimpur M, Mohajeri-Tehrani MR, Pejman Sani M. Photoclinic. Arch Iran Med. 2018;21(11):547-548.

## ■ Photoclinic Diagnosis

### Huge Ectopic Parathyroid Adenoma

in women and occurs at an average age of 60 years.<sup>3</sup> The incidence and prevalence of primary hyperparathyroidism are about 1/1000 and 3/1000 in the normal population respectively.<sup>3</sup> Primary hyperparathyroidism is due to single adenoma (85–85%), hyperplasia (10%–20%), carcinoma (1%), and up to 20% of the parathyroid glands may be outside of the anatomical location.<sup>4</sup> The most common site of an ectopic parathyroid gland is in the mediastinum.<sup>2</sup> Clinical manifestations in patients with primary hyperparathyroidism, such as bone pain, depression, anxiety, fatigue, polyuria, polydipsia, muscle cramp, and constipation, depends on serum calcium levels. Benign tumors are not detectable on routine physical examination and are diagnosed based on laboratory findings and imaging.<sup>4</sup> After neck exploration, ectopic tumors and several other reasons such as disease recurrence or surgical site residue can be responsible for persistent hyperparathyroidisms. Due to these challenges, anatomical studies are recommended before surgery. In managing parathyroid adenoma recurrence after a previous surgery, careful examination of previous imaging, operational and pathology notes, ultrasound and Tc-99m sestamibi scan are required.

If the location of the tumor remains uncertain, cross-sectional imaging (eg, CT or MRI) should be conducted.<sup>2</sup> Sensitivity of ultrasonography and Tc-99m sestamibi scan in discovery of adenoma is 60–90% and 70%–80%, respectively. The test with the highest sensitivity of about 87% for localization of parathyroid tumors is a 99m sestamibi scan with single-photon emission computerized tomography (SPECT).<sup>5</sup>

#### Authors' Contribution

Data collection: ME; Writing primary draft and manuscript: MRMT; all authors' revised subsequent drafts of the paper; final revision and prepared this manuscript for publication: MPS.

#### Conflict of Interest Disclosures

The authors have no conflicts of interest.

#### Ethical Statement

An informed consent was obtained from the patient for publishing this photo clinic.

#### Funding

None.

#### References

1. Chang BA, Sharma A, Anderson DW. Ectopic parathyroid adenoma in the soft palate: a case report. *J Otolaryngol Head Neck Surg.* 2016;45(1):53. doi: 10.1186/s40463-016-0165-z.
2. Sato S, Kitahara A, Koike T, Hashimoto T, Ohashi R, Motoi N, et al. Resection of a large ectopic parathyroid adenoma: A case report. *Int J Surg Case Rep.* 2016;23:8-11. doi: 10.1016/j.ijscr.2016.04.007.
3. Grozavu C, Pantile D. Primary Hyperparathyroidism Through an Ectopic Parathyroid Adenoma. *Chirurgia (Bucur).* 2016;111(2):156-60.
4. Taghavi Kojidi H, Vagharimehr N, Mohseni S, Pajouhi M, Mohajeri-Tehrani MR. Unusual Ectopic Parathyroid Adenoma: A Case Report. *Acta Med Iran.* 2016;54(8):547-50.
5. Al-Mashat F, Sibiany A, Faleh D, Kary K, Alfi AY, El-Lakany MM. Mediastinal parathyroid adenoma. *Saudi J Kidney Dis Transpl.* 2009;20(5):826-30.



© 2018 The Author(s). This is an open-access article distributed under the terms of the Creative Commons Attribution License (<http://creativecommons.org/licenses/by/4.0>), which permits unrestricted use, distribution, and reproduction in any medium, provided the original work is properly cited.