

## Original Article

# Eicosapentaenoic Acid and Vitamin E Against Doxorubicin-Induced Cardiac and Renal Damages: Role of Cytochrome c and iNOS

Ahmed M. Fayez, PhD<sup>1</sup>; Mai A. Zaafan, PhD<sup>1\*</sup><sup>1</sup>Pharmacology and Toxicology Department, Faculty of Pharmacy, October University for Modern Sciences and Arts, Egypt**Abstract**

**Background:** The current study aimed to evaluate the mechanisms involved in protection against doxorubicin-induced cardiac and renal toxicities upon treatment with eicosapentaenoic acid and vitamin E.

**Methods:** Rats were randomly assigned to 4 groups: normal control, doxorubicin induced control, eicosapentaenoic acid treated group and a final group pretreated with vitamin E. Lipid peroxidation, reduced glutathione (GSH) and tumor necrosis factor- $\alpha$  (TNF- $\alpha$ ) contents as well as glutathione peroxidase (GPx), superoxide dismutase (SOD) and myeloperoxidase (MPO) activities were assessed. Moreover, hearts were used for immunohistochemical detection of the pro-apoptotic protein cytochrome c expression, while the kidneys were used for detection of inducible nitric oxide synthase (iNOS) expression.

**Results:** Eicosapentaenoic acid and vitamin E produced significant protection from doxorubicin-induced cardiac and renal toxicities. The suggested mechanisms for protection included decreased cytochrome c and iNOS expression as well as markedly decreased lipid peroxides and TNF- $\alpha$  contents accompanied with increased GSH content as compared to the doxorubicin control group. Moreover, there was marked increase in GPx and SOD activities accompanied by significant suppression of MPO activity.

**Conclusion:** The present study demonstrated the potent protective effects of eicosapentaenoic acid and vitamin E from doxorubicin induced cardiac and renal toxicities through their potent anti-oxidant, anti-inflammatory and anti-apoptotic properties. Hence, eicosapentaenoic acid and vitamin E could be promising protective agents against doxorubicin toxicity.

**Keywords:** Anti-inflammatory, Cytochrome c, Doxorubicin, Eicosapentaenoic acid, iNOS, Vitamin E

**Cite this article as:** Fayez AM, Zaafan MA. Eicosapentaenoic acid and vitamin E against doxorubicin-induced cardiac and renal damages: role of cytochrome c and iNOS. Arch Iran Med. 2018;21(11):502-508.

Received: January 1, 2018, Accepted: October 7, 2018, ePublished: November 1, 2018

**Introduction**

Use of doxorubicin as an effective broad spectrum anthracycline chemotherapeutic drug has been hindered by its dose-dependent cardiac and renal toxicities.<sup>1</sup> The mechanisms underlying doxorubicin-induced cardiomyopathy and nephrotoxicity are not completely understood but may include increased oxidative stress and free radical formation.<sup>2,3</sup> Doxorubicin induces disruption of the catalytic cycle of topoisomerase 2 $\beta$  resulting in DNA double strand breaks and contributing to the generation of reactive oxygen species (ROS) and to mitochondrial dysfunction and apoptosis.<sup>4</sup> Despite the remarkable and extensive research about doxorubicin, the clinical usefulness of doxorubicin is restricted by specific toxicities to cardiac and renal tissues.

Omega-3 polyunsaturated fatty acids exhibit many beneficial effects against cardiovascular diseases. Eicosapentaenoic acid is the major omega-3 polyunsaturated fatty acid in fish oil that has various pharmacological effects.<sup>5</sup> Intake of eicosapentaenoic acid can attenuate pathological cardiac remodeling in response to pressure overload and can affect cardiac mitochondrial function through alteration of membrane phospholipids.<sup>4</sup> In addition, eicosapentaenoic acid promotes the production of adiponectin, which protects

against diabetes and atherosclerosis.<sup>6</sup> Another study has demonstrated that omega-3 poly-unsaturated fatty acids can both enhance the toxicity of drugs to tumor cells at low doses, offer protection to the non-target tissue, and, therefore, they can augment the therapeutic index of anticancer drugs and reduce the possible side effects of various chemotherapeutic treatments.<sup>7</sup>

Vitamin E is the collective name for a group of fat-soluble compounds that is found naturally in some foods and available as a dietary supplement. The main function of vitamin E in the body is to act as an antioxidant and get rid of free radicals that can damage cells.<sup>8</sup> In addition, it was suggested to have anti-inflammatory potential through inhibition of pro-inflammatory cytokines expression.<sup>9</sup>

Hence, the current study aimed to evaluate the efficacy of eicosapentaenoic acid and vitamin E against doxorubicin-induced cardiac and renal toxicities in addition to studying their possible mechanisms of action.

**Materials and Methods****Animals**

Male Wistar albino rats, weighing 150–200 g, were used in the present study. They were purchased from the Egyptian

\*Corresponding Author: Mai A. Zaafan, MD; Pharmacology and Toxicology Department, Faculty of Pharmacy, October University for Modern Sciences and Arts, Egypt. Tel: 00202-01065751000, Email: makamel@msa.eun.eg

Company for Production of Vaccines, Sera and Drugs (EGYVAC; Cairo, Egypt) and allowed free access to water and standard pellet chow. Rats were kept under constant conditions (temperature  $25 \pm 3^\circ\text{C}$  and humidity 50%) with 12/12 h light/dark cycles. The study was carried out according to the guidelines of the Ethics Committee, Faculty of Pharmacy, October University for Modern Sciences and Arts.

### Drugs and Chemicals

Eicosapentaenoic acid and vitamin E were purchased from Sigma-Aldrich (MO, USA); whereas doxorubicin Hydrochloride was obtained from Pfizer (Cairo, Egypt). All other chemicals used were of analytical grade.

### Experimental Design

Rats were randomly allocated into 4 groups ( $n = 8$ ) using a simple randomization technique. The first 2 groups served as normal and doxorubicin control groups, respectively. The remaining 2 groups received eicosapentaenoic acid (300 mg/kg/d; p.o) and vitamin E (200 mg/kg/d; p.o.), respectively, for 14 days. All groups, except the normal one, received a single high dose of doxorubicin HCl (15 mg/kg; i.p.) in the last day of treatment.<sup>1</sup>

After 24 hours from the last treatment, the animals were anesthetized with ether. Blood samples were collected from the retro-orbital plexus for serum separation and estimation of creatine kinase-MB (CK-MB) activity. Then, rats were sacrificed by cervical dislocation and their hearts and kidneys were rapidly isolated and washed with ice-cold saline. The hearts were cut into 2 equal halves. One half was homogenized in phosphate buffer to prepare 10% (w/v) homogenate that was used for the estimation of cardiac lipid peroxides, reduced glutathione (GSH), glutathione peroxidase (GPx) and tumor necrosis factor- $\alpha$  (TNF- $\alpha$ ) contents. While, the other half was preserved in 10% formalin for histologic examination and the immunohistochemical detection of cytochrome c expression. Regarding isolated kidneys, one kidney from each rat was homogenized in phosphate buffer to prepare 10% (w/v) homogenate that was used for the estimation of renal lipid peroxides, GSH, TNF- $\alpha$  contents as well as superoxide dismutase (SOD) and myeloperoxidase (MPO) activities. Finally, the other kidney was preserved in 10% formalin for immunohistochemical detection of inducible nitric oxide synthase (iNOS) and histological examination.

### Biochemical Investigations

Activity of CK-MB in serum was determined using the Stanbio CK-MB diagnostic kit (USA). Lipid peroxidation in cardiac and renal tissues was estimated by the determination of thiobarbituric acid reactive substances content that was evaluated as malondialdehyde (MDA) in heart and kidney homogenates using a standard kit purchased from Biodiagnostic (Egypt). Cardiac and renal GSH contents were determined using a commercial kit (Biodiagnostic, Egypt).

Cardiac and renal contents of TNF- $\alpha$  were determined by

ELISA technique using standard kits (MyBioSource, Inc., USA). While the cardiac GPx was measured using specific an immunoassay kit (Elabscience, USA). Finally, SOD and MPO activities in renal tissue were estimated using a commercial kit (Biodiagnostic, Egypt).

### Immunohistochemical Expression of Cytochrome c and iNOS

Paraffin embedded tissue sections of 3  $\mu\text{m}$  thickness were rehydrated in xylene and then in graded ethanol solutions. The slides were then blocked with 5% bovine serum albumin (BSA) in Tris buffered saline (TBS) for 2 hours. The sections were then immunostained with primary antibody polyclonal immunoglobulin-G (IgG) to rat iNOS or rat cytochrome c at a concentration of 1  $\mu\text{g}/\text{mL}$  with 5% BSA in TBS and incubated overnight at  $4^\circ\text{C}$ . After washing the slides with TBS, the sections were incubated with secondary antibody, diluted 1:2000 with 5% BSA in TBS and incubated for 2 hours at room temperature. Finally, sections were washed with TBS and incubated for 5–10 min in a solution of 0.02% diaminobenzidine containing 0.01% hydrogen peroxide. Counter staining was performed using hematoxylin, and the slides were visualized under a light microscope.<sup>10</sup>

### Histopathologic Assessment of Heart and Kidney Tissue Damage

Autopsy samples were taken from the hearts and kidneys of rats in different groups and fixed in 10% formal saline for twenty-four hours. These tissues were prepared for histological preparation as prescribed by Bancroft, Stevens.<sup>11</sup> The severity of changes was quantitated from none (-) to severe (+++) based on the degree of necrosis, tissue degeneration and inflammatory cells infiltration. The scoring system was as follows: (-) no damage, (+) mild, (++) moderate, and (+++) severe negative features.

### Statistical Analysis

Data were expressed as mean  $\pm$  SD. Comparisons between means of different groups were carried out using one-way analysis of variance (ANOVA) followed by Tukey-Kramer multiple comparisons test.<sup>12</sup> The level of significance was taken as  $P < 0.05$ . GraphPad Prism software package, version 5 (GraphPad Software, Inc., USA) was used to carry out all statistical tests.

## Results

### Biochemical Investigations

Doxorubicin resulted in significant increase in the serum CK-MB activity as compared to the normal rats. The rats pretreated with eicosapentaenoic acid and vitamin E showed a significant suppression of CK-MB activity as compared to the doxorubicin control rats (Table 1).

The current study showed a significant increase in cardiac MDA content combined with marked decrease in GSH content and GPx activity in the heart tissue upon doxorubicin treatment. While, pretreatment with eicosapentaenoic acid and vitamin E resulted in a significant decrease in cardiac

**Table 1.** Effect of Eicosapentaenoic Acid and Vitamin E Treatment on Serum Creatine Kinase-MB (CK-MB) Activity as well as Cardiac Contents of TNF- $\alpha$ , MDA, reduced GSH and GPx

Parameter	Normal Control	Doxorubicin Control	Eicosapentaenoic Acid	Vitamin E
CK-MB (ng/mL)	1.50 $\pm$ 0.16	9.10 <sup>a</sup> $\pm$ 0.88	4.75 <sup>ab</sup> $\pm$ 0.56	3.05 <sup>ab</sup> $\pm$ 0.24
TNF- $\alpha$ (pg/g tissue)	7.35 $\pm$ 1.28	29.92 <sup>a</sup> $\pm$ 2.92	19.05 <sup>ab</sup> $\pm$ 2.60	13.00 <sup>ab</sup> $\pm$ 3.36
MDA ( $\mu$ mol/mL tissue)	11.58 $\pm$ 2.04	37.90 <sup>a</sup> $\pm$ 6.48	25.40 <sup>ab</sup> $\pm$ 5.20	18.60 <sup>ab</sup> $\pm$ 4.12
GSH (pg/g tissue)	24.60 $\pm$ 5.48	3.84 <sup>a</sup> $\pm$ 2.56	12.35 <sup>ab</sup> $\pm$ 3.28	17.53 <sup>ab</sup> $\pm$ 3.48
GPx (pg/g tissue)	13.15 $\pm$ 3.28	7.45 <sup>a</sup> $\pm$ 1.56	17.45 <sup>ab</sup> $\pm$ 3.72	18.51 <sup>ab</sup> $\pm$ 3.92

Abbreviations: TNF- $\alpha$  tumor necrosis factor-alpha; MDA, malondialdehyde; GSH, glutathione; GPx, glutathione peroxidase; CK-Mb, creatine kinase-MB.

Each value represents mean  $\pm$  SD (n = 6)

<sup>a</sup> Significantly different from normal control group at  $P < 0.05$

<sup>b</sup> Significantly different from doxorubicin control group at  $P < 0.05$

<sup>c</sup> Significantly different from eicosapentaenoic acid group at  $P < 0.05$

MDA content with a parallel marked increase in cardiac GSH content and GPx activity. In addition, eicosapentaenoic acid and vitamin E were effectively able to decrease the cardiac TNF- $\alpha$  content as compared to the doxorubicin control group (Table 1).

Moreover, doxorubicin produced significant increase in the oxidative stress and inflammatory biomarkers in kidney tissues as revealed by significant increase in renal MDA (mean difference: 91.75; 95% CI: 87.38 to 96.11) and TNF- $\alpha$  contents (mean difference: 16.94; 95% CI: 14.96 to 18.91) as well as MPO activity (mean difference: 16.11; 95% CI: 13.42 to 18.80). These were accompanied by significant decrease in renal GSH content (mean difference: 80.85; 95% CI: 67.91 to 93.79) and SOD activity (mean difference: 34.43; 95% CI: 30.74 to 38.12) (Table 2).

Eicosapentaenoic acid also resulted in significant suppression in the renal MDA (mean difference: 64.06; 95% CI: 59.69 to 68.42) and TNF- $\alpha$  contents (mean difference: 10.56; 95% CI: 8.582 to 12.54) when compared to the doxorubicin control group. The MPO activity was also decreased with eicosapentaenoic acid pretreatment (mean difference: 11.35; 95% CI: 8.661 to 14.04). Renal GSH content and SOD activity increased significantly in the eicosapentaenoic acid group when compared to the doxorubicin control (Table 2).

In addition, pretreatment with vitamin E produced marked suppression in renal MDA (mean difference: 78.86; 95% CI: 74.50 to 83.22) and TNF- $\alpha$  contents (mean difference: 11.54; 95% CI: 9.562 to 13.52) when compared to treatment with doxorubicin alone. Renal MPO activity

decreased markedly upon pretreatment with vitamin E as compared to the doxorubicin control group (mean difference: 12.32; 95% CI: 9.631 to 15.01). Moreover, renal GSH content and SOD activity obviously increased upon pretreatment with vitamin E as compared to the doxorubicin control rats (Table 2).

#### Expression of Cytochrome c in the Heart

Heart sections from normal control rats showed very weak positive expression of cytochrome c in heart tissue (Figure 1A). On the other hand, doxorubicin treated rats showed strong positive expression of cytochrome c in their heart tissue as shown in Figure 1B. The heart sections of eicosapentaenoic acid group revealed weak positive expression of cytochrome c as compared to that of doxorubicin control group (Figure 1C). Pretreatment with vitamin E showed moderate positive expression of cytochrome c in heart tissue (Figure 1D). Comparative quantification of cytochrome c staining from all groups is presented in Figure 1E.

#### Expression of iNOS in the Kidneys

Kidneys of normal control rats showed small degree of immunostaining for iNOS (Figure 2A). On the other hand, doxorubicin produced severe increase in the immunohistochemical expression of iNOS in the kidneys as shown in Figure 2B.

While, the kidneys of eicosapentaenoic acid pretreated rats showed moderate immunohistochemical expression of iNOS (Figure 2C). Finally, pretreatment with vitamin E produced mild immunohistochemical expression of iNOS

**Table 2.** Effect of Eicosapentaenoic Acid and Vitamin E Treatment on Renal Contents of Reduced GSH, MDA, SOD, TNF- $\alpha$  and MPO

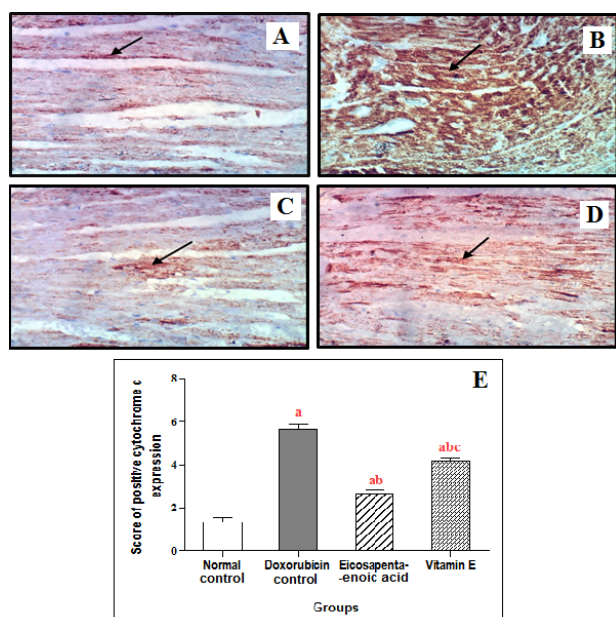
Parameter	Normal Control	Doxorubicin Control	Eicosapentaenoic Acid	Vitamin E
GSH (mg/g tissue)	152.10 $\pm$ 15.6	71.28 <sup>a</sup> $\pm$ 2.56	120.10 <sup>ab</sup> $\pm$ 2.21	128.00 <sup>ab</sup> $\pm$ 1.29
MDA (nmol/g tissue)	52.53 $\pm$ 3.07	144.30 <sup>a</sup> $\pm$ 3.19	80.22 <sup>ab</sup> $\pm$ 2.35	65.41 <sup>abc</sup> $\pm$ 1.89
SOD (U/mg tissue)	45.43 $\pm$ 2.94	11.00 <sup>a</sup> $\pm$ 1.45	29.47 <sup>ab</sup> $\pm$ 2.13	38.11 <sup>abc</sup> $\pm$ 2.33
TNF- $\alpha$ (pg/mg tissue)	11.32 $\pm$ 1.26	28.26 <sup>a</sup> $\pm$ 1.18	17.70 <sup>ab</sup> $\pm$ 1.67	16.72 <sup>ab</sup> $\pm$ 1.29
MPO (U/mg tissue)	21.94 $\pm$ 1.87	38.05 <sup>a</sup> $\pm$ 2.08	26.70 <sup>ab</sup> $\pm$ 1.66	25.73 <sup>ab</sup> $\pm$ 0.68

Abbreviations: TNF- $\alpha$  tumor necrosis factor-alpha; MDA, malondialdehyde; GSH, glutathione; SOD, superoxide dismutase; MPO, myeloperoxidase. Each value represents mean  $\pm$  SD (n = 6)

<sup>a</sup> Significantly different from normal control group at  $P < 0.05$

<sup>b</sup> Significantly different from doxorubicin control group at  $P < 0.05$

<sup>c</sup> Significantly different from eicosapentaenoic acid group at  $P < 0.05$



**Figure 1.** Effect of Eicosapentaenoic Acid and Vitamin E Treatment on the Immunohistochemical Expression Of Cytochrome c in Heart Tissue ( $\times 16$ ): (A) The normal control group: small degree of immunostaining of cytochrome c as illustrated by the brown color, (B) The doxorubicin control group: severe increased expression of cytochrome c, (C) Eicosapentaenoic acid treated group: weak positive expression of cytochrome c, (D) Vitamin E treated group: moderate positive expression of cytochrome c, (E) Quantification of cytochrome c staining represents the number of stained (positive) cells per ( $\times 16$ ) field was averaged across 6 fields for each rat section. Each value represents mean  $\pm$  SD ( $n = 6$ ) <sup>a</sup> significantly different from normal control group at  $P < 0.05$ , <sup>b</sup> significantly different from doxorubicin control group at  $P < 0.05$ , <sup>c</sup> significantly different from eicosapentaenoic acid group at  $P < 0.05$ .

in the kidneys (Figure 2D). Comparative quantification of iNOS staining from all groups is presented in Figure 2E.

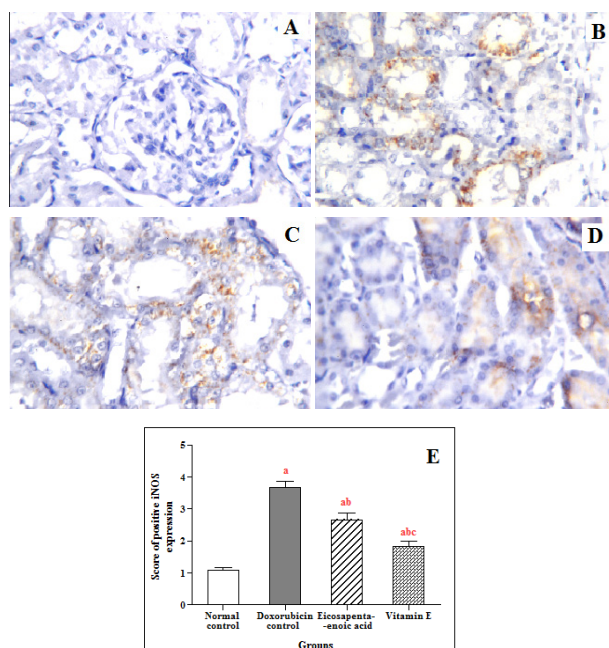
#### Histological Examination of the Heart and Kidneys

Hearts from the doxorubicin control rats showed multiple focal areas of myocardial cell degeneration with edema and inflammatory cell infiltration combined with congestion in the myocardial blood vessels. On the other hand, marked improvement was noticed in rats pretreated with either eicosapentaenoic acid or vitamin E (Figure 3).

In addition, the histological examination of the kidneys reflected that doxorubicin caused marked swelling of the tubular lining epithelium at the cortex of the kidney tissue. This was associated with congestion in the intertubular blood vessels and the glomerular tufts. The corticomedullary portion showed severe congestion in the blood vessels associated with focal hemorrhage in between the degenerated tubules. On the other hand, pretreatment with either eicosapentaenoic acid or vitamin E showed almost normal histological structure of the kidneys (Figure 4). Severity of histopathological alterations in the hearts and kidneys of the different experimental groups are illustrated in Table 3 and Table 4.

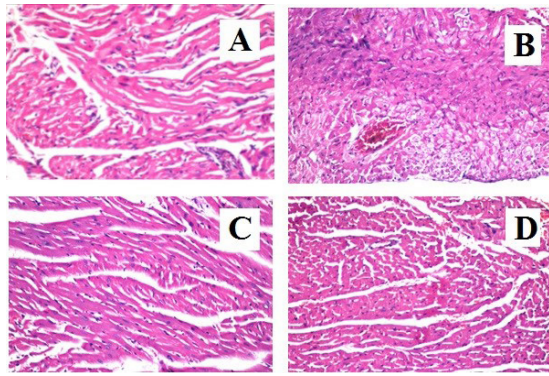
#### Discussion

The present study showed a marked decrease in the cardiac

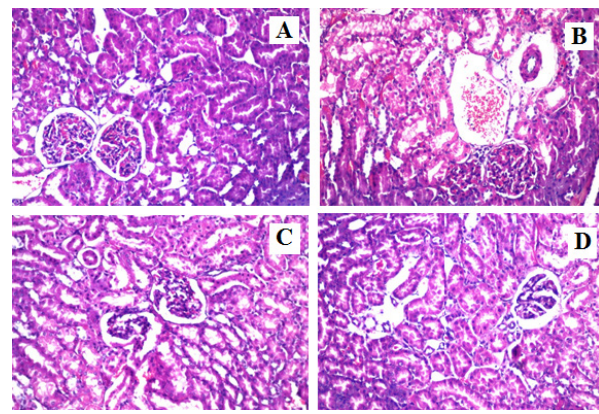


**Figure 2.** Effect of Eicosapentaenoic Acid and Vitamin E Treatment on the Immunohistochemical Expression of Inducible Nitric Oxide Synthase (iNOS) in Kidney Tissue ( $\times 16$ ): (A) The normal control group showed a small degree of immunostaining of iNOS as illustrated by the brown color ( $\times 16$ ), (B) The doxorubicin control group showed severe increased expression of iNOS in kidney tissues, (C) Eicosapentaenoic acid treated group showed moderate positive immunoreaction of iNOS in kidney tissue, (D) Vitamin E treated group showed mild positive immunoreaction of iNOS, (E) Quantification of iNOS staining represents the number of stained (positive) cells per ( $16\times$ ) field was averaged across 6 fields for each rat section. Each value represents mean  $\pm$  SD ( $n = 6$ ) <sup>a</sup> significantly different from normal control group at  $P < 0.05$ , <sup>b</sup> significantly different from doxorubicin control group at  $P < 0.05$ .

antioxidant GSH content combined with a significant increase in the cardiac lipid peroxides following doxorubicin treatment. These results are in harmony with previous studies that demonstrated the ability of doxorubicin to intercalate DNA and generate reactive oxygen species such as superoxide anion, hydrogen peroxide, and hydroxyl radicals which result in the conversion of membrane unsaturated fatty acids into lipid peroxides leading to disturbed integrity of cell membrane and consequently to tissue injury.<sup>13, 14</sup> In addition, Cardiac GPx activity decreased significantly in the current study. As GSH is the substrate for GPx, the decrease in GSH content produced this suppression of GPx activity in heart tissue.<sup>15</sup> In addition, kidney tissue of rats injected with doxorubicin alone, in the current study, showed a significant increase in MDA content accompanied by a significant increase in GSH content. Moreover, the renal SOD activity declined significantly as an indication of the potent oxidative potential of the doxorubicin on the kidneys. Regarding the pro-inflammatory mediator TNF- $\alpha$ , both cardiac and renal tissue showed significant elevation in TNF- $\alpha$  content upon doxorubicin treatment in the current study. These results are in agreement with a previous study.<sup>16</sup> Moreover, the MPO activity elevated significantly with doxorubicin injection as compared to the normal rats in the present study. MPO is an enzyme expressed in neutrophils



**Figure 3.** Effect of Eicosapentaenoic Acid and Vitamin E Treatment on the Histological Structure of the Heart Tissue in Rats With Doxorubicin Toxicity: Hematoxylin and Eosin Staining (H&E×16): (A) Section of a heart from a normal rat showed normal histological structure of heart tissue, being composed of muscle cells, cardiomyocytes, with one centrally placed nucleus; (B) Section of heart of a rat in doxorubicin control group showed degenerative changes in the myocardial muscle bundles associated with congestion in the myocardial blood vessel; (C) Section of heart of a rat in eicosapentaenoic acid pretreated group showed a marked protection from the deleterious effects of doxorubicin with almost normal histological structure; (D) Section of heart of a rat in vitamin E pretreated group showed a noticeable preservation from the doxorubicin effects with marked decrease in inflammatory cells infiltration.



**Figure 4.** Effect of eicosapentaenoic acid and vitamin E treatment on the histological structure of the kidney in rats with doxorubicin toxicity: (A) normal rats: normal histological structure of kidney tissue, being composed of glomeruli and tubules at the cortex; (B) Doxorubicin control rats: showed swelling of the tubular lining epithelium at the cortex with degenerative changes. The corticomedullary portion showed severe congestion in the blood vessels associated with focal hemorrhage in between the degenerated tubules; (C) Eicosapentaenoic acid treated rats: showed a marked protection from the deleterious effects of doxorubicin with marked suppression of the inflammatory cells infiltration; (D) Vitamin E treated rats: showed a noticeable preservation from the doxorubicin effects with no histological alterations. (H&E×16).

and monocytes. This enzyme generates ROS that contribute to the destruction and killing of the engulfed pathogens. It has been demonstrated that MPO is involved in cellular homeostasis and plays an important role in the initiation and progression of acute and chronic inflammatory diseases.<sup>17</sup> MPO enzyme was reported to be involved in the modulation of immune responses and inflammation and inhibition of nitric oxide production.<sup>18</sup>

The present work demonstrated that doxorubicin can cause marked tissue injury through the increased expression of iNOS. The toxic effects of iNOS are due to the induction of peroxynitrites that are generated when nitric oxide reacts with O<sub>2</sub>.<sup>19</sup> Peroxy-nitrites are known to damage DNA, activating poly-polymerase, leading to an energetic imbalance and eventual cell death.<sup>20</sup> Furthermore, the present study showed the apoptotic potential of doxorubicin

through the massively increased production of the pro-apoptotic cytochrome c protein in the heart tissue. These results coincided with another study reporting the apoptotic potential of doxorubicin which could be attributed to the free radicals generated within the mitochondria during doxorubicin metabolism that attack the mitochondrial membrane phospholipids resulting in loss of mitochondrial membrane potential and consequently release of cytochrome c into the cytosol. Released cytochrome c forms a complex with apoptosis protease activation factor-1 recruiting and activating the initiator caspase-9 and resulting in apoptosis.<sup>21</sup> The present work also revealed the doxorubicin cardiac and renal toxicities through the obvious histological alterations as the marked tissue degeneration and necrosis combined with focal inflammatory cells infiltration.

Interestingly, pretreatment with either eicosapentaenoic

**Table 3.** Severity of Histopathological Alterations in the Hearts of Different Experimental Groups Showing Histological Scoring Analysis

Histopathological Findings	Normal Control	Doxorubicin control	Eicosapentaenoic acid	Vitamin E
Degenerated myocardial cells	-	+++	-	-
Focal inflammatory cells infiltration	-	+++	-	+
Edema in the hyalinized myocardium	-	+++	-	+

(-) no damage, (+) mild, (++) moderate, and (+++) severe negative features

**Table 4.** Severity of Histopathological Alterations in The Kidneys of Different Experimental Groups Showing Histological Scoring Analysis

Histopathological Findings	Normal Control	Doxorubicin Control	Eicosapentaenoic acid	Vitamin E
Degenerated tubular lining epithelium	-	+++	-	-
Focal inflammatory cells infiltration in between the tubules	-	+++	+	+
Swelling and vacuolization of the endothelial cells lining the glomeruli tufts	-	+++	-	-

(-) no damage, (+) mild, (++) moderate, and (+++) severe negative features

acid or vitamin E produced significant protection from the deleterious effects of doxorubicin on cardiac and renal tissues. Eicosapentaenoic acid significantly increased the GSH content and GPx activity in heart tissue. These were accompanied by a marked suppression in the cardiac MDA content. These results are in line with a previous study that reported the potent antioxidant potential of all the omega-3 polyunsaturated fatty acids.<sup>7</sup> Moreover, eicosapentaenoic acid pretreatment in the current study produced a potent anti-inflammatory effect that was reflected through the significant decrease in cardiac TNF- $\alpha$  content and hence it can aid in cardiac tissue protection. Previous studies suggested the cardio-protective effects of fish oil omega-3 polyunsaturated fatty acids through their anti-inflammatory potential.<sup>22, 23</sup> The current study suggested that the cardio-protective effects of fish oil omega-3 polyunsaturated fatty acids can be attributed to eicosapentaenoic acid in particular. Furthermore, pretreatment with eicosapentaenoic acid in the present work significantly normalized the pro-apoptotic protein cytochrome c production in heart tissue which suggested another mechanism of eicosapentaenoic acid-induced cardio-protective effect. Eicosapentaenoic acid was previously reported to protect from the diabetic tubular injury through its anti-apoptotic potential that was demonstrated through significant decrease in grades of immunostaining for caspase-3, caspase-9, and cytochrome c.<sup>24</sup> All these mentioned antioxidant, anti-inflammatory and anti-apoptotic properties can predict a powerful protection from the doxorubicin cardiotoxicity upon eicosapentaenoic acid pretreatment and this was demonstrated in the current study through the significant decrease in cardiac CK-MB content and the normalized histological structure of heart tissue.

Examination of the kidneys in the current study revealed the potent antioxidant effect of eicosapentaenoic acid that was significantly able to increase the GSH content and the antioxidant SOD activity in the kidneys accompanied by a marked decrease in the renal lipid peroxides as compared to the doxorubicin control group. Regarding the anti-inflammatory effect on the kidney, the eicosapentaenoic acid pretreatment produced a significant decrease in the renal TNF- $\alpha$  content beside the marked suppression in the MPO activity in the kidneys when compared to the doxorubicin control group. Moreover, pretreatment with eicosapentaenoic acid showed a significant decrease in iNOS expression in the kidneys which offered another mechanism for renal protection. The renal protective effect eicosapentaenoic acid was obvious upon histological examination of the kidneys in the current study that reflected a marked protection from the deleterious effects of doxorubicin with just mild degenerative changes in the tubular lining epithelium. These results are in agreement with another study which reported that administration of fish oil containing omega-3 fatty acids can produce renal protective effects and could significantly suppress the tacrolimus-induced nephrotoxicity in rats.<sup>25</sup> In addition, another study demonstrated that fish oil rich in eicosapentaenoic acid can protect against oxidative stress-related renal dysfunction induced by the organic pollutants

TCDD in Wistar rats.<sup>26</sup>

In the current study, the group pretreated with vitamin E showed significant increase in cardiac and renal GSH contents combined with a significant decrease in cardiac and renal lipid peroxides. In addition, it showed a marked increase in cardiac GPx activity and renal SOD activity. These results reflected the potent antioxidant properties of vitamin E and are in line with previous studies that showed the ability of vitamin E to decrease lipid peroxides and increase the antioxidant enzymes, and therefore could protect from nephrotoxicity in rats treated with cisplatin<sup>27</sup> alongside its cardiac protective effects against isoproterenol induced cardiac infarction in rats.<sup>28</sup>

The vitamin E pretreated group also showed a significant decrease in the cardiac and renal TNF- $\alpha$  contents with a significant suppression of the MPO activity in the kidneys when compared to the doxorubicin control group. These results suggested the potent anti-inflammatory properties of vitamin E which aided in the cardiac and renal tissues protection from the deleterious effects of doxorubicin. Another study reported the suppression of TNF- $\alpha$  expression upon treatment with vitamin E in amikacin-induced renal injury in rats and that reflected the vitamin E anti-inflammatory properties.<sup>29</sup> In addition, the study of Huwait and Al-Ghamdi<sup>28</sup> reported the significant decrease of the cardiac TNF- $\alpha$  contents upon vitamin E treatment in infarcted rat model.

Moreover, the group pretreated with vitamin E showed a marked decrease in cytochrome c expression in the heart with obvious suppression in iNOS expression in the kidney as compared to the doxorubicin control group. These results demonstrated ROS scavenging properties and the anti-apoptotic potential of vitamin E. A previous study has reported the possible anti-apoptotic effect of vitamin E through suppression of caspase-3 expression in rats with arsenic acid toxicity.<sup>30</sup> The beneficial effects of vitamin E were reflected in the current study by the significantly decreased CK-MB activity and the histological examination of heart and kidney tissues that showed a noticeable preservation from the doxorubicin effects with no histological alterations.

In conclusion, both eicosapentaenoic acid and vitamin E are potent anti-oxidants and anti-inflammatory agents which can be considered as hopeful anti-apoptotic agents. They are promising agents to be used for protection against the deleterious effects of doxorubicin chemotherapy.

#### Authors' Contribution

Both authors shared in the study design, the practical work, data analysis and writing the manuscript.

#### Conflict of Interest Disclosures

The authors declared no potential conflicts of interest with respect to research, authorship and publication of this article.

#### Ethical Statement

The study was done under the universal guide lines with the approval of the ethics committee of October University for Modern Sciences and Arts.

#### Acknowledgments

The authors are very grateful to Dr. Adel M. Bakeer, Professor of

pathology, Faculty of Veterinary Medicine, Cairo University, for examining and interpreting the histopathologic aspects of this study

## References

- Nonaka M, Kurebayashi N, Murayama T, Sugihara M, Terawaki K, Shiraishi S, et al. Therapeutic potential of ghrelin and des-acyl ghrelin against chemotherapy-induced cardiotoxicity. *Endocr J*. 2017;64(Suppl.):S35-s9. doi: 10.1507/endocrj.64.S35.
- Ajith TA, Hema U, Aswathi S. Zingiber officinale Roscoe ameliorates anticancer antibiotic doxorubicin-induced acute cardiotoxicity in rat. *J Exp Ther Oncol*. 2016;11(3):171-5.
- Veena RK, Ajith TA, Janardhanan KK. Lingzhi or Reishi Medicinal Mushroom, *Ganoderma lucidum* (Agaricomycetes), Prevents Doxorubicin-Induced Cardiotoxicity in Rats. *Int J Med Mushrooms*. 2018;20(8):761-74. doi: 10.1615/IntJMedMushrooms.2018027010.
- Hsu HC, Chen CY, Chen MF. N-3 polyunsaturated fatty acids decrease levels of doxorubicin-induced reactive oxygen species in cardiomyocytes -- involvement of uncoupling protein UCP2. *J Biomed Sci*. 2014;21:101. doi: 10.1186/s12929-014-0101-3.
- Chung HF, Long KZ, Hsu CC, Al Mamun A, Jhang HR, Shin SJ, et al. Association of n-3 polyunsaturated fatty acids and inflammatory indicators with renal function decline in type 2 diabetes. *Clin Nutr*. 2015;34(2):229-34. doi: 10.1016/j.clnu.2014.02.009.
- Ito S, Sano Y, Nagasawa K, Matsuura N, Yamada Y, Uchinaka A, et al. Highly purified eicosapentaenoic acid ameliorates cardiac injury and adipose tissue inflammation in a rat model of metabolic syndrome. *Obes Sci Pract*. 2016;2(3):318-29. doi: 10.1002/osp4.50.
- Xue H, Ren W, Denking M, Schlotzer E, Wischmeyer PE. Nutrition Modulation of Cardiotoxicity and Anticancer Efficacy Related to Doxorubicin Chemotherapy by Glutamine and omega-3 Polyunsaturated Fatty Acids. *JPEN J Parenter Enteral Nutr*. 2016;40(1):52-66. doi: 10.1177/0148607115581838.
- Jung H, Chen CO, Blumberg JB, Kwak HK. The effect of almonds on vitamin E status and cardiovascular risk factors in Korean adults: a randomized clinical trial. *Eur J Nutr*. 2018;57(6):2069-79. doi: 10.1007/s00394-017-1480-5.
- Darwish MA, Abo-Youssef AM, Khalaf MM, Abo-Saif AA, Saleh IG, Abdelghany TM. Vitamin E mitigates cisplatin-induced nephrotoxicity due to reversal of oxidative/nitrosative stress, suppression of inflammation and reduction of total renal platinum accumulation. *J Biochem Mol Toxicol*. 2017;31(1):1-9. doi: 10.1002/jbt.21833.
- Kumagai Y, Sobajima J, Higashi M, Ishiguro T, Fukuchi M, Ishibashi K, et al. Coexpression of COX-2 and iNOS in Angiogenesis of Superficial Esophageal Squamous Cell Carcinoma. *Int Surg*. 2015;100(4):733-43. doi: 10.9738/intsurg-d-14-00234.1.
- Bancroft JD, Stevens A, Turner DR. Theory and practice of histological techniques. 4th ed. London: Churchill Livingstone; 1996.
- Tukey JW. Reminder sheets for " Discussion of paper on multiple comparisons by Henry Scheffe". In: Tukey JW VIII, ed. *Multiple Comparisons*. New York: Chapman and Hall; 1951.
- Shoukry HS, Ammar HI, Rashed LA, Zikri MB, Shamaa AA, Abou Elfadl SG, et al. Prophylactic supplementation of resveratrol is more effective than its therapeutic use against doxorubicin induced cardiotoxicity. *PLoS One*. 2017;12(7):e0181535. doi: 10.1371/journal.pone.0181535.
- Uygur R, Aktas C, Tulubas F, Alpsoy S, Topcu B, Ozen OA. Cardioprotective effects of fish omega-3 fatty acids on doxorubicin-induced cardiotoxicity in rats. *Hum Exp Toxicol*. 2014;33(4):435-45. doi: 10.1177/0960327113493304.
- Abdel-Daim MM, Kilany OE, Khalifa HA, Ahmed AAM. Allicin ameliorates doxorubicin-induced cardiotoxicity in rats via suppression of oxidative stress, inflammation and apoptosis. *Cancer Chemother Pharmacol*. 2017;80(4):745-53. doi: 10.1007/s00280-017-3413-7.
- Zhang J, Cui L, Han X, Zhang Y, Zhang X, Chu X, et al. Protective effects of tannic acid on acute doxorubicin-induced cardiotoxicity: Involvement of suppression in oxidative stress, inflammation, and apoptosis. *Biomed Pharmacother*. 2017;93:1253-60. doi: 10.1016/j.biopha.2017.07.051.
- Olza J, Aguilera CM, Gil-Campos M, Leis R, Bueno G, Martinez-Jimenez MD, et al. Myeloperoxidase is an early biomarker of inflammation and cardiovascular risk in prepubertal obese children. *Diabetes Care*. 2012;35(11):2373-6. doi: 10.2337/dc12-0614.
- van der Veen BS, de Winther MP, Heeringa P. Myeloperoxidase: molecular mechanisms of action and their relevance to human health and disease. *Antioxid Redox Signal*. 2009;11(11):2899-937. doi: 10.1089/ars.2009.2538.
- Neilan TG, Blake SL, Ichinose F, Raheer MJ, Buys ES, Jassal DS, et al. Disruption of nitric oxide synthase 3 protects against the cardiac injury, dysfunction, and mortality induced by doxorubicin. *Circulation*. 2007;116(5):506-14. doi: 10.1161/circulationaha.106.652339.
- Octavia Y, Tocchetti CG, Gabrielson KL, Janssens S, Crijns HJ, Moens AL. Doxorubicin-induced cardiomyopathy: from molecular mechanisms to therapeutic strategies. *J Mol Cell Cardiol*. 2012;52(6):1213-25. doi: 10.1016/j.yjmcc.2012.03.006.
- Mantawy EM, Esmat A, El-Bakly WM, Salah ElDin RA, El-Demerdash E. Mechanistic clues to the protective effect of chrysin against doxorubicin-induced cardiomyopathy: Plausible roles of p53, MAPK and AKT pathways. *Sci Rep*. 2017;7(1):4795. doi: 10.1038/s41598-017-05005-9.
- Ma Y, Lindsey ML, Halade GV. DHA derivatives of fish oil as dietary supplements: a nutrition-based drug discovery approach for therapies to prevent metabolic cardiotoxicity. *Expert Opin Drug Discov*. 2012;7(8):711-21. doi: 10.1517/17460441.2012.694862.
- Sokola-Wysoczanska E, Wysoczanski T, Wagner J, Czyz K, Bodkowski R, Lochynski S, et al. Polyunsaturated Fatty Acids and Their Potential Therapeutic Role in Cardiovascular System Disorders-A Review. *Nutrients*. 2018;10(10). doi: 10.3390/nu10101561.
- Taneda S, Honda K, Tomidokoro K, Uto K, Nitta K, Oda H. Eicosapentaenoic acid restores diabetic tubular injury through regulating oxidative stress and mitochondrial apoptosis. *Am J Physiol Renal Physiol*. 2010;299(6):F1451-61. doi: 10.1152/ajprenal.00637.2009.
- Fernandes MB, Caldas HC, Toloni LD, Baptista MA, Fernandes IM, Abbud-Filho M. Supplementation with omega-3 polyunsaturated fatty acids and experimental tacrolimus-induced nephrotoxicity. *Exp Clin Transplant*. 2014;12(6):522-7.
- Palaniswamy KS, Vishwanadha VP, Ramalingam Singaravelu S. Fish oil rich in eicosapentaenoic acid protects against oxidative stress-related renal dysfunction induced by TCDD in Wistar rats. *Cell Stress Chaperones*. 2014;19(3):409-19. doi: 10.1007/s12192-013-0470-7.
- Aksoy A, Karaoglu A, Akpolat N, Naziroglu M, Ozturk T, Karagoz ZK. Protective Role of Selenium and High Dose Vitamin E against Cisplatin - Induced Nephrotoxicity in Rats. *Asian Pac J Cancer Prev*. 2015;16(16):6877-82.
- Huwait EA, Al-Ghamdi MA. Protective role of carnitine synergized with vitamin E against isoproterenol induced cardiac infarction in rats. *Afr J Tradit Complement Altern Med*. 2017;14(2):25-32. doi: 10.21010/ajtcam.v14i2.4.
- Selim A, Khalaf MM, Gad AM, Abd El-Raouf OM. Evaluation of the possible nephroprotective effects of vitamin E and rosuvastatin in amikacin-induced renal injury in rats. *J Biochem Mol Toxicol*. 2017;31(11). doi: 10.1002/jbt.21957.
- Oyagbemi AA, Omobowale TO, Ola-Davies OE, Adejumo OA, Asenuga ER, Adeniji FK, et al. Protective Effect of Azadirachta indica and Vitamin E Against Arsenic Acid-Induced Genotoxicity and Apoptosis in Rats. *J Diet Suppl*. 2018;15(3):251-68. doi: 10.1080/19390211.2017.1336147.

