

## Review Article

# Pharmacologic Treatment of Wet Type Age-related Macular Degeneration; Current and Evolving Therapies

Hoda Shams Najafabadi<sup>1</sup>, Narsis Daftarian<sup>2</sup>, Hamid Ahmadih<sup>3</sup>, Zahra-Soheila Soheili<sup>1\*</sup>

## Abstract

Age-related macular degeneration as the major cause of blindness in the elderly population has remained at the epicenter of clinical research in ophthalmology. This retinal disorder is characterized by the photoreceptor and retinal pigment epithelial cells loss, occurring within the macula. The disease represents a spectrum of clinical manifestations. It is a multifactorial disease resulting from a combination of genetic predispositions and environmental risk factors. AMD is classified into two different types, dry and wet. Wet AMD is in close relation with angiogenesis and inflammatory processes. A variety of anti-angiogenesis and anti-inflammatory drugs have been proposed for the treatment of the disease. The purpose of this paper is to briefly review the pharmacological therapies of the wet form of AMD and focus on new drugs that are currently in different stages of research and development.

**Keywords:** Age-related macular degeneration, angiogenesis, anti-angiogenesis drugs, anti-inflammatory drugs, inflammation

**Cite this article as:** Shams Najafabadi H, Daftarian N, Ahmadih H, Soheili ZS, et al. Pharmacologic Treatment of Wet Type Age-related Macular Degeneration; Current and Evolving Therapies. *Arch Iran Med.* 2017; 20(8): 525 – 537.

## Introduction

Age-related macular degeneration was first introduced in the medical literature in 1875 as a symmetrical central chorioretinal disease occurring in the elderly.<sup>1</sup> It was not studied until 1980 when macular degeneration was reported to be a leading cause of blindness in the United States.<sup>2</sup> According to World Health Organization estimates, AMD is the most common cause of blindness in people over the age of 50 in developed countries (Figure 1).<sup>3</sup>

About 35% of the U.S. population aged 75 years or more have some signs of AMD and approximately 10% of these patients demonstrate late stages of the disease.<sup>4</sup> Nowadays, more than 25 to 30 million people are affected by AMD worldwide.<sup>5</sup> According to the latest predictions, AMD is expected to undergo a nearly 2-fold increase in 2020.<sup>6</sup>

Due to the progressive deterioration in the patients' central vision, the ability to perform daily activities such as driving, reading, ambulating, walking and recognizing people's faces is decreased.<sup>7</sup>

Progression of AMD reduces the patient's sense of well-being and independence and increases the risk of depression. Patients with AMD in both eyes, especially if accompanied by hemorrhage in the macular area, are at high risk of falls and depression. Overall, AMD leads to significant reduction in mental health and patient's quality of life.<sup>8,9</sup>

**Authors' affiliations:** <sup>1</sup>National Institute of Genetic Engineering and Biotechnology, Tehran, Iran. <sup>2</sup>Ophthalmic Research Center, Shahid Beheshti University of Medical Sciences, Tehran, Iran. <sup>3</sup>Ocular Tissue Engineering Research Center, Shahid Beheshti University of Medical Sciences, Tehran, Iran. **\*Corresponding author and reprints:** Zahra-Soheila Soheili, National Institute of Genetic Engineering and Biotechnology, Shahrak-e Pajooesh, km 15, Tehran-Karaj Highway, Tehran 14965161, Iran. E-mail: soheili@nigeb.ac.ir. Accepted for publication: 27 April 2017

## Anatomy of the eye

The human eye has three main layers. The outermost layer of the eye is called the sclera, which is composed of connective tissue that maintains the shape of the globe and offers resistance to internal and external forces.

The choroid is the middle layer of the eye located between the sclera and the retina. The inner part of choroid is composed of a capillary network and the outermost layer consists of larger-diameter blood vessels. The main function of the choroid is to provide enough oxygen and nutrients to the retinal pigment epithelium<sup>10</sup> and the outermost layers of the retina as well as to remove waste products from their environment.

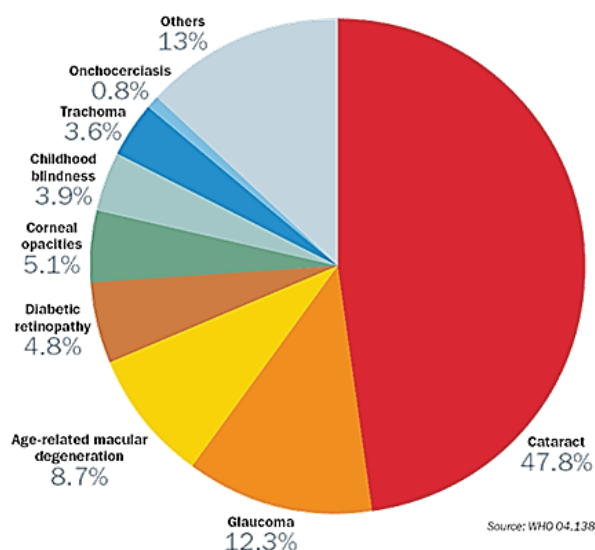
The retina is the inner part of the eye with two main layers: the more posterior RPE layer consists of retinal pigment epithelial cells and the inner neurosensory layer which consists of a variety of different nerve cells and photoreceptors in a layered and complex configuration.

RPE cells are separated from the choroid by a semi-permeable matrix called Bruch's membrane (BM) which facilitates the passage of nutrients and metabolites between the choroid and the retina (Figure 2).<sup>11</sup>

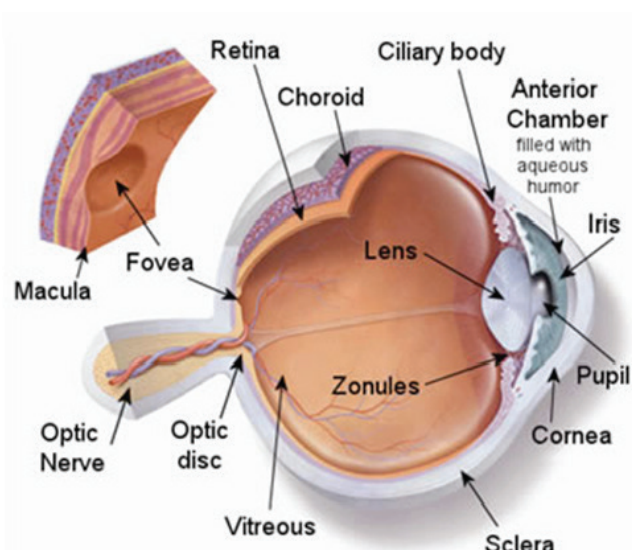
## Pathology of AMD

AMD occurs when the photoreceptor cells in the macula are slowly broken down or damaged. Macula is made up of the highest density of cones photoreceptor cells responsible for a central, high resolution vision with precision detail. There are two main types of macular degeneration: dry, non-exudative or atrophic AMD and exudative or wet AMD. Approximately 90% of cases of macular degeneration are the dry type.

As with any disease, AMD exhibits a spectrum of clinical and pathologic manifestations. In the case of dry AMD, the clinical signs can range from early pigmentary changes in the macula



**Figure 1.** According to the World Health Organization estimate, AMD is third most common worldwide cause of blindness. **Sourced:** www.unmc.edu/eye/internationalmission.htm.



**Figure 2.** The human eye in the inner layer is composed of the sclera, choroid and retina. AMD is caused by damage to macula or yellow spot. **Source:** www.eastoneye.com

to presence of Drusen (yellow deposits of extracellular material under the neural retina or RPE cells), of which the number and size can be increased distributing throughout the macula.<sup>12</sup> Gradually, the density of choroidal blood vessels is reduced and RPE cells are atrophied.

The more advanced stage of dry macular degeneration is geographic atrophy, which appears as a circumscribed area of RPE and photoreceptor cell loss. To compensate for this loss, peripheral RPE cells proliferate; therefore, hypertrophied RPE cells are observed in these areas.<sup>13</sup>

Exudative macular degeneration is marked by growth of aberrant blood vessels under the retina, photoreceptor cells and Bruch's membrane along with epithelial proliferation and inflammation. This process is due to the release of vascular endothelial growth factor (VEGF) as angiogenic factor from RPE cells,<sup>14</sup> which leads to formation of a choroidal neovascular membrane (CNVM). CNVM can leak hemorrhage in the subretinal space that induces blurry vision and finally creates a disciform scar which causes total central vision loss.<sup>15</sup>

### Etiology of AMD

AMD is a complex multifactorial disease resulting from interactions between genetic variants and environmental factors. These factors induce oxidative damage and structural changes in the retina and RPE producing a cascade of events including the inflammatory intermediates that interrupt cells activity and destroy them.

Among environmental factors associated with AMD, only advanced age, cigarette smoking, diet, and race are the most important factors.<sup>16</sup>

Age-associated increase in AMD risk may be mediated by gradual accumulation of daily oxidative stress in the retina and loss of normal physiological function in the aging RPE cells.<sup>17</sup>

Recent studies have demonstrated that white people are much more likely to lose vision from AMD than other races.<sup>18</sup>

Studies have also demonstrated that smokers are three to four times more likely to develop AMD.<sup>19</sup> The general mechanisms by which smoking results in AMD include: impairment in the generation of antioxidants such as vitamin C, generation of reactive oxygen species, activation of inflammatory pathways and reduction of choroidal blood flow.<sup>20</sup>

People with a family history of AMD are at a higher risk of developing AMD.<sup>21</sup>

Obesity and high-fat diets containing cholesterol and saturated fats increase the risk of AMD<sup>22</sup> while taking antioxidants in the early stages of the disease may play a role in curbing its progression.<sup>23</sup>

The AREDS (Age-Related Eye Disease Study) demonstrated that a series of compounds such as vitamin C, vitamin E, beta-carotene, zinc oxide and copper oxide as dietary supplements in patients with intermediate and advanced AMD in one eye, lower the risk of late stage AMD in the other eye.<sup>24</sup> Taking beta-carotene might put smokers at higher risk of lung cancer, so they should take dietary supplements without beta-carotene.

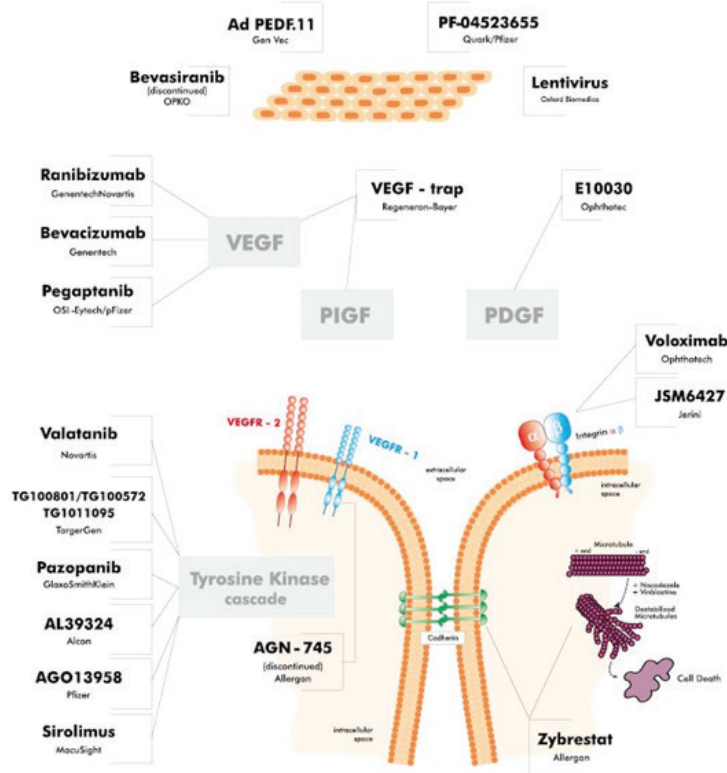
Taking antioxidants such as lutein and zeaxanthin that are found in green leafy vegetables such as broccoli, corn, squash and omega-3 fatty acids which are found in fish, play a vital role in preventing intermediate or advanced AMD.<sup>10,25</sup>

Consumption of mono- and poly-unsaturated fatty acids and linoleic acid was especially associated with an elevated risk for AMD.<sup>26</sup>

### Treatment Strategies for Wet AMD

AMD is a complex, multifactorial disease associated with environmental, dietary, and genetic factors. There is no known definite treatment for either type of this disease. Available treatment methods can only reduce the risk of severe vision loss.

These methods include thermal laser photocoagulation, transpupillary thermotherapy, radiotherapy, photodynamic therapy and pharmacologic treatment. This review article is devoted entirely to the last topic.



**Figure 3.** Strategies to inhibit the VEGF signaling pathway include inhibition of VEGF, VEGFR and tyrosine kinase cascade. Sourced: www.amdbook.org

### Pharmacotherapy for wet AMD

Wet AMD occurs due to adventitious growth of blood vessels into the retina along with endothelial cell proliferation and inflammation.

Increased knowledge about the molecular mechanisms and pathophysiology of wet AMD has led to the application of novel treatments for this disease. Anti-angiogenic and anti-inflammatory medications are currently used to prevent progression of wet AMD.

#### 1. Anti-angiogenesis drugs

Angiogenesis, i.e. formation of new blood vessels from the pre-existing ones, is essential for physiological processes such as embryonic development, tissue and organ regeneration, the female reproductive cycle, wound healing and inflammation. Despite the fact that angiogenesis plays an important physiological role, it may also result in pathologic conditions. Abnormal blood vessel growth has a crucial role in wet AMD, tumorigenesis and metastases.<sup>27</sup>

The process of angiogenesis in wet AMD is induced by generation of vascular endothelial growth factor (VEGF) from the RPE cells which binds to tyrosine kinase receptors (VEGFR) on the cell surface and the signaling cascade leading to angiogenesis is triggered.<sup>28</sup> Platelet-derived growth factor (PDGF) is one of the numerous growth factors that regulate cell growth and division and play a significant role in angiogenesis.<sup>29</sup>

Today, different types of drugs with several mechanisms such as

inhibition of VEGF, VEGFR, PDGF and tyrosine kinase activity of VEGFR and decreasing VEGF and VEGFR expression are used or investigated to prevent the development of wet AMD and its progression (Figure 3).

#### A. VEGF inhibitor Antibodies

VEGF, a signaling protein of angiogenesis in neovascular AMD, stimulates vascular endothelial cell growth and survival. The VEGF family includes VEGF-A, B, C and D, and the viral homologue VEGF-E, in addition to the placental growth factor (PlGF). VEGF-A is associated with eye diseases like wet AMD and diabetic retinopathy. Currently available pharmacotherapeutic agents used for treatment of wet AMD block the biological effects of VEGF such as the RNA aptamer pegaptanib, partial and full-length antibodies ranibizumab and bevacizumab, VEGF receptor decoy aflibercept, small interfering RNA-based therapies bevasiranib and AGN211745, sirolimus, and tyrosine kinase inhibitors including vatalanib, pazopanib, TG100801, TG101095, AGO13958 and AL39324.

**Pegaptanib (Macugen, OSI-Eyetech Pharmaceuticals, Pfizer, New York, USA):** A single strand of 28-base ribonucleic acid as a pegylated anti VEGF aptamer binds to VEGF<sub>165</sub> (dominant isoform of VEGF-A in ocular neovascularization processes) and blocks its actions. It was the first anti-VEGF inhibitor to become available for treatment of AMD. Pegaptanib is administered in 0.3 mg doses once every six weeks by intravitreal injection. Its approval was granted by the U.S. Food and Drug Administration (FDA) in December 2004 for treatment of wet AMD.<sup>30</sup>

**Bevacizumab (Avastin, Genentech, South San Francisco, California, USA):** A full-length humanized IgG1 monoclonal antibody with two VEGF-A binding sites binds all isoforms of VEGF and prevents the growth of abnormal blood vessels under or in the retina. Bevacizumab is FDA approved to treat metastatic colorectal, breast, and lung cancer.<sup>31</sup> In 2000, the potential role for bevacizumab in AMD treatment was established when systemic administration of fluorescein-conjugated bevacizumab to cynomolgus monkeys competitively inhibited extravascular VEGF.<sup>32</sup> The first reported case of intravitreal bevacizumab injection was described in 2005 as a case report of a 63-year-old woman with CNV. Four weeks after a single-intravitreal injection of bevacizumab (1 mg), improvements in macula appeared and no adverse effects were observed.<sup>33</sup> Phase I clinical trials (to test a new biomedical intervention for the first time in a small group of 20-80 people to evaluate safety and identify side effects) investigated the safety and efficacy of intravitreal bevacizumab in a case series of 79 patients treated with monthly bevacizumab (1.25 mg) in 2006. Bevacizumab and ranibizumab have the same function; however, bevacizumab differs from ranibizumab in being the complete IgG molecule with less affinity but binding to more isoforms of VEGF. Currently, a randomized clinical trial has demonstrated that bevacizumab is comparable with ranibizumab in terms of visual improvement and possible adverse effects.<sup>34,35</sup> Bevacizumab is usually given once every 4–6 weeks.<sup>36,37</sup>

**Ranibizumab (Lucentis, Novartis Pharma AG, Basel, Switzerland):** It is a monoclonal antibody Fab fragment which binds to all identified VEGF isoforms as an anti-angiogenesis drug. It was engineered to have a 100-time higher binding affinity than bevacizumab. However, absence of the Fc component results in a shorter systemic half-life compared to bevacizumab (about four hours vs. 20 days), better retinal penetration, and decreased Fc-related inflammatory reaction.<sup>38</sup> Some clinicians indicated that the short-term effectiveness of ranibizumab treatment was significantly better than bevacizumab while bevacizumab accumulated within retinal pigment epithelial cells and possibly induced longer action than ranibizumab.<sup>39-41</sup> Bevacizumab is produced in a eukaryotic cell line (CHO cells) while ranibizumab is produced in prokaryotic *E. coli*; therefore, it does not carry glycosylation sites.<sup>42</sup> The drug is injected intravitreally once a month. It prevents progression of wet AMD but does not cure the disease. On June 30, 2006, ranibizumab was approved by the US Food and Drug Administration for the treatment of wet AMD.<sup>43</sup> Clinical studies indicated that intravitreal ranibizumab did not induce significant systemic effects or vascular impairment.<sup>44</sup>

**Aflibercept (Eylea, Regeneron Pharmaceuticals, Tarrytown, New York, USA)** is a fusion protein with binding domains from native VEGF receptors 1 and 2 extracellular domains fused to the Fc portion of human IgG1 which was produced in Chinese hamster ovary (CHO) K1 cells by recombinant DNA technology. It binds VEGF-A, VEGF-B, and placental growth factors 1 and 2 with much stronger affinity than anti-VEGF monoclonal antibodies. In November 2011, aflibercept was approved for treatment of wet AMD.<sup>45</sup> The drug is injected intravitreally 2 mg every 8 weeks, thus reducing the risk of monthly intravitreal injections and the burden of monthly monitoring.<sup>46</sup> Single aflibercept intravitreal injection would last between 48 and 83 days compared to 30 days for a ranibizumab intravitreal injection. A recent study demonstrated

that intravitreal aflibercept injection in patients with persistent macular exudate previously treated with bevacizumab and/or ranibizumab reduced central retinal thickness and total retinal fluid volume with no appreciable change in visual acuity.<sup>47</sup> Phase IV clinical trials (the safety surveillance (pharmacovigilance) and ongoing technical support of a drug after it receives permission to be sold) of this drug were started in 2013 that aflibercept 2 mg (0.05 mL) administered by intravitreal injection every 4 weeks for the first 8 weeks, followed by 2 mg (0.05 mL) via intravitreal injection once every 8 weeks for 36 weeks. It is estimated the project will be completed in 2017 (the clinical trial identifier is NCT02002377).<sup>48</sup>

**DARPin (Allergan, Irvine, California, USA)** is genetically engineered antibody mimetic proteins typically exhibiting highly specific and high-affinity target protein binding. It is derived from natural ankyrin protein and is comprised of at least three, usually four or five repeat motifs of the human ankyrin generated by protein engineering and recombinant DNA technology with high binding affinity towards the VEGF-A.<sup>49</sup> Individual members of the libraries of these molecules were well-expressed in a soluble form in the cytoplasm of *E. coli* and were found to exhibit very favorable thermal (midpoints of denaturation between 66 and 95°C) and thermodynamic stability.<sup>50</sup> Abicipar potentially has a similar effect to ranibizumab with a higher half-life which allows longer intervals between injections.<sup>51</sup> In 2010, the first of these molecules (abicipar pegol or MP0112) entered clinical trials for treating wet AMD. Phase I clinical trials demonstrated safety and tolerability of the drug that is injected intravitreally once every 4 months (NCT01086761). Results of Phase II clinical trials (the experimental treatment is given to a group of 100-300 people to see if it is effective) demonstrated that abicipar pegol provides equal or potentially higher vision gains with very low systemic exposure compared to ranibizumab (NCT02181517).<sup>52</sup> A long ocular half-life (more than 60 days) of this molecule reduced injection by three or four folds compared to current therapy with ranibizumab. Drug delivery with eye drop abicipar pegol improved injection-associated complications with respect to other anti-VEGF drugs. Phase III clinical trials (randomized controlled multicenter trials on large patient groups 300–3000 each, that depend on the disease and medical condition studied) started in the second quarter of 2015 (NCT02462928 and NCT02462486). Abicipar pegol (previously MP0112 or AGN 150998) is the trade name of DARPin.

**NT-503:** Encapsulating VEGF receptor Fc-fusion proteins (VEGFR-Fc) are released from highly producing NT-503 cell line which is implanted into the vitreous cavity. This program was established to address the tremendous treatment burden associated with the requirement for monthly or bimonthly anti-VEGF injections. These kinds of capsules allow oxygen and nutrients to enter the cell while protecting them against the immune system. These cells produce VEGF antagonists as a recombinant protein consisting of the Fc portion of antibodies and VEGFR released directly into the retina. The drug is implanted once every 12 months. Animal studies showed the safety and efficacy of this product.<sup>53</sup>

**Squalamine (Ohr Pharmaceutical, New York, New York, USA):** Small aminosterol molecule inhibits multiple angiogenic

growth factors through a unique intracellular mechanism of action. It binds to the cell membrane-bound regulatory protein calmodulin and chaperons it into the cytoplasm where it becomes unavailable to modulate the downstream signaling of vascular endothelial growth factor (VEGF), platelet-derived growth factor (PDGF) and basic fibroblast growth factor (bFGF). It is a water-soluble molecule derived from the internal organs (primarily the liver) of the dogfish shark; today, eye drop formulation of squalamine is undergoing clinical trials to be used for treatment of wet AMD. Researchers demonstrated that the ability to self-administer eye drops to treat wet AMD is more effective (and less invasive) than the current standard of care, which involves regular injections of lucentis, avastin, or eylea directly into the eye, via a very small needle. Depending on the needs of the patient and the type of drug, it is usually administered twice a day for a month.<sup>54-56</sup> Phase II clinical trial (OHR-002) of Squalamine eye drop in patients with wet AMD demonstrated a benefit in visual acuity in July 2014 (clinical trial identifier is NCT01678963). This included a mean improvement in visual acuity (VA) in the group treated with the eye drops plus ranibizumab as compared to the lucentis monotherapy group at all-time points from 4 to 38 weeks. The Phase III trial for squalamine eye drop was started in the first half of 2015. It is designed to measure the efficacy of combination therapy with OHR-102 eye drops plus lucentis injections compared with lucentis monotherapy at a period of 9 months (NCT02727881).

**KH902 (Chengdu Kanghong Biotechnology Co. Ltd, Chengdu, China):** A recombinant, soluble protein involved binding domains of VEGF receptors 1 and 2 combined with the Fc portion of IgG. This drug has a very high affinity for all VEGF-A isoforms, PlGF 1, PlGF2 and VEGF-B.<sup>57</sup> In a phase I trial, patients were given a single intravitreal injection of 0.05 mg, 0.15 mg, 0.5 mg, 1.0 mg, 2.0 mg, and 3.0 mg KH902 for 12 weeks. Improvement in visual acuity, reduction in central retinal thickness and reduction in CNV area were demonstrated in patients with wet AMD.<sup>58</sup> The Phase II clinical trial (AURORA) confirms the efficacy and safety of multiple injections (0.5mg/eye/time and 2.0mg/eye/time) of KH902 at variable dosing regimen in patients with CNV due to neovascular AMD (NCT01157715). Significant gains in VA were observed at 3 to 12 months in all dosing groups of wet AMD patients in this clinical trial.<sup>59</sup> The Phase III trials (PHOENIX) were designed to prove the efficacy and safety of multiple injections of KH902 comparing intravitreal injections of KH902 with sham-injections. This study was completed in November 2013 but its result has not been published yet (clinical trial identifier is NCT01436864). Conbercept is another name of KH902.

**AAV2-sFLT01 (Genzyme, a Sanofi Company, New York Avenue, Framingham, Massachusetts, USA):** A neutralized adeno-associated virus with sFLT01 (a novel fusion protein with anti angiogenic activity) gene which produces an antagonist to the VEGF protein. AAV2 vectors have minimal toxicity with a potential for long-term expression.<sup>38</sup> The phase I trials assess safety and tolerability of a single intravitreal injection of different doses of AAV2-sFLT01 in patients with wet AMD. It is estimated that this trial will be complete in July 2018 (clinical trial identifier is NCT01024998).

## B. VEGFR inhibitor Antibodies

Three different VEGF receptors have been identified: VEGFR-1 (fms-like tyrosine kinase-1 or Flt-1), VEGFR-2 (kinase insert domain-containing receptor or KDR) and VEGFR-3 (fms-like tyrosine kinase-4 or Flt-4). VEGFRs are expressed by a number of important cell types in the eye, including vascular endothelial cells, choroidal fibroblasts, RPE and inflammatory cells attracted by hypoxia. The affinity of VEGF-A is highest for VEGFR1, VEGFR2 appears to be the primary mediator of VEGF angiogenic activity. VEGFR-1 is a key receptor in developmental angiogenesis during embryonic development, but does not appear to stimulate pathogenic angiogenesis. The majority of downstream angiogenic effects of VEGF including vascular permeability, endothelial cell proliferation, invasion, migration and survival, are mediated by VEGFR-2. In addition to VEGF inhibitor antibodies, VEGFR inhibitor antibodies are another group of drugs for treating wet AMD.

**Volociximab (Ophthotech Corporation, Princeton, New Jersey, USA):** The ligation of fibronectin to  $\alpha 5\beta 1$  is an important step for proliferation of endothelial cells. Volociximab as a chimeric monoclonal antibody blocks this ligation and induces apoptosis of proliferating endothelial cells. However, bevacizumab administered either intravenously or intravitreally prior to the onset of neovascularization significantly reduced angiogenesis. The phase I clinical trials of volociximab are completed but the results have not been published yet (NCT00782093). It is demonstrated that this drug can decrease angiogenesis in the tumor mass. The drug has not been marketed yet.<sup>60</sup> M200 is the code name of this drug.

**AdPEDF (GenVec, Gaithersburg, Maryland, USA):** A recombinant adenovirus (Ad35 serotype) that contains pigment epithelium-derived factor (PEDF) which is one of the most potent antiangiogenic proteins. It inhibits proliferation and migration of the blood vessel endothelial cells in established neovascularization and protects the retina cells from damage. AdPEDF's key difference from other therapies is its potential to protect the photoreceptors from damage. Phase I clinical trials demonstrated safety and feasibility of intravitreal injection of this drug in patients with wet AMD. No dose limiting toxicities or drug related severe adverse events or cases of infection in the eye were observed.<sup>61</sup> The adPEDF is injected once every 3 months. Ad35 vectors provide the ability to achieve long-term gene expression in the eye for treatment of chronic ocular diseases.<sup>62</sup> A Phase II study of AdPEDF is underway for treating patients with early to moderate wet AMD.

## C. VEGF expression inhibitors:

VEGF is a key component in the pathogenesis of CNV which is a precursor of wet AMD. The current standard drug for wet AMD treatment is the monoclonal antibody fragment which targets VEGF or VEGFR. In addition to these drugs, a unique class of drugs has been developed that targets the mRNA encoding VEGF. Small interfering RNA (siRNA)-based drugs have been developed to silence the mRNAs encoding VEGF as a new approach for VEGF inhibition. RNAi is an ideal therapeutic strategy for the eye because of its limited volume required for effective local administration<sup>[63]</sup>.

**Bevasiranib (Opko Health, Miami, Florida, USA):** A small interfering RNA (siRNA) is designed to work by downregulating VEGF-A production in the retina. In 2006, the Nobel Prize was awarded to Andrew Z. Fire and Craig C. Mello for their discovery of bevasiranib as a new era in drug research and development. Bevasiranib (formerly known as Cand5) initially developed by OPKO Ophthalmologics is a 21-nucleotide RNA duplex that suppresses the expression of VEGF, thus preventing the CNV.<sup>64</sup> Phase III clinical trials of the RNAi drug were started in 2011 with bevasiranib (2.5mg) administered intravitreally either every 8 or 12 weeks as a maintenance therapy following three injections of ranibizumab (0.5mg) but the results have not been published yet (clinical trial identifier is NCT00557791). The effects of bevasiranib as the only drug for treatment do not appear until six weeks after the commencement of treatment. It inhibits the synthesis of new VEGF but does not eliminate existing VEGF. A direct anti-VEGF agent may be required to neutralize VEGF that is already present in the eye. Over 30% of patients on combination therapy of ranibizumab and bevasiranib achieve three more lines of visual acuity than those on Lucentis.<sup>65</sup> Bevasiranib is delivered as a naked siRNA molecule in humans. Recent studies have suggested that naked RNA is not taken up into cells due to an innate immune reaction.<sup>66</sup> This certainly warrants further investigations. OPKO is the trade name for bevasiranib.<sup>67</sup>

**PF-4523655 (Quark/Pfizer, Denver, Colorado, USA):** A naked, 19bp blunt-ended synthetic AtuRNAi molecule which inhibits the DNA damage-inducible transcript 4 (DDIT4) genes (also known as REDD1 and RTP-801). This gene is involved in abnormal blood vessel development and leakage in the eye. Phase II clinical trials demonstrated that the drug is safe and well-tolerated in patients with wet AMD who failed to respond to currently approved therapies. This drug acts in a dose-related manner, starting as early as the first day after its single intravitreal administration, for up to 14 days. RTP801i-14 is another name of this medicine.<sup>68</sup>

**Anecortave (Manhattan Eye, Ear & Throat Hospital, New York, New York, USA):** An angiostatic steroid that is investigated for treatment of AMD. It is injected with a blunt-tipped, curved cannula in the juxtasclear space overlying the macula. Because the drug is slowly released to the choroid, the injections are only given every six months. This novel method of drug delivery avoids the most common side effects associated with injecting therapeutic agents directly into the eye. It is usually administered with verteporfin and radiation therapy and usually helps to reduce the frequency of radiation therapy. It is used during the time between two consecutive steps of radiation.<sup>69,70</sup> Phase II clinical trials of anecortave confirmed the effect of anecortave acetate (15 mg or 30 mg) versus placebo following initial Visudyne PDT, for treatment of wet AMD (NCT00211458).<sup>71,72</sup> In 2006, anecortave acetate received FDA approval for treatment of wet AMD. Phase III clinical trials of anecortave were completed in 2008, with the result confirming that the drug is not efficient for treatment of wet AMD and development of the drug was terminated (NCT00065728). Its brand name is Retaane.

#### D. VEGFR expression inhibitor antibodies

VEGF has 2 cell surface receptors: VEGF receptor 1 (VEGFR-1) and VEGF receptor 2 (VEGFR-2). These receptors are potential

targets for treatment of wet AMD. Inhibition of VEGF receptor with multiple ligands may have a greater effect than simply inhibiting the action of VEGF. RNAi-mediated knockdown of VEGF receptor (VEGF-R) in the retina may lead to inhibition of abnormal new blood vessel growth and improvement of vision.

**Sirna-027(Allergan, Irvine, California, USA):** is a modified short interfering RNA (siRNA) that silences human, cynomolgus monkey, mouse and rat VEGFR-1 mRNA molecules found on vascular endothelial cells. It is stimulated by VEGF and placental growth factor (PlGF), causing the growth of new blood vessels. Phase I trial of sirna-027 revealed that 92% of the subjects showed clinically significant improvement in visual acuity. Phase II clinical trials demonstrated that intravitreal injection of this drug did not provide visual improvement and the development of the drug was halted in 2007 (clinical trial identifier is NCT00363714). AGN211745 is another name of this medicine.<sup>73</sup>

#### E. PDGF (Platelet derived growth factor) inhibitor

PDGF is one of the numerous growth factors which plays a significant role in blood vessel formation (angiogenesis). The PDGF family consists of PDGF-A, -B, -C and -D, which form either homo- or heterodimers (PDGF-AA, -AB, -BB, -CC, -DD). Pericytes are contractile cells that wrap around the endothelial cells of capillaries. Their presence on capillaries leads to new vessel support and stabilization. Coating of the new vessel endothelial cells by pericytes is initiated by endothelial cell expression of homo dimer PDGF-BB. PDGF-BB by binding PDGFR- $\beta$  receptor initiates the proliferation and migration of pericytes along the growing neovascularization. Pericytes line the outer wall of endothelial cells and limit the effect of anti-VEGF therapy. It is believed that an effective anti-PDGF agent can strip the pericytes in the new vessel and strengthen the function of anti-VEGF agent. Studies demonstrated that blocking the PDGF leads to lack of pericyte coverage, vascular abnormalities and inhibition of NV capillary maturation.<sup>74</sup>

**E10030 (Ophthotech Corporation, Princeton, New Jersey, USA):** 32-mer DNA-based oligonucleotide attached via two polyethylene glycols (PEG) to the 5' end. This aptamer binds to PDGF-B as the major factor of angiogenesis with high specificity and affinity and inhibits the function of PDGF-B both *in vitro* and *in vivo*. The phase I clinical trials demonstrated the safety and tolerability of intravitreal injections of E10030. Phase II clinical trial of E10030 in combination with ranibizumab showed 62% additional benefit of combination therapy over monotherapy.<sup>75</sup> In Phase III clinical trials, E10030 (1.5 mg/eye) was administered intravitreally in combination with ranibizumab (0.5 mg/eye) for a total of 24 months. The trial started in August 2013 and primary efficacies were noticed on visual acuity at month 12. It is estimated that the results will be published in July 2016 (clinical trial identifier is NCT01089517). Fovista is the trade name of this medicine.<sup>76,77</sup>

#### F. Tyrosine kinase cascade inhibitors

Approximately 2000 protein kinases have been recognized so far and are divided into two classes, the receptor tyrosine kinases (RTK) and the non-receptor or cytoplasmic kinases. They play important roles in diverse cellular activities including growth, differentiation, metabolism, adhesion, motility and death. RTKs

are composed of an extracellular domain, which is able to bind a specific ligand, a transmembrane domain, and an intracellular catalytic domain, which is able to bind and phosphorylate selected substrates. A specific ligand binding to the extracellular region of RTK causes phosphorylation of intracellular proteins that transmit to the nucleus and change gene expression. Approximately 20 different RTK classes have been identified but only the fibroblast growth factor receptor (FGFR) family and vascular endothelial growth factor receptor (VEGFR) family of RTK are the most promising for drug development in the field of AMD treatment. During angiogenesis, VEGF molecule binds to its VEGFR on the epithelial cells surface. These receptors with tyrosine kinase activity trigger signaling pathway leading to angiogenesis. Today, newly created drugs inhibit VEGFR tyrosine kinase activity, thereby impairing the angiogenic process. The following is a list of these drugs:

**Ruboxistaurin (Eli Lilly and Company, Indianapolis, Indiana, USA):** is an orally selective antagonist for protein kinase C beta (PKC beta) which inhibits VEGF receptor phosphorylation and angiogenesis. It is used mainly for treatment of diabetic retinopathy, but also suggested for treatment of wet AMD. Arxxant is another name of this drug.<sup>78</sup>

**Vatalanib (Novartis, East Hanover, New Jersey, USA):** is an orally active, small-molecule tyrosine kinase inhibitor which blocks phosphorylation of all known VEGF and PDGF receptors and inhibits retinal neovascularization. Phase I/II clinical trials evaluated safety and efficacy of oral PTK-787 combined with PDT administered once daily for 3 months. No results have been published yet (clinical trial identifier is NCT00138632). PTK/ZK and PTK787 are the code names of this drug.<sup>79</sup>

**Pazopanib (GlaxoSmithKline, Stevenage, UK):** is a tyrosine kinase inhibitor which blocks phosphorylation of VEGFR and PDGFR and inhibits angiogenesis. Phase I clinical trial successfully demonstrated safety and tolerability of pazopanib eye drops which resulted in significant visual improvement in wet AMD. Phase II trial confirmed that instilled pazopanib 4 times daily did not improve the visual acuity or decrease the central retinal thickness (NCT00612456).<sup>[80]</sup> In 2015, clinical evaluation confirmed that pazopanib eye drops 4 times daily do not have any therapeutic benefit beyond that obtained with ranibizumab alone in wet AMD patients.<sup>81</sup> Phase I clinical trial involving oral pazopanib is under way.<sup>82</sup> Votrient is another name of this drug and GW786034 is its code name.

**TG101095 (TargeGen, San Diego, California, USA):** is a tyrosine kinase inhibitor that specifically targets VEGFR and has only been tested in animal models as an eye drop. Administration of this drug twice daily for 14 days effectively reduced the lesion size in the laser-induced neovascularization in murine model.<sup>83</sup>

**AG013958 (Pfizer, San Diego, California, USA):** is a tyrosine kinase inhibitor injected in the sub-tenon space. A phase II study of AG-013958 in wet AMD patients injected once every 3 months has been completed but the results have not been published yet (clinical trial identifier is NCT00090532).<sup>84</sup>

**TG100801 (TargeGen, San Diego, California, USA):** a multi-targeted kinase inhibitor which inhibits VEGF, PDGF and

FGF receptors in addition to the Src family of kinases (sarcoma proto-oncogenic tyrosine kinases family). This drug can reduce inflammation, edema, and angiogenesis which are the pathological hallmarks of wet AMD. Phase I study suggests that TG100801 applied twice daily for 14 days is well tolerated in humans. A phase II study will also evaluate the safety of TG100801 in wet AMD patients when administered twice a daily for 30 days (clinical trial identifier is NCT00509548).<sup>85</sup> It is an important drug that potentially reduces the requirement for repeated injections into the eye. Another topically applied compound for eye disease, TG100948, is in early development.

**AL39324 (Alcon Research Ltd, Fort Worth, Texas, USA):** a novel, potent ATP-competitive VEGFR/PDGFR inhibitor which has been tested as a treatment for wet AMD. Phase II clinical studies will also evaluate the safety, tolerability of intravitreal injection of AL39324 in comparison with ranibizumab. These studies were completed in 2011 but the results have not been published yet. (Clinical trial identifier is NCT00992563). AL39324 is administered intravitreally in wet AMD patients.<sup>86</sup> Linifanib is another name of this drug.

**Palomid 529 (National Eye Institute, Bethesda, Maryland, USA):** is a dual TORC1/TORC 2 inhibitor for the mammalian target of rapamycin (mTOR) signal transduction pathway involved in angiogenesis and cellular proliferation. Animal studies have demonstrated that palomid 529 reduces proliferation and stabilizes the structure of vessels already formed.<sup>87</sup> A phase I trial assesses the safety and efficacy of subconjunctival injections of palomid 529 in patients with wet AMD who have not responded to anti-VEGF treatment. This study has been completed in September 2012; however, the results have not yet been published (Clinical trial identifier is NCT01271270).

## 2. Anti-inflammatory drugs

AMD is not a classic inflammatory disease but inflammatory cells play a major role in the progression of the disease. During aging of the retina, RPE and photoreceptors suffer oxidative or metabolic stress, leading to microglial activation, subretinal migration and complement activation.<sup>88</sup> These para-inflammatory responses protect the retina from age-related free radicals' mediated damage. These components gradually accumulate in the retina and create drusen, the hallmark of early AMD which contains a variety of inflammatory molecules including vitronectin, amyloid A/P, Factor X, prothrombin, and in some instances, immunoglobulin, HLA-DR, complement C3, C5, C5b-9, CFH, and C-reactive protein (CRP).<sup>89</sup> The inflammatory cells such as macrophages accumulate around drusen and release tumor necrosis factor- $\alpha$  (TNF- $\alpha$ ), IL-1 and IL-2 that promote expressions of intercellular adhesion molecule-1 (ICAM-1) in vascular endothelial cells and RPE cells and increase the number of additional inflammatory cells. On the other hand, macrophages induce proliferation and migration of vascular endothelial cells, accelerating angiogenesis and CNV formation.<sup>90</sup> When ICAM-1 as a ligand for LFA-1 (a receptor found on leukocytes) is activated, leukocytes bind to endothelial cells via ICAM-1/LFA-1 and transmigrate into tissue.<sup>91</sup>

For this reason, anti-inflammatory drugs were commonly used along with anti-angiogenesis drug as adjuvant drugs to treat wet AMD.

**Table 1.** Classification of anti-inflammatory drugs.<sup>92</sup>

Category	Examples	Recommendation
Corticosteroids	Dexamethasone	Used in conjunction with anti-VEGF agents and PDT to increase efficiency of treatment in neovascular AMD, when patients poorly respond or are resistant to anti-VEGF alone.
	Triamcinolone acetonide (TA)	Not recommended for monotherapy of neovascular AMD, can be combined, when patients poorly respond or are resistant to anti-VEGF alone.
NSAIDs	Bromfenac Nepafenac Diclofenac	Can be combined with anti-VEGF agents in neovascular AMD, more clinical studies are warranted.
	Aspirin (low dose)	Can be used as long-term anti-inflammatory treatment, potential preventative power against AMD development.
Immunosuppressant	Methotrexate	Alternative treatments for neovascular AMD patients who are resistant to anti-VEGF therapy, more clinical studies are warranted.
	Rapamycin	Used in neovascular AMD patients and evaluated in clinical trials for non-neovascular and vascular AMD, more clinical studies are warranted.
Anti-TNF- $\alpha$ agents	Infliximab Adalimumab	May be used in anti-VEGF resistant patients; more clinical studies are warranted.
IL-2 receptor antagonist	Daclizumab	Used in conjunction with anti-VEGF agents to decrease anti-VEGF treatment in neovascular AMD, more clinical studies are warranted.

These drugs are divided into several groups (Table 1):

#### A. Corticosteroids:

These drugs inhibit migration and activation of inflammatory cells, downregulate cytokines expression, reduce permeability of retinal endothelial cells and VEGF expression and thus prevent the development of AMD.<sup>93</sup> These drugs include the following:

**Triamcinolone acetonide (Bristol-Myers Squibb, New York, New York, USA):** A synthetic water-soluble corticosteroid which inhibits leukocytes that release angiogenic factors and downregulates inflammation. This drug was used as monotherapy or in combination with other drugs for treating wet AMD.<sup>94</sup> Anti-VEGF monotherapy has many limitations due to the need for repetitive treatments, increased costs and tachyphylaxis. Treatments involving TA in combination therapy with anti-VEGF and PDT can provide substantial long-term benefits. It is injected in the vitreous or the subtenon space. Triamcinolone acetonide can remain active in ocular tissue for many months after a single intravitreal injection.<sup>95</sup> A phase II study included intravitreal injections of ranibizumab (0.5mg/0.05 mL) injected monthly for 6 months along with sub-tenon injection of triamcinolone acetonide (40mg/mL) every two months, for a total of 6 months. The hypothesis was that treatment with both ranibizumab and triamcinolone acetonide will allow even greater vision improvements than ranibizumab treatment alone but the results have not been published yet. (Clinical trial identifier is NCT01249937). In 2005, Ahmadi *et al.* started phase III clinical trial of intravitreal injection of bevacizumab plus triamcinolone acetonide versus bevacizumab only. They demonstrated that combination therapy increased the therapeutic efficacy in the early post-injection period and resulted in fewer requirements for repeat bevacizumab injections. (Clinical trial identifier is NCT00370370).<sup>96</sup> Another research by this group demonstrated that triple therapy consisting of single-session photodynamic therapy combined with bevacizumab and intravitreal triamcinolone improves vision and reduces central macular thickness (CMT) in wet AMD.<sup>97</sup> Kenalog is another name of this drug.

**Dexamethasone (Bay Area Retina Associates, Walnut Creek, California, USA):** is a potent synthetic glucocorticoid which has anti-inflammatory effects. This medication is usually administered combined with radiation therapy and bevacizumab. The application of these three factors together, named triple therapy, results in significant visual improvement in most wet AMD patients with CNV. This drug is used for injection into the vitreous.<sup>98</sup> A phase II study (Lucedex) included combination therapy with 0.05 cc dose intravitreal dexamethasone injection (10mg/ml vial) and a single 0.5 mg intravitreal ranibizumab injection versus 0.5 mg intravitreal injection of ranibizumab. The purpose of this research was to evaluate the safety of intravitreal ranibizumab in combination with intravitreal dexamethasone in comparison to intravitreal ranibizumab alone in treating wet AMD. This clinical trial confirmed a benefit of adjoining intravitreal dexamethasone to treatment of wet AMD with intravitreal ranibizumab (NCT00793923).<sup>99,100</sup>

#### B. Nonsteroidal anti-inflammatory drugs:

These drugs have heterogeneous chemical structures which are used as anti-inflammatory agent with great influence for treating wet AMD. NSAIDs act by blocking the cyclooxygenase enzymes, COX-1 and COX-2. The COX-2 enzyme mediates the production of prostaglandins that contribute to the inflammatory response and ocular disease.<sup>101</sup> The following is a list of these drugs:

**Bromfenac (ISTA Pharmaceuticals, Irvine, California, USA):** A non-steroidal anti-inflammatory drug which inhibits prostaglandin production.<sup>102</sup> In a phase II clinical trial, ranibizumab was injected each month for 4 months, then if needed for 8 months, plus bromfenac eye drop twice per day, each day, for 12 months versus ranibizumab injection alone. This trial was completed in September 2010 but the results have not been published yet (Clinical trial identifier NCT00805233). In July 2014, Wyględowska-Promieńska *et al.* demonstrated that the combined therapy of bevacizumab and bromfenac improved visual acuity compared to the control group.<sup>103</sup> This combined therapy reduces



the number of intravitreal injections of bevacizumab.<sup>103</sup> Prolensa, Bromday and Xibrom are other names of this drug.

**Nepafenac (Alcon Research Ltd, Fort Worth, Texas, USA):**

A nonsteroidal anti-inflammatory drug which reduces pain and inflammation. This drug is usually used once daily as an eye drop to reduce inflammation in cataract. Few clinical studies are performed for this drug as a treatment for wet AMD. In 2010, researcher added topical nepafenac to monthly anti-VEGF injections in wet AMD patients and demonstrated that no significant change was observed in visual acuity, but detectable improvement appeared in eye anatomy.<sup>104</sup> Nevanac is the brand name of this drug.<sup>105</sup>

**Diclofenac (Novartis Pharmaceuticals UK Ltd, Camberley, UK):**

Diclofenac is a nonsteroidal anti-inflammatory drug (NSAID) which reduces pain and inflammation. A phase II clinical trial study demonstrated that the use of diclofenac, 2–4 days before and until 2 weeks after verteporfin treatment showed no significant differences in improvement when compared to verteporfin monotherapy.<sup>106</sup> It is supplied in medications under a variety of trade names such as Aclonac, Cataflam, Voltaren.

**Ketorolac (Syntex Corporation, Palo Alto, California, USA):**

is another nonsteroidal anti-inflammatory drug used for treating wet AMD.<sup>107</sup> A phase IV clinical trial started in December 2012, designed to determine the effectiveness of ranibizumab with and without ketorolac eye drop for treating wet AMD. This trial was completed in January 2014 and confirmed the efficacy and safety of a combination of ketorolac eye drops and intravitreal ranibizumab injections in wet AMD patients. It is demonstrated that topical ketorolac supplements and intravitreal ranibizumab decreased CMT in CNV (NCT02060604).<sup>108</sup> In 2015, researcher confirmed that the combination of ketorolac eye drops and ranibizumab provided superior best-corrected visual acuity and central retinal thickness outcomes compared with ranibizumab monotherapy or ranibizumab plus loading-phase reduced-fluence verteporfin in wet AMD patients.<sup>109</sup> Toradol, Acular and Sprix are the trade names of this drug.

**C. Immunosuppressants:**

These drugs were used as adjuvant treatment with anti VEGF drugs for wet AMD. They have several mechanisms as anti-inflammatory agents, such as inhibition of B and T lymphocytes proliferation by reducing synthesis of purine and pyrimidine, inhibition of macrophage and lymphocyte function by reducing intracellular glutathione concentrations and reducing proliferation and activation of T and B lymphocytes by inhibiting mTOR function.<sup>89</sup>

**Methotrexate:** dicarboxylic acids as anti-inflammatory drugs are used as adjunct drugs for treating wet AMD. This drug inhibits the immune system with inhibition of T cell activation, suppression of intercellular adhesion molecule expression by T cells, downregulation of B cells and increasing CD95 sensitivity of activated T cells. The drug is injected intravitreally with VEGF inhibitor drugs for patients who have become resistant to them. More clinical studies are necessary to improve the efficiency of this drug. It was formerly known as Amethopterin.<sup>110</sup> Trexall, Rheumatrex and Dose Pack are trade names of this drug.

**Sirolimus (Macusight/Santen, Union City, California, USA):**

A polyketide (secondary metabolites produced by all living organisms) which inhibits the mammalian target of rapamycin (mTOR). mTOR is a protein kinase activated by growth factors which causes uncontrolled proliferation of blood vessels. It stimulates inflammatory response by activation of T and B cells.<sup>111,112</sup> This drug is administered via subconjunctival or intravitreal injections. A phase II clinical trial started in October 2008 to assess the safety and efficacy of Lucentis plus Sirolimus versus Lucentis. This trial has been completed but the results have not been published yet (Clinical trial identifier is NCT00766337). Rapamycin is the trade name of this medicine.

**D. IL-2 receptor antagonist:**

The high-affinity IL-2R is only expressed in activated T cells and is required for viability of T cells. Blockage of IL-2R decreases activation and proliferation of T-cells. This drug has become a promising adjunctive therapy in wet AMD for patients who do not respond to the anti-VEGF drugs.

**Daclizumab (Hoffmann-La Roche Ltd, Basel, Switzerland):**

A therapeutic humanized monoclonal antibody directed against the  $\alpha$ -chain of the IL-2 receptor.<sup>113</sup> A phase II clinical trial demonstrated that intravitreal injection of this drug as an adjuvant with bevacizumab or ranibizumab reduces the need for anti-VEGF injections for treating wet AMD.<sup>114</sup> Studies demonstrated that daclizumab is well tolerated and has no serious adverse effects following intravenous and subcutaneous injections. Zenapax is its trade name.

**E. TNF- $\alpha$  inhibitor drug:**

TNF- $\alpha$  is now recognized as a key regulator of inflammatory responses. It causes cell death, fever and inflammation, affected by domestic or internal infectious agents. Two kinds of anti-TNF- $\alpha$  agents are currently being evaluated for treatment of wet AMD.

**Efalizumab (Genentech, San Francisco, California, USA and Merck-Serono, Geneva, Switzerland):**

A chimeric immunoglobulin IgG1 monoclonal antibody composed of a constant human Fc region and a variable mouse Fab region with anti-inflammatory function. Efalizumab inhibits binding of LFA-1 to ICAM-1, thereby inhibiting the adhesion of leukocytes to other cells. On the other hand, it acts as TNF- $\alpha$  inhibitor implicated for treating wet AMD. A phase III clinical trial demonstrated that combination therapy of weekly subcutaneous injection of efalizumab as an iCAM-1 inhibitor and intravitreal injections of ranibizumab as an anti-VEGF agent improved wet AMD treatment. Raptiva is another name of this drug.<sup>115</sup>

**Adalimumab (ABBOTT Laboratories, Illinois, USA):**

A fully humanized recombinant anti-TNF- $\alpha$  IgG1 monoclonal antibody which has a performance similar to efalizumab. This drug plays an anti-inflammatory role through inhibition of TNF- $\alpha$ . A phase II clinical trial demonstrated safety and efficacy of intravitreal adalimumab administered to wet AMD patients who are non-responders to ranibizumab (NCT01136252).<sup>89</sup> In 2012, clinical reports confirmed that intravitreal infliximab and adalimumab do not appear to benefit eyes with CNV that

responded to ranibizumab.<sup>116</sup> In 2016, researchers reported a case of a patient with wet AMD refractory to ranibizumab therapy, who clinically benefited from subcutaneous adalimumab therapy. Treatment with subcutaneous adalimumab in combination with ranibizumab avoids the high risks of multiple intravitreal anti-VEGF injections.<sup>117</sup> Adalimumab has a lower risk of adverse effects than infliximab because it is a fully humanized antibody. Humira is its trade name.

#### F. Complement component inhibitors

The complement system consists of more than 40 proteins and regulators that play a key role in defense against pathogens.<sup>118</sup> The retina, RPE and photoreceptors suffer oxidative or metabolic stress with aging, resulting in microglial activation, subretinal migration and complement activation. These components gradually accumulate in the retina and give rise to drusen, adjacent to the basal surface of RPE in AMD patients. The inflammatory cells such as macrophages accumulated around drusen induce proliferation and migration of vascular endothelial cells and accelerate angiogenesis and CNV formation. Drusen as the hallmark of early AMD contains complement components (C3a, C5a, C5, C5b-9), terminal complement complex (TCC) (C5b connecting C6, C7, C8 and C9 factors), complement regulatory proteins (CFH and CFB) and factors (E and D).<sup>118-120</sup> A series of complement inhibitors have been used to prevent complement components accumulation in drusen, for treatment of wet AMD treatment.

**POT-4 (Potentia Pharmaceuticals Inc, Louisville, Kentucky, USA):** A cyclic peptide comprised of 13 amino acids, derived from compstatin. POT-4 binds reversibly to complement component 3 (C3) and prevents its activation.<sup>120</sup> A phase I clinical trial started in 2007 to assess safety, stability and tolerability of intravitreal injection of POT-4 for treating wet AMD. This trial was completed on March 16, 2010 but the results have not been published yet (Clinical trial identifier is NCT00473928). Some reports indicate that phase I clinical trial demonstrated safety and tolerability of the drug at all doses tested; no adverse events and no identifiable intraocular inflammation were reported. Blood test demonstrated that the drug stays in the body for 3-6 months. This result supports the implementation of Phase II clinical trial program to further define the safety, efficacy and pharmacokinetic profile of POT-4 as a treatment for wet AMD.

**ARC1905 (Ophthotech Corp, Princeton, New Jersey, USA):** This pegylated, nuclease-stabilized aptamer acts as a C5 inhibitor of the complement cascade. ARC1905 inhibits the activation of the membrane attack complex MAC by blocking the cleavage of C5.<sup>121</sup> A phase I clinical trial assessed the safety and tolerability of intravitreal injection of ARC1905 in combination with ranibizumab (0.5 mg) as an anti-VEGF drug for treatment of wet AMD. This trial was completed in March 2011 but the results have not been published yet (Clinical trial identifier is NCT00709527). The drug can improve vision and prevent progression of the disease. Zimura is another name of this drug.

**TNX-234 (Genentech, San Francisco, California, USA):** A humanized monoclonal antibody directed against factor D. A preclinical study of this drug was performed for treatment of wet AMD.<sup>120</sup> Tanox is another name of this drug.

**C1-INH (Viropharma, Hampshire, UK and CSL Behring, Marburg, Germany)** as a C1 esterase inhibitor and **recombinant CFH (Taligen Therapeutics, Cambridge, Massachusetts, USA and Ophtherion, New Haven, USA)** as CFH supplementation, are other complement component inhibitors. A preclinical study of these two drugs was performed for treatment of wet AMD.<sup>120</sup>

**Summary:** The prevalence of AMD as the main cause of low vision in elderly is increasing; therefore, the scientific community mainly centers on how it can be prevented and treated.

AMD is a multifactorial disease influenced by complex genetic and environmental risk factors. Different treatment strategies have been attempted for AMD. Laser based treatments such as thermal laser photocoagulation, transpupillary thermotherapy and photodynamic therapy halt the AMD progression but improved vision cannot be expected. Pharmacotherapy revolutionized the management of wet type AMD resulting in improved structural and visual outcomes in these patients. Some of these drugs have received FDA approval and others are under investigation. Cell therapies use different cell sources such as RPE for regeneration of damaged cells; these researches are currently in clinical trial phases.

This review aimed to provide an overview on pharmacotherapy of wet AMD. Inflammation and angiogenesis play critical roles in AMD; therefore, the medications used to treat this disease focus on the control of these two processes.

During the angiogenesis process, VEGF binds to VEGF receptor and triggers tyrosine kinase signaling pathway that leads to angiogenesis. This process can be controlled with VEGF, VEGFR, VEGF expression, VEGFR expression, and tyrosine kinase cascade inhibitors. Most currently available pharmacotherapeutic agents used for treatment of wet AMD block the biological effects of VEGF such as the RNA aptamer pegaptanib, partial and full-length antibodies ranibizumab and bevacizumab, the VEGF trap aflibercept, DARPIn, KH902 and NT-503, the small aminosterol squalamine and the recombinant sFLT01 protein or adeno-associated virus AAV2-sFLT01. Some of these drugs block the biological activity of VEGFRs such as a chimeric monoclonal antibody volociximab, the recombinant PEDF adenovirus AdPEDF and the synthetic AtuRNAi PF-4523655. VEGF expression inhibitor drugs include synthetic siRNAs bevasiranib, PF-4523655 and CAND5 and an angiostatic cortisone anecortave. The siRNA-based drugs such as Sirna-027 were used for inhibiting VEGFR expression. The tyrosine kinase inhibitors include ruboxistaurin, vatalanib, pazopanib, TG100801, TG101095, AG013958, AL39324 and palomid 529. Among these drugs, VEGF inhibitors such as bevacizumab, ranibizumab and aflibercept are commercially available drugs for treating wet AMD while the other drugs are in clinical trials. Most of the VEGF inhibitors must be injected directly into the vitreous and the injections should be repeated at variable intervals from 15 days to 8 week, depending on the type and half-life of the medication. However, some of the drugs are used via other routes such as NT-503 which is implanted in the vitreous as encapsulated cells, squalamine is an eye drop and anecortave is injected into the juxtasclear space with a curved needle. AMD is not a classic inflammatory disease but inflammatory cells play a major role in the progression of the disease. For this reason, anti-inflammatory drugs were commonly used along with anti-angiogenesis drugs as adjuvant drugs to treat wet AMD.

During aging of the retina, RPE and photoreceptors suffer oxidative stress, which leads to complement activation. These components are gradually accumulated in retina and create drusen, the hallmark of early AMD. The inflammatory cells such as macrophages accumulate around drusen and release TNF- $\alpha$  (Tumor necrosis factor- $\alpha$ ), IL-1 and IL-2 which promote expression of intercellular adhesion molecule ICAM-1 in vascular epithelial and RPE cells and increase the number of other inflammatory cells. On the other hand, macrophages induce proliferation and migration of vascular endothelial cells, accelerating angiogenesis and CNV formation.

There are many anti-inflammatory drugs currently under investigation in clinical trials for treating wet AMD, such as corticosteroids including triamcinolone acetonide and dexamethasone; nonsteroidal anti-inflammatory drugs like bromfenac, nepafenac, diclofenac and ketorolac; immunosuppressants methotrexate and sirolimus, IL-2 receptor antagonist daclizumab, TNF- $\alpha$  inhibitor drugs including efalizumab and adalimumab; complement component inhibitors POT-4, ARC1905, TNX-234, C1-INH and recombinant CFH. Triamcinolone acetonide is commonly used as an anti-inflammatory drug in combination with ranibizumab or bevacizumab for treating wet AMD.

We hope to have provided a better understanding of different aspects of wet AMD pharmacotherapy as well as knowledge for safer and more effective treatment strategies for the affected patients.

## Acknowledgments

*We wish to acknowledge Meisam Lesani and Maliheh Davari for their contribution to completing this work.*

## Reference

- Tay HW. Symmetrical central choroidoretinal disease occurring in senile persons. *R. Lond Ophthal Hosp Rep.* 1875; 8: 231 – 244.
- Leibowitz H, Krueger D, Maunder L, Milton R, Kini M, Kahn H, et al. The Framingham Eye Study monograph: An ophthalmological and epidemiological study of cataract, glaucoma, diabetic retinopathy, macular degeneration, and visual acuity in a general population of 2631 adults, 1973-1975. *Surv Ophthalmol.* 1980; 24(Suppl): 335 – 610.
- Liu K, Xie B. Today and Future of Age-Related Macular Degeneration. *International Scholarly Research Notices* 2012; 2012: 9. Available from: URL: <http://dx.doi.org/10.5402/2012/480212>.
- Porte C. Pathogenesis and Management of Age-Related Macular Degeneration. *SUMJ.* 2012; 1(2).
- Chopdar A, Chakravarthy U, Verma D. Age related macular degeneration. *BMJ.* 2003; 326(7387): 485 – 488.
- Athanasakis K, Fragoulakis V, Tsiantou V, Masaoutis P, Maniadakis N, Kyriopoulos J. Cost-Effectiveness Analysis of Ranibizumab versus Verteporfin Photodynamic Therapy, Pegaptanib Sodium, and Best Supportive Care for the Treatment of Age-Related Macular Degeneration in Greece. *Clin Ther.* 2012; 34(2): 446 – 456.
- Stein JD, Brown MM, Brown GC, Hollands H, Sharma S. Quality of life with macular degeneration: perceptions of patients, clinicians, and community members. *Br J Ophthalmol.* 2003; 87(1): 8 – 12.
- Aydin Kurma S, Altun A, Gencaga T, Akkaya S, Sengor T. Vision Related Quality of Life in Patients with Keratoconus. *J Ophthalmol.* 2014; 2014: 694542.
- Rovner BW, Casten RJ, Tasman WS. Effect of depression on vision function in age-related macular degeneration. *Arch Ophthalmol.* 2002; 120(8): 1041 – 1044.
- Carpentier S, Knaus M, Suh M. Associations between lutein, zeaxanthin, and age-related macular degeneration: an overview. *Crit Rev Food Sci Nutr.* 2009; 49(4): 313 – 326.
- Adler FH, Kaufman PL, Levin LA, Alm A. *Adler's Physiology of the Eye.* Elsevier Health Sciences; 2011.
- Green WR, Enger C. Age-related macular degeneration histopathologic studies: the 1992 Lorenz E. Zimmerman Lecture. *Retina.* 2005; 25(5): 1519 – 1535.
- de Jong PTVM. Age-Related Macular Degeneration. *N Engl J Med.* 2006; 355(14): 1474 – 1485.
- Lopez PF, Sippy BD, Lambert HM, Thach AB, Hinton DR. Transdifferentiated retinal pigment epithelial cells are immunoreactive for vascular endothelial growth factor in surgically excised age-related macular degeneration-related choroidal neovascular membranes. *Invest. Ophthalmol. Vis. Sci.* 1996; 37(5): 855 – 868.
- Sarks J, Tang K, Killingsworth M, Arnold J, Sarks S. Development of atrophy of the retinal pigment epithelium around disciform scars. *Br J Ophthalmol.* 2006; 90(4): 442 – 446.
- Coleman HR, Chan CC, Ferris IF, Chew EY. Age-related macular degeneration. *Lancet.* 2008; 372: 1835 – 1845.
- VanNewkirk MR, Nanjan MB, Wang JJ, Mitchell P, Taylor HR, McCarty CA. The prevalence of age-related maculopathy: The visual impairment project. *Ophthalmology.* 2000; 107(8): 1593 – 1600.
- Bressler SB, Munoz B, Solomon SD, West SK. Racial differences in the prevalence of age-related macular degeneration: the Salisbury Eye Evaluation (SEE) Project. *Arch Ophthalmol.* 2008; 126(2): 241 – 245.
- Mitchell P, Wang J, Smith W, Leeder SR. Smoking and the 5-year incidence of age-related maculopathy: The blue mountains eye study. *Arch Ophthalmol.* 2002; 120(10): 1357 – 1363.
- Tsoumakidou M, Demedts IK, Brusselle GG, Jeffery PK. Dendritic Cells in Chronic Obstructive Pulmonary Disease. *Am J Respir Crit Care Med.* 2008; 177(11): 1180 – 1186.
- Nano ME, Lansingh VC, Pighin MS, Zarate N, Nano H, Carter MJ, et al. Risk factors of age-related macular degeneration in Argentina. *Arq Bras Oftalmol.* 2013; 76: 80 – 84.
- Mares JA, Moeller SM. Diet and age-related macular degeneration: expanding our view. *Am J Clin Nutr.* 2006; 83(4): 733 – 734.
- Johnson EJ. Age-related macular degeneration and antioxidant vitamins: recent findings. *Curr Opin Clin Nutr Metab Care.* 2010; 13(1): 28 – 33.
- Evans JR. Antioxidant vitamin and mineral supplements for slowing the progression of age-related macular degeneration. *Cochrane Database Syst Rev.* 2006; (2): CD000254.
- Age-Related EDS. Lutein+ zeaxanthin and omega-3 fatty acids for age-related macular degeneration: the Age-Related Eye Disease Study 2 (AREDS2) randomized clinical trial. *JAMA.* 2013; 309(19): 2005.
- Seddon JM, Rosner B, Sperduto RD, Yanzuzzi L, Haller JA, Blair NP, Willett, et al. Dietary fat and risk for advanced age-related macular degeneration. *Arch Ophthalmol.* 2001; 119(8): 1191 – 1199.
- Sweeney K. Angiogenesis inhibitors: an upcoming therapy for cancer and wet age-related macular degeneration. *Drug Discov Today.* 2005; 10(20): 1346 – 1348.
- Liu E, Morimoto M, Kitajima S, Koike T, Yu Y, Shiiki H, et al. Increased Expression of Vascular Endothelial Growth Factor in Kidney Leads to Progressive Impairment of Glomerular Functions. *J. Am. Soc. Nephrol.* 2007; 18(7): 2094 – 2104.
- Hannink M, Donoghue DJ. Structure and function of platelet-derived growth factor (PDGF) and related proteins. *Biochim. Biophys. Acta.* 1989; 989(1): 1 – 10.
- Shukla D, Namperumalsamy P, Goldbaum M, Cunningham Jr ET. Pegaptanib sodium for ocular vascular disease. *Indian J. Ophthalmol.* 2007; 55(6): 427.
- Ferrara N, Hillan KJ, Gerber HP, Novotny W. Discovery and development of bevacizumab, an anti-VEGF antibody for treating cancer. *Nat Rev Drug Discov.* 2004; 3(5): 391 – 400.
- Tolentino MJ, Husain D, Theodosiadis P, et al. Angiography of fluoresceinated anti-vascular endothelial growth factor antibody and dextrans in experimental choroidal neovascularization. *Arch. Ophthalmol.* 2000; 118(1): 78 – 84.
- Rosenfeld PJ, Moshfeghi AA, Puliafito CA. Optical coherence tomography findings after an intravitreal injection of bevacizumab (Avastin) for neovascular age-related macular degeneration. *Ophthalmic Surg Lasers Imaging.* 2004; 36(4): 331 – 335.
- Kodjikian L, Decullier E, Souied E, Girmens JF, Durand E, Chapuis F, et al. Bevacizumab and ranibizumab for neovascular age-related macular degeneration: an updated meta-analysis of randomised clinical trials. *Ger J Ophthalmol.* 2014; 252(10): 1529 – 1537.
- Ahfat FG, Zaidi FH. Bevacizumab vs ranibizumab [mdash] an appraisal of the evidence from CATT and IVAN. *Eye.* 2013; 27(3): 289 – 290.
- Bashshur ZF, Haddad ZA, Schakal A, Jaafar RF, Saab M, Nouredin BN. Intravitreal bevacizumab for treatment of neovascular age-

- related macular degeneration: a one-year prospective study. *Am J Ophthalmol.* 2008; 145(2): 249 – 256. e242.
37. Samiei S BA, soheili ZS, Ahmadi H, Alipour SD, Rezaei M, Dizaji A. he Effect of Bevacizumab on MMP-9 Production and Activity in Human Retinal pigment Epithelial Cell Culture. 11th Euretina Congress; 2011.
  38. Ferrara N, Damico L, Shams N, Lowman H, Kim R. Development of ranibizumab, an anti-vascular endothelial growth factor antigen binding fragment, as therapy for neovascular age-related macular degeneration. *Retina.* 2006; 26(8): 859 – 870.
  39. Chang TS, Kokame G, Casey R, Prenner J, Feiner L, Anderson N. Short-term effectiveness of intravitreal bevacizumab versus ranibizumab injections for patients with neovascular age-related macular degeneration. *Retina.* 2009; 29(9): 1235 – 1241.
  40. Klettner A, Kruse ML, Meyer T, Wesch D, Kabelitz D, Roeder J. Different properties of VEGF-antagonists: Bevacizumab but not Ranibizumab accumulates in RPE cells. *Graefes Arch Clin Exp Ophthalmol.* 2009; 247(12): 1601 – 1608.
  41. Zou L, Lai H, Zhou Q, Xiao F. Lasting Controversy on Ranibizumab and Bevacizumab. *Theranostics.* 2011; 1: 395 – 402.
  42. Magdelaine-Beuzelin C, Pinaut C, Pintaud G, Watier H. Therapeutic antibodies in ophthalmology: Old is new again. *mAbs.* 2010; 2(2): 176 – 180.
  43. Rosenfeld PJ, Brown DM, Heier JS, Boyer DS, Kaiser PK, Chung CY, et al. Ranibizumab for neovascular age-related macular degeneration. *N Engl J Med.* 2006; 355(14): 1419 – 1431.
  44. Machalińska A, Paczkowska E, Pabin T, Safranow K, Karczewicz D, Machaliński B. Influence of ranibizumab on vascular endothelial growth factor plasma level and endothelial progenitor cell mobilization in age-related macular degeneration patients: safety of intravitreal treatment for vascular homeostasis. *J Ocul Pharmacol Ther.* 2011; 27(5): 471 – 475.
  45. Akrami H, Soheili Z-S, Sadeghizadeh M, Ahmadi H, Rezaeianavi M, Samiei S, et al. PlGF gene knockdown in human retinal pigment epithelial cells. *Graefes Arch Clin Exp Ophthalmol.* 2011; 249(4): 537 – 546.
  46. Heier JS, Brown DM, Chong V, Korobelnik J-F, Kaiser PK, Nguyen QD, et al. Intravitreal Aflibercept (VEGF Trap-Eye) in Wet Age-related Macular Degeneration. *Ophthalmology.* 2012; 119(12): 2537 – 2548.
  47. Griffin DR, Richmond PP, Olson JC. Intravitreal Aflibercept Outcomes in Patients with Persistent Macular Exudate Previously Treated with Bevacizumab and/or Ranibizumab for Neovascular Age-Related Macular Degeneration. *J Ophthalmol.* 2014; 2014: 6.
  48. Heier JS, Brown DM, Chong V, Korobelnik JF, Kaiser PK, Nguyen QD, et al. Intravitreal aflibercept (VEGF trap-eye) in wet age-related macular degeneration. *Ophthalmology.* 2012; 119(12): 2537 – 2548.
  49. Binz HK, Stumpp MT, Forrer P, Amstutz P, Plückthun A. Designing Repeat Proteins: Well-expressed, Soluble and Stable Proteins from Combinatorial Libraries of Consensus Ankyrin Repeat Proteins. *J Mol Biol.* 2003; 332(2): 489 – 503.
  50. Wetzel SK, Ewald C, Settanni G, Jurt S, Plückthun A, Zerbe O. Residue-Resolved Stability of Full-Consensus Ankyrin Repeat Proteins Probed by NMR. *J Mol Biol.* 2010; 402(1): 241 – 258.
  51. Stahl A, Stumpp MT, Schlegel A, Ekawardhani S, Lehrling C, Martin G, et al. Highly potent VEGF-A-antagonistic DARPins as anti-angiogenic agents for topical and intravitreal applications. *Angiogenesis.* 2013; 16(1): 101 – 111.
  52. Souied EH, Devin F, Mauguet-Fayssse M, Kolář P, Wolf-Schnurrbusch U, Framme C, et al. Treatment of Exudative Age-Related Macular Degeneration with a Designed Ankyrin Repeat Protein that Binds Vascular Endothelial Growth Factor: a Phase I/II Study. *Am J Ophthalmol.* 2014; 158(4): 724 – 732.e722.
  53. Rivera M LA, Bouchard B, Stiles M, Ling V. Pharmacokinetics of a VEGF Antagonist Delivered by an Intraocular Encapsulated Cell Technology Implant. ARVO Meeting Abstracts 2012.
  54. A DM. New Clinical Trial: Squalamine Eye Drops for Wet AMD and Retinal Vein Occlusion. *Vision aware* 2013.
  55. Connolly B, Desai A, Garcia CA, Thomas E, Gast MJ. Squalamine lactate for exudative age-related macular degeneration. *Ophthalmol Clin North Am.* 2006; 19(3): 381 – 391.
  56. Pecun PE, Kaiser PK. Current phase 1/2 research for neovascular age-related macular degeneration. *Curr Opin Ophthalmol.* 2015; 26(3): 188 – 193.
  57. Chen X, Li J, Li M, Zeng M, Li T, Xiao W, et al. KH902 suppresses high glucose-induced migration and sprouting of human retinal endothelial cells by blocking VEGF and PlGF. *Diabetes Obes Metab.* 2013; 15(3): 224 – 233.
  58. Zhang M, Zhang J, Yan M, Luo D, Zhu W, Kaiser PK, et al. A Phase I Study of KH902, a Vascular Endothelial Growth Factor Receptor Decoy, for Exudative Age-Related Macular Degeneration. *Ophthalmology.* 2011; 118(4): 672 – 678.
  59. Li X, Xu G, Wang Y, Xu X, Liu X, Tang S, et al. Safety and Efficacy of Conbercept in Neovascular Age-Related Macular Degeneration. *Ophthalmology.* 2012(9): 1740 – 1747.
  60. Ramakrishnan V, Bhaskar V, Law DA, Wong M, DuBridges RB, Breinberg D, et al. Preclinical evaluation of an anti- $\alpha$ 5 $\beta$ 1 integrin antibody as a novel anti-angiogenic agent. *J Exp Ther Oncol.* 2005; 5(4): 273 – 286.
  61. Carrion M, Hamilton M, Harris B, King C, Mori K, Wei L. Ocular Pharmacokinetics of Pigment Epithelium-Derived Factor (PEDF) Following Adenovector-Based Gene Delivery Indicate That Low Doses of PEDF Are Therapeutic. In: ARVO Annual Meeting; 2005: 1 – 5.
  62. Hamilton MM, Byrnes GA, Gall JG, Brough DE, King CR, Wei LL. Alternate serotype adenovector provides long-term therapeutic gene expression in the eye. *Mol Vis.* 2008; 14: 2535.
  63. Tolentino MJ, Brucker AJ, Fosnot J, Ying GS, Wu IH, Malik G, et al. Intravitreal injection of vascular endothelial growth factor small interfering RNA inhibits growth and leakage in a nonhuman primate, laser-induced model of choroidal neovascularization. *Retina.* 2004; 24(1): 132 – 138.
  64. Elbashir SM, Harborth J, Lendeckel W, Yalcin A, Weber K, Tuschl T. Duplexes of 21-nucleotide RNAs mediate RNA interference in cultured mammalian cells. *Nature.* 2001; 411(6836): 494 – 498.
  65. Abouammoh M, Sharma S. Ranibizumab versus bevacizumab for the treatment of neovascular age-related macular degeneration. *Curr Opin Ophthalmol.* 2011; 22(3): 152 – 158.
  66. Perkel J. RNAi Therapeutics: A Two-Year Update. *Science.* 2009; 326(5951): 454.
  67. Garba AO, Mousa SA. Bevasiranib for the Treatment of Wet, Age-Related Macular Degeneration. *Ophthalmol Eye Dis.* 2010; 2: 75 – 83.
  68. Nguyen QD, Schachar RA, Nduaka CI, Sperling M, Klamerus KJ, Chi-Burris K, et al. Evaluation of the siRNA PF-04523655 versus ranibizumab for the treatment of neovascular age-related macular degeneration (MONET Study). *Ophthalmology.* 2012; 119(9): 1867 – 1873.
  69. Geltzer A, Turalba A, Vedula SS. Surgical implantation of steroids with antiangiogenic characteristics for treating neovascular age-related macular degeneration. *Cochrane Database Syst Rev.* 2007; (4): CD005022.
  70. Slakter JS, Bochow T, D'Amico DJ, Marks B, Jerdan J, Sullivan EK. Anecortave Acetate (15 Milligrams) versus Photodynamic Therapy for Treatment of Subfoveal Neovascularization in Age-Related Macular Degeneration. *Ophthalmology.* 2006; 113(1): 3 – 13.
  71. Augustin A. Anecortave acetate in the treatment of age-related macular degeneration. *Clin Interv Aging.* 2006; 1(3): 237 – 246.
  72. HO AC. Anecortave acetate: treatment for age-related macular degeneration. *Drugs Future.* 2002; 27(11): 1039 – 1048.
  73. Kaiser PK, Symons R, Shah SM, Quinlan EJ, Tabandeh H, Do DV, et al. RNAi-based treatment for neovascular age-related macular degeneration by Sima-027. *Am J Ophthalmol.* 2010; 150(1): 33 – 39. e32.
  74. Kudelka MR, Grossniklaus HE, Mandell KJ. Emergence of dual VEGF and PDGF antagonists in the treatment of exudative age-related macular degeneration. *Expert Rev Ophthalmol.* 2013; 8(5): 475 – 484.
  75. Tolentino MJ, Dennrick A, John E, Tolentino MS. Drugs in Phase II clinical trials for the treatment of age-related macular degeneration. *Expert Opin Investig Drugs.* 2015; 24(2): 183 – 199.
  76. Jo N, Mailhos C, Ju M, Cheung E, Bradley J, Nishijima K, et al. Inhibition of platelet-derived growth factor B signaling enhances the efficacy of anti-vascular endothelial growth factor therapy in multiple models of ocular neovascularization. *Am J Pathol.* 2006; 168(6): 2036 – 2053.
  77. Ishikawa M, Jin D, Sawada Y, Abe S, Yoshitomi T. Future Therapies of Wet Age-Related Macular Degeneration. *Am J Ophthalmol.* 2015; 20159. Available from: URL: <http://dx.doi.org/10.1155/2015/138070>.
  78. Kumar B, Gupta S, Saxena R, Srivastava S. Current trends in the pharmacotherapy of diabetic retinopathy. *J Postgrad Med.* 2012; 58(2): 132.
  79. Jost LM, Gschwind HP, Jalava T, Wang Y, Guenther C, Souppart C, et al. Metabolism and disposition of vatalanib (PTK787/ZK-222584)

- in cancer patients. *Drug Metab Dispos.* 2006; 34(11): 1817 – 1828.
80. Singh R, Wurzelmann JI, Ye L, Henderson L, Hossain M, Trivedi T, et al. Clinical evaluation of pazopanib eye drops in healthy subjects and in subjects with neovascular age-related macular degeneration. *Retina.* 2014; 34(9): 1787 – 1795.
  81. Csaky KG, Dugel PU, Pierce AJ, Fries MA, Kelly DS, Danis RP, et al. Clinical evaluation of pazopanib eye drops versus ranibizumab intravitreal injections in subjects with neovascular age-related macular degeneration. *Ophthalmology.* 2015; 122(3): 579 – 588.
  82. Danis R, McLaughlin MM, Tolentino M, Staurengi G, Ye L, Xu CF, et al. Pazopanib eye drops: a randomised trial in neovascular age-related macular degeneration. *Br J Ophthalmol.* 2014; 98(2): 172 – 178.
  83. Chen Z, Mak C, Renick J, Lohse D, Dellamary L, Martin M, et al. A dual VEGFR/JAK2 kinase inhibitor suitable for topical delivery inhibits choroid neovascularization in mice. *Invest. Ophthalmol Vis Sci.* 2007; 48(5): 1469.
  84. Hoyng C, Vingerling J, Hooymans J, Klamerus K, Younis H, Khalil D, et al. AG-013958 (VEGFR inhibitor) achieves effective choroidal concentrations with minimal systemic effects in cynomolgus monkeys and humans with age-related macular disease. *Invest. Ophthalmol Vis Sci.* 2005; 46(5): 2365.
  85. Doukas J, Mahesh S, Umeda N, Kachi S, Akiyama H, Yokoi K, et al. Topical administration of a multi-targeted kinase inhibitor suppresses choroidal neovascularization and retinal edema. *J Cell Physiol.* 2008; 216(1): 29 – 37.
  86. Bingaman D, Liu C, Landers R, Gu X. AL-39324: A Potential 2nd Generation Agent for the Treatment of Pathologic Choroidal Neovascularization (CNV). *Invest Ophthalmol Vis Sci.* 2005; 46(5): 464.
  87. Dalal M, Jacobs-El N, Nicholson B, Tuo J, Chew E, Chan CC, et al. Subconjunctival Palomid 529 in the treatment of neovascular age-related macular degeneration. *Graefes Arch Clin Exp Ophthalmol.* 2013; 251(12): 2705 – 2709.
  88. Chen M, Muckersie E, Forrester JV, Xu H. Immune Activation in Retinal Aging: A Gene Expression Study. *Invest Ophthalmol Vis Sci.* 2010; 51(11): 5888 – 5896.
  89. Wang Y, Wang VM, Chan CC. The role of anti-inflammatory agents in age-related macular degeneration (AMD) treatment. *Eye.* 2011; 25(2): 127 – 139.
  90. Apte RS. Regulation of angiogenesis by macrophages. In: *Retinal Degenerative Diseases*: Springer; 2010: 15 – 19.
  91. Yang L, Froio RM, Sciuto TE, Dvorak AM, Alon R, Lusinskas FW. ICAM-1 regulates neutrophil adhesion and transcellular migration of TNF- $\alpha$ -activated vascular endothelium under flow. *Blood.* 2005; 106(2): 584 – 592.
  92. Coppin C, Kollmannsberger C, Le L, Porzolt F, Wilt TJ. Targeted therapy for advanced renal cell cancer (RCC): a Cochrane systematic review of published randomised trials. *BJU international.* 2011; 108(10): 1556 – 1563.
  93. Tsurufuji S, Sugio K, Sato H, Ohuchi K. A review of mechanism of action of steroid and non-steroid anti-inflammatory drugs. In: *Inflammation: Mechanisms and Treatment*. Willoughby DA, Giroud JP (editors): Springer Netherlands; 1981: 63 – 78.
  94. M Becerra E, Morescalchi F, Gandolfo F, Danzi P, Nascimbeni G, Arcidiacono B, et al. Clinical evidence of intravitreal triamcinolone acetonide in the management of age-related macular degeneration. *Curr Drug Targets.* 2011; 12(2): 149 – 172.
  95. Gopal L, Sharma T. Use of intravitreal injection of triamcinolone acetonide in the treatment of age-related macular degeneration. *Indian J Ophthalmol.* 2007; 55(6): 431.
  96. Ahmadiéh H, Taei R, Riazi-Esfahani M, Piri N, Homayouni M, Daftarian N, et al. Intravitreal bevacizumab versus combined intravitreal bevacizumab and triamcinolone for neovascular age-related macular degeneration: six-month results of a randomized clinical trial. *Retina.* 2011; 31(9): 1819 – 1826.
  97. Ahmadiéh H, Taei R, Soheilian M, Riazi-Esfahani M, Karkhaneh R, Lashay A, et al. Single-session photodynamic therapy combined with intravitreal bevacizumab and triamcinolone for neovascular age-related macular degeneration. *BMC Ophthalmology.* 2007; 7(1): 10.
  98. Medeiros MD, Navarro R, Garcia-Arumí J, Mateo C, Corcóstegui B. Dexamethasone intravitreal implant for treatment of patients with recalcitrant macular edema resulting from Irvine-Gass syndrome. *Invest Ophthalmol Vis Sci.* 2013; 54(5):3320-3324.
  99. Ranchod TM, Ray SK, Daniels SA, Leong CJ, Ting TD, Verne AZ. LuceDex: a prospective study comparing ranibizumab plus dexamethasone combination therapy versus ranibizumab monotherapy for neovascular age-related macular degeneration. *Retina* 2013; 33(8): 1600 – 1604.
  100. Kuppermann BD, Goldstein M, Maturi RK, Pollack A, Singer M, Tufail A, et al. Dexamethasone Intravitreal Implant as Adjunctive Therapy to Ranibizumab in Neovascular Age-Related Macular Degeneration: A Multicenter Randomized Controlled Trial. *Ophthalmologica.* 2015; 234(1): 40 – 54.
  101. Gallemore RP. NSAIDs in treatment of retinal disorders. *Expert Rev Ophthalmol.* 2006; 13(11): 81.
  102. Gomi F, Sawa M, Tsujikawa M, Nishida K. Topical bromfenac as an adjunctive treatment with intravitreal ranibizumab for exudative age-related macular degeneration. *Retina.* 2012; 32(9): 1804 – 1810.
  103. Wyględowska-Promieńska D, Piotrowska-Gwózdź A, Piotrowska-Seweryn A, Mazur-Piotrowska G, Rokicki W. Combination of bevacizumab and bromfenac therapy in age-related macular degeneration: A pilot study. *Med Sci Monit.* 2014; 20:1168 – 1175.
  104. Chen E, Benz MS, Fish RH, Brown DM, Wong TP, Kim RY, et al. Use of nepafenac (Nevanac®) in combination with intravitreal anti-VEGF agents in the treatment of recalcitrant exudative macular degeneration requiring monthly injections. *Clin Ophthalmol.* 2010; 4: 1249 – 1252.
  105. Libondi T, Jonas JB. Topical nepafenac for treatment of exudative age-related macular degeneration. *Acta ophthalmologica.* 2010; 88(2): e32 – e33.
  106. Group Advvs. Effect of adjunctive diclofenac with verteporfin therapy to treat choroidal neovascularization due to age-related macular degeneration: phase II study. *Retina.* 2007; 27(6): 693 – 700.
  107. Kim SJ, Flach AJ, Jampol LM. Nonsteroidal anti-inflammatory drugs in ophthalmology. *Surv Ophthalmol.* 2010; 55(2): 108 – 133.
  108. Russo A, Costagliola C, Delcassi L, Romano MR, Semeraro F. A randomised controlled trial of ranibizumab with and without ketorolac eyedrops for exudative age-related macular degeneration. *Br J Ophthalmol.* 2013; 97(10): 1273 – 1276.
  109. Semeraro F, Russo A, Delcassi L, Romano MR, Rinaldi M, Chiosi F, et al. Treatment of exudative age-related macular degeneration with ranibizumab combined with ketorolac eyedrops or photodynamic therapy. *Retina.* 2015; 35(8): 1547 – 1554.
  110. Eter N, Karl SE, Helb HM, Krohne T, Roth F, Bindewald A, et al. Intravitreal Methotrexate Injections in the Treatment of Choroidal Neovascularization in Age-Related Macular Degeneration. *Invest Ophthalmol Vis Sci.* 2005; 46(5): 1389.
  111. Sehgal S. Sirolimus: its discovery, biological properties, and mechanism of action. In: *Transplantation proceedings*: Elsevier; 2003; S7 – S14.
  112. Thomson AW, Turmquist HR, Raimondi G. Immunoregulatory functions of mTOR inhibition. *Nat Rev Immunol.* 2009; 9(5): 324 – 337.
  113. Goebel J, Stevens E, Forrester K, Roszman TL. Daclizumab (Zenapax®) inhibits early interleukin-2 receptor signal transduction events. *Transpl Immunol.* 2000; 8(3):153 – 159.
  114. Nussenblatt RB, Bymes G, Sen HN, Yeh S, Faia L, Meyerle C, et al. A randomized pilot study of systemic immunosuppression in the treatment of age-related macular degeneration with choroidal neovascularization. *Retina.* 2010; 30(10): 1579 – 1587.
  115. Theodossiadis PG, Liarakos VS, Sfrikakis PP, Vergados IA, Theodossiadis GP. Intravitreal Administration of the Anti-Tumor Necrosis Factor Agent Infliximab for Neovascular Age-related Macular Degeneration. *Am J Ophthalmol.* 2009; 147(5): 825 – 830.e821.
  116. Wu L, Arevalo JF, Hernandez-Bogantes E, Regatieri CV, Roca JA, Farah ME. Intravitreal tumor necrosis factor-alpha inhibitors for neovascular age-related macular degeneration suboptimally responsive to antivascular endothelial growth factor agents: a pilot study from the Pan American Collaborative Retina Study Group. *J Ocul Pharmacol Ther.* 2013; 29(3): 366 – 371.
  117. Fernández-Vega B, Fernández-Vega Á, Rangel CM, Nicieza J, Villota-Deleu E, Vega JA, et al. Blockade of Tumor Necrosis Factor-Alpha: A Role for Adalimumab in Neovascular Age-Related Macular Degeneration Refractory to Anti-Angiogenesis Therapy? *Case Rep Ophthalmol.* 2016; 7(1): 154 – 162.
  118. Jha P, Bora PS, Bora NS. The role of complement system in ocular diseases including uveitis and macular degeneration. *Mol. Immunol.* 2007; 44(16):3901 – 3908.
  119. Gehrs KM, Jackson JR, Brown EN, Allikmets R, Hageman GS. Complement, age-related macular degeneration and a vision of the future. *Arch Ophthalmol.* 2010; 128(3):349 – 358.
  120. Troutbeck R, Al-Qureshi S, Guymer RH. Therapeutic targeting of the complement system in age-related macular degeneration: a review. *Clin Exp Ophthalmol.* 2012; 40(1):18 – 26.
  121. Ni Z, Hui P. Emerging pharmacologic therapies for wet age-related macular degeneration. *Ophthalmologica.* 2009; 223(6): 401 – 410.