

Systematic Review and Meta-Analysis

Gonad Shielding during Pelvic Radiography: A Systematic Review and Meta-analysis

Vahid Karami MSc¹, Mansour Zabihzadeh PhD^{2,3}, Nasim Shams MD⁴, Amal Saki Malehi PhD⁵

Abstract

Background: Gonad shielding has been extensively advocated during pelvic radiography at or below reproductive ages. The popular practice of gonad shielding is placement of a lead shield in the midline of the pelvis. The aim of this study was to address the prevalence of gonad shielding and find out whether the current practice of gonad shielding can be considered as an effective method to reduce radiation exposure in patients undergoing pelvic radiography.

Methods: National and international electronic databases, including PubMed, MEDLIN, EMBASE, and Google-Scholar, were searched up to January 2016. The database searches were supplemented with manual searches of reference lists. Two authors independently assessed the eligibility of all studies and extracted data.

Results: The searches yielded a total of 243 publications. After assessing each identified study against specific inclusion exclusion criteria, 18 studies were deemed as relevant for this review. The total prevalence rate of gonad shielding was estimated at 58% (95% CI: 40 to 74%). It was estimated that only 34% (95% CI: 25 to 44%) of the radiographs had correct positioning of the shield. Also, incorrect positioning of the shield was statistically significantly higher in females than males (85% vs. 52 %; P -value <0.001).

Conclusions: Our study demonstrates that the current practice of gonad shielding during female pelvic radiography should be no longer considered as an effective method to reduce radiation exposure. Training the best qualified radiographers is the key to accurate positioning of the shield in male subjects.

Key words: Gonad shielding, Pelvic radiography, Radiation protection

Cite this article as: Karami V, Zabihzadeh M, Shams N, Saki Malehi A. Gonad Shielding during Pelvic Radiography: A Systematic Review and Meta-analysis. *Arch Iran Med.* 2017; **20**(2): 113 – 123.

Introduction

Radiography of the pelvis is one of the most common X-ray examinations.¹⁻⁵ It has been estimated that pelvis and hip radiography has an annual frequency of 39 per 1000 population and is the third biggest contributor of radiation dose from medical imaging in the United Kingdom.⁶ Since the 1950s, the pelvic X-ray examinations have been essentially concerning due to the placement of gonads in the irradiated field.^{3,7-12} As recommended by the international commission on radiological protection (ICRP), rapid proliferation of the gonadal cells makes them particularly sensitive to radiation effects.¹³ Germ cell irradiation can result in genetic mutations and malignant changes with the potential to be expressed in future generations.¹³⁻¹⁹ Furthermore, irradiating the lower section of colon (with high tissue weighting factor of 0.12) in pelvic radiography has been

recently highlighted.^{3,13,14} Accordingly, pelvis irradiation poses a risk to both genetic and somatic malignancies.^{14,16} Although the risk of radiation-induced fatal cancer followed to a single pelvic X-ray examination may not be significant (15 to 55 per million)⁷ but its stochastic risk should not be ignored. Hence, it is essential to follow safety guidelines to reduce radiation exposure of gonads to as low as reasonably achievable (ALARA).

Gonad shielding has been advocated as an effective method to reduce radiation exposure to the reproductive organs, especially in young patients.^{1,7,11,12,16,20,21} This is consistent with the recommendations of ICRP publication 34²² that states, “The gonads should be shielded when, of necessity, they are directly in the x-ray beam or within 5 cm of it, unless such shielding excludes or degrades important diagnostic information”. The concept of gonad shielding dates back to 1958.²³ Gonad shields are designed as contact or shadow shields²⁴⁻²⁶ with various shapes including hearts, diamonds, triangles, and squares,²⁷ traditionally placed in the mid-sagittal line of the pelvis directly on the basin pelvis (true pelvis) in females and lower than symphysis pubis on the scrotum region in males.²⁷⁻²⁹ Perfect positioning of gonad shields is achieved by completely covering the gonads without compromising the diagnostic information of the image.³⁰ It was declared that shielding the gonads with 1-mm lead (Pb) can reduce radiation dose to the testes and ovaries by about 95% and 50%, respectively (21, 31). Concerns of increased pelvis irradiation and its associated malignancy risk have led to extensive published studies on the extent and quality of gonad shielding in pelvic

Authors' affiliations: ¹Department of Medical Physics, School of Medicine, Ahvaz Jundishapur University of Medical Sciences, Ahvaz, Iran. ²Department of Medical Physics, Student Research Committee, School of Medicine, Ahvaz Jundishapur University of Medical Sciences, Ahvaz, Iran. ³Department of Clinical Oncology, Golestan Hospital, Ahvaz Jundishapur University of Medical Sciences, Ahvaz, Iran. ⁴Department of Oral and Maxillofacial Radiology, School of Dentistry, Ahvaz Jundishapur University of Medical Sciences, Ahvaz, Iran. ⁵Department of Biostatistics and Epidemiology, School of Public Health, Ahvaz Jundishapur University of Medical Sciences, Ahvaz, Iran.

Corresponding author and reprints: Mansour Zabihzadeh PhD, Department of Medical Physics, School of Medicine, Ahvaz Jundishapur University of Medical Sciences, Golestan Blvd., Ahvaz 61357-33118, Iran. Tel: +98-912-5032283, Fax: +98-613-3332066, E-mail: manzabih@gmail.com.

Accepted for publication: 21 December 2016

radiography.^{2,7,14,15,20,25,30-33} The results of these studies have indicated that gonad shielding is suboptimal.

Inaccurate positioning of gonad shield in pelvic radiography has been addressed by some researchers over the past two decades.^{14,15,20,31,33} Evidence indicates frequently incorrect positioning of gonad shields with little or no protection to the gonads, especially in pediatric girls who are highly sensitive to radiation.^{7,14,15,31,33,34}

Compromising of diagnostic information of images due to incorrect positioning of the shield can result in repetition of the examination.¹⁴ The extra radiation dose associated with the exposure repetitions may result in increased dose and eventually greater harm than a single unshielded exposure.^{14,31} Moreover, it has been demonstrated that the ovaries have variable positions extended to outside of the true pelvis that is intended to be shielded.^{27,28,31}

These concerns have led to various recommendations such as: abandoning ovarian shielding,^{27,28,31} omission of gonad shield in singular³⁵ or initial pelvic radiographs when two or more views are required,²⁰ re-design of gonad shields,³³ provision of written protocols,^{7,25} and adherence to better training programs.^{25,33} Despite these considerations and recommendations, routine use of gonad shielding, especially in pediatric pelvic radiography, remains controversial.

The aim of this systematic review and meta-analysis was to address the prevalence of gonad shielding in pelvic radiography projection and find out whether the current practice of gonad shielding can be considered as an effective method to reduce radiation exposure in patients undergoing pelvic radiography.

Materials and Methods

Literature search

Our systematic review and meta-analysis comply with the Preferred Reporting Items for Systematic Reviews and Meta-Analyses (PRISMA) guidelines.³⁶ The ethics committee of Ahvaz Jundishapur University of medical sciences approved the concept of this study (Grant No. U-94150). The following databases were searched without language restrictions for articles published in any year up to January 2016: "PubMed, MEDLIN, EMBASE, and Google-Scholar". An extensive search was performed using various combinations of the Mesh terms: "pelvic radiography, gonad shield/ing, radiation protection, x-ray, reproductive organs, testes, ovary, prevalence, and positioning". Designing and conducting the electronic search strategy were performed by an expert reference librarian based on input data from investigators. The database searches were supplemented with manual searches of reference lists of the potentially eligible articles. We also contacted other expert authors of the field to identify additional studies of potential interest.

Eligibility criteria

Eligibility criteria were established before the literature search and were applied by two independent reviewers (V.K. and M.Z., both with 3 years of experience in systematic reviewing). As the first inclusion criterion, only studies with presentation of data on pelvic radiography were retained. The second criterion for inclusion was that the studies addressed the prevalence of gonad shielding, and if available, the accuracy or inaccuracy of positioning the shields. The third criterion for inclusion was

the data should be obtained from direct evaluation of pelvic radiographs and not from questionnaire or observational studies. All other articles that did not clearly meet our inclusion criteria were excluded from the study.

Study selection

To assess eligibility, the initial search results were screened independently by two reviewers. First, the title and abstract of each article were carefully screened. Then, the full texts of articles that were deemed potentially relevant were retrieved for inclusion and additional searches of their reference lists were performed to identify other potentially relevant articles that may have been missed during computerized search of databases. The discrepancies between reviewers in study selection were resolved by consultation. If two reviewers could not reach a consensus, we planned to resolve the disagreement through discussion and consultation with a third reviewer (A.S.M.). The agreement was excellent as only one¹⁶ disagreement required the assistance of the third reviewer.

Data extraction

Two independent reviewers extracted the following data from each study using a standardized study record form: 1) authors, 2) country where the study was performed, 3) year of publication, 4) number of patients/pelvis radiographs, 5) patients age/sex, 6) methodology of the study, 7) total number of pelvic radiographs with/without shield (if available, in males and females, as well), and 8) total number of pelvic radiographs with adequacy/inadequacy of positioning the shield (if available, in males and females, as well).

Statistical Analysis

The prevalence and 95% confidence intervals (CI) of gonad shielding were estimated for each study. A forest plot was used to present the results of meta-analyses, which exhibits the estimates of prevalence and their confidence intervals for individual studies. Heterogeneity and inconsistency were evaluated using Cochrane Q and I² statistics, respectively. Furthermore, Egger's regression test was designed to assess small study effects and publication bias. The publication bias was also examined graphically using the 'funnel plot'. According to the results of the heterogeneity test, DerSimonian and Laird's random-effects method was used to pool the estimations. Also, subgroup analysis was done for incorrect positioning of the gonadal shields based on patients' gender. Statistical analysis was performed using STATA12 software (STATA Corporation, College Station, Texas). Two proportions test was implemented to determine whether the difference between male and female was significant. $P < 0.05$ was considered to be statistically significant for all test results as well as summary prevalence.

Results

Results of the search

The search flowchart is shown in Figure 1. The electronic search yielded a total of 243 publications. After eliminating 86 duplicates, 157 studies were screened on the basis of title and abstract, of which 89 studies were deemed irrelevant, 14 studies relevant and 54 studies of uncertain relevance. The reference lists of these 68 potentially relevant studies were screened and 12 studies of uncertain relevance were identified. The full texts of these 80

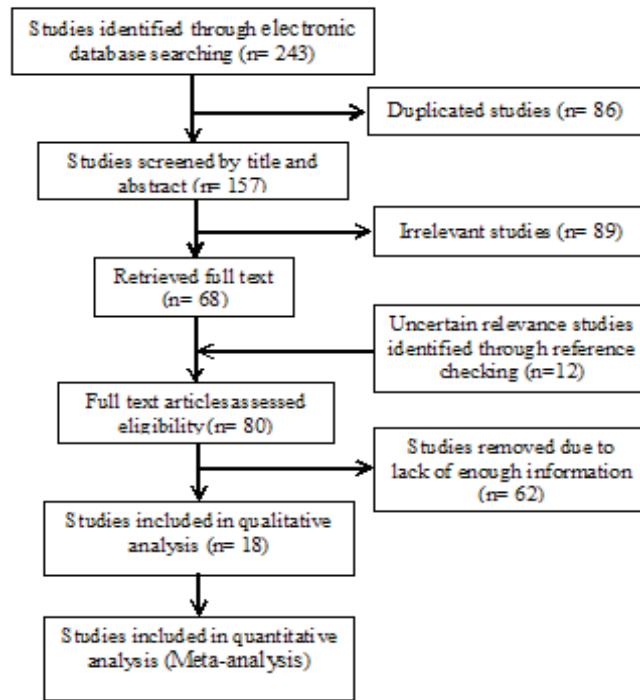


Figure 1. PRISMA flowchart of the study with detailed number of articles in each step.

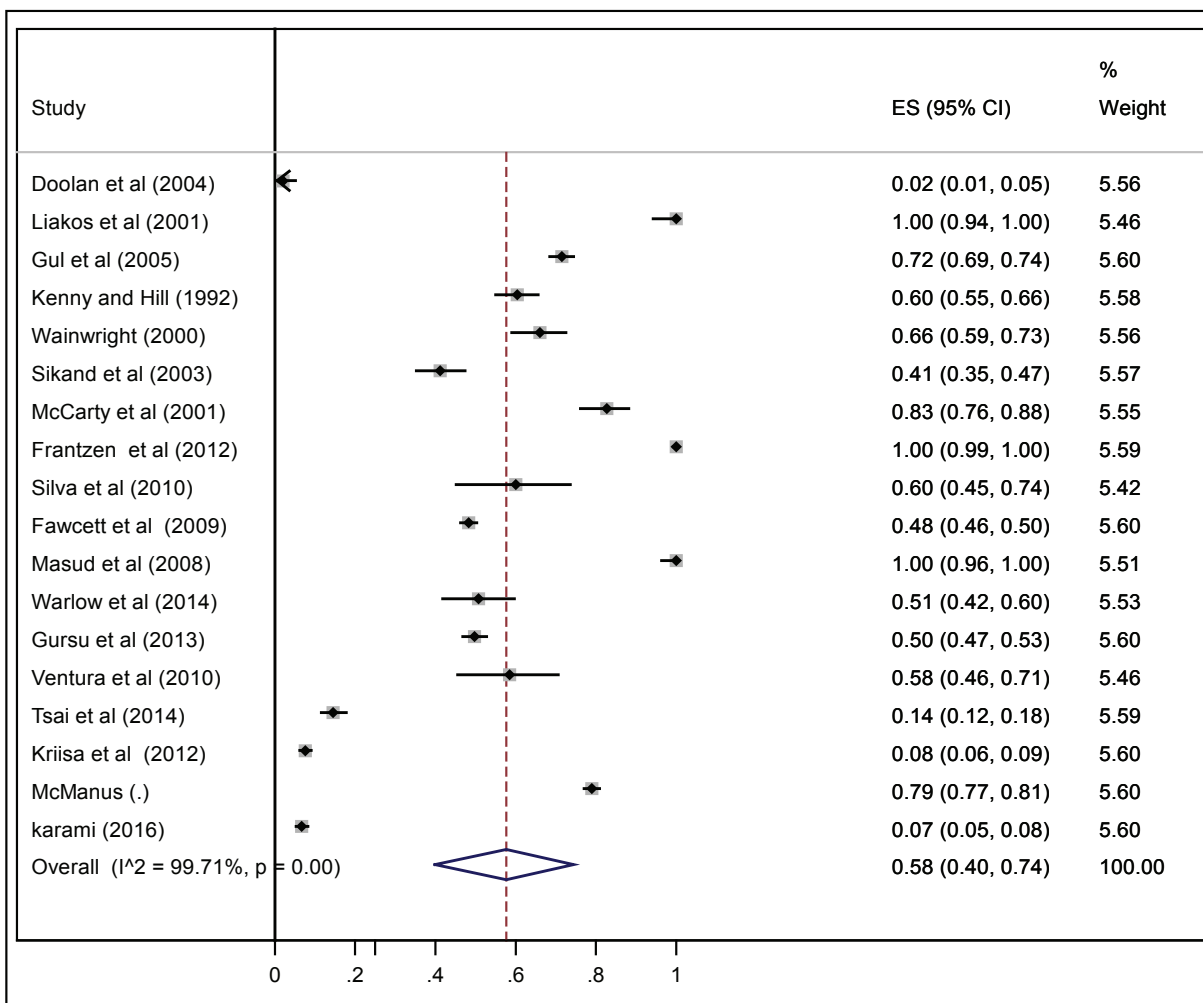


Figure 2. Prevalence Rate of Gonad Shielding and Its 95% Confidence Interval.

Table 1. Summary of studies included gonad shielding during pelvic radiography.

Study Published Year	M	No. of radiographs No. of patients Patients age, y	No. of radiographs with shield			No. of radiographs without shield		Comments	References
			AP	IP	Total	Total	Total		
Ireland 2004	R	198 120 —	0	4	4	194		Radiographs of accident and emergency patients were excluded of the study	Doolan <i>et al.</i> (2004) ⁷
U.S.A. 2001	R	62 61 4z-9	1	61	62	—		Only provided data of ovarian shielding	Liakos <i>et al.</i> (2001) ¹⁵
England 2005	R	948 111 1-16	466	212	678	270		The initial pelvic radiograph in trauma patients associate with the initial frog lateral view of other patients were excluded of the study	Gul <i>et al.</i> (2005) ¹
Iran 2016	R	1230 939 16<	31	51	82	1148			Karami <i>et al.</i> (2016) ³⁰
England 1992	R	346 32 8-15	100	109	209	137		Only complete set of pelvic radiographs in children treated for slipped capital femoral epiphysis were assessed	Kenny and Hill (1992) ³⁰
UK 2000	R	200 49 6mo-43	72	60	132	68		The initial pelvic radiograph were excluded of the study	Wainwright (2000) ³⁴
UK 2003	R	267 101 3mo-16	81	29	110	157		The initial pelvic radiograph in females and trauma patients were excluded of the study	Sikand <i>et al.</i> (2003) ²
UK 2001	R	218 50 <15	46	93	139	79			McCarty <i>et al.</i> ³²
Netherlands 2012	R	500 — <15	93	407	500	—		In 8 out of 193 male radiographs and 86 out of 307 female radiographs retake were required	Frantzen <i>et al.</i> ³¹

Portugal 2010	R	50 50 3mo-11	6	24	30	20	The absence and inadequacy positioning of the shield was found equally for both female and male patients.	Silva <i>et al.</i> ³⁶
UK 2009	R	2405 900 16<	438	723	1161	884	Images taken with an image intensifier were excluded of the study	Fawcett <i>et al.</i> ³⁷
England 2010	—	1720 — 16<	595	764	1359	361	—	McManus ³⁸
England 2008	R	100 62 16<	22	78	100	—	Inadequate protection of the gonads was unrelated to the patient's age or sex	Masud <i>et al.</i> ³⁹
UK 2014	R	130 130 16<	22	44	66	64	—	Warlow <i>et al.</i> ¹⁴
Turkey 2013	R	1137 675 6mo-17	104	462	566	571	Nineteen X-rays (3.3%) were repeated due to false-position of the gonadal shield	Gursu <i>et al.</i> ³³
Portugal 2010	R	65 65 3mo-13	15	23	38	27	Unprotected gonadal shielding was encountered almost in the same proportion for both genders, namely 51.9 percent of the female and 48.1 percent of the male children.	Ventura <i>et al.</i> ⁴⁰
China 2014	R	525 — <6	4	72	76	449	Only provided data on ovarian protection	Tsai <i>et al.</i> ⁴¹
Estonian 2012	R	1442 — <50	72	37	109	1333	Only provided data on scrotum shielding	Kriisa <i>et al.</i> ⁴²
M = methodology; AP = adequately protected; IP = inadequately protected; R = retrospective								

articles were retrieved and reviewed against specific inclusion exclusion criteria. Finally, 18 studies were deemed as relevant for this systematic review and meta-analysis. The characteristics of studies are summarized in Tables 1 and 2.

Description of studies

Eighteen studies published between 1992 and 2016 were identified for inclusion in this review. One study³³ was in Turkish language and the other 17 studies^{1,2,7,14,15,20,30-32,34,37-43} were in English. All these studies, excluding the re-audits of McCarty *et al.* (2001),³² were performed retrospectively using archived images in digital image libraries and common picture archiving and communication system (PACS). Patients were 0–50 years old and in 15 studies, they were younger than 18 years of age. Two studies^{15,41} focused only on ovarian shielding and one study⁴² only on testes shielding. The studies originated from 10 different countries: the UK (5), England (4), Portugal (2) and the remaining countries (China, Estonia, Iran, Ireland, Netherlands, Turkey and the USA) each had one study. Overall, 11,543 anterior-posterior (AP) pelvic radiographs were reviewed in these studies.

Meta-Analysis

The meta-analysis results are shown in Tables 3, 4 and 5 and Figures 2, 3, 4 and 5. The total prevalence rate of gonad shielding was estimated as 58% (95% CI: 40 to 74%). The gonad shields were adequately positioned in only 34% (95% CI: 25 to 44%) of the radiographs. Subgroup analysis based on patients' gender showed that the prevalence rate of shielding was more common in males than females (45 vs. 38; P -value = 0.79). Also, inaccurate positioning of the gonad shield was statistically significantly higher in females than males (85% vs. 52%; P -value < 0.001).

Discussion

Data on 11,543 AP pelvic radiographs were included in this systematic review and meta-analysis. We found that inaccurate positioning of the shields occurred frequently in pelvic radiography, especially in females. On the basis of our data, the total prevalence rate of gonad shielding was estimated as 58% (95% CI: 40–74%), of which gonadal shields were accurately positioned in only 34% (95% CI: 25–44%) of the radiographs (Table 3, Figures 2 and 3). It seems that during pelvic radiography, it is difficult to optimally position the shields without compromising diagnostic image information.^{25,31,44} One study²¹ highlighted that lack of confidence or skills of radiographers in adequate positioning of the shield is the main reason for non-optimal use. Kenny and Hill²⁰ in 1992 demonstrated that omission and inaccurate positioning of the shield were more common in females than males. Similar results have been reported by Wainwright *et al.* (2000)³⁴ and Fawcett *et al.* (2009).³⁷ This is presumably due to the difficulty associated with determining ovarian position based on surface landmarks and radiographer's fear of obscuring anatomy of interest. As shown in table 4, our subgroup analysis for use of gonadal shields based on patients' gender revealed that the prevalence rate of gonad shielding was more common in males than females (45% vs. 38%; P -value = 0.79). This might be stem from radiographer's belief that accurate positioning of the shield is more problematic in females than males. Also, it is estimated that inaccurate positioning of the shield was statistically significantly higher in females than males (85% vs. 52%; P -value < 0.001) (Table 5).

Due to the exterior location of the testes, shielding can be usually satisfactory.^{14,15} Adequate protection of the testes is highly dependent on the skill of radiographers in accurate positioning of the shield²¹ that can be improved with practical training. McCarty *et al.* (2001)³² showed that accurate positioning of the gonadal shield in males increased from 31.5% to 78.3% following multidisciplinary audit. However, in two studies^{33,34} re-design of gonadal shields was recommended.

In contrast to the testes, locating the ovaries based on surface landmarks is problematic and as a consequence, the ovarian shields are frequently incorrectly positioned.¹⁵ Frantzen *et al.* (2012)³¹ conducted a retrospective study on 500 pelvis radiographs and reported that gonadal shields were incorrectly positioned in 91% of girls' radiographs, and re-imaging was required for 28% of them. Their finding has been replicated by Liakos *et al.*¹⁵ Adequate protection of the ovaries requires knowledge of the ovaries' position.^{28,41} The 1982 ICRP⁴⁵ recommendations for ovary protection come mainly from two studies on ovaries' position comprising adult females and a small set of 13 children under the age of 12 years with relatively limited data.^{46,47} Subsequently, various studies have been carried out to address the position of the ovaries in the pelvic region by surgery,⁴⁶ ultrasonography,⁴⁸ computed tomography (CT)⁴⁹ and magnetic resonance imaging (MRI)^{27,28} evaluations. Altogether the results of these studies demonstrated that the ovaries have variable positions in the pelvic region including areas far from the midline (outside of the true pelvis that is intended to be shielded). Bardo *et al.*²⁷ retrospectively evaluated the ovaries' position on 336 pelvis and lumbar spine MRI images and reported that the ovaries are almost positioned in the lateral edges of the pelvis. In addition, the left and right ovaries in the same child have the potential to be located at different lateral distances from the midline of pelvis. Therefore, they highlighted that the ovarian shields should be placed in a lateral position instead of midline of the pelvis whenever possible, or completely abandoned. Two studies^{31,50} therefore highlighted that the disadvantages may prevail over benefits, when using ovarian shields during pelvic radiography. However, the ovaries' position depends on the patient's age^{27,28} and amount of urine in the bladder.^{28,51} Fawcett *et al.*²⁸ demonstrated that when the bladder is empty, it is more likely that both ovaries are located inside the true pelvis that is intended to be protected by the shield. Also with increasing patients' age, it is more likely to have at least one ovary inside the true pelvis. Therefore, if a shield is used, it is better that the bladder is empty and patient is an adult, whenever possible.

As known from the literature,^{1,2,14,15,32,34,37} in most institutions it is widely accepted that the ovarian shield should be eliminated for singular or first view when two or more radiographic studies are ordered with employing the shield for subsequent exposures. Regardless of training challenges in institutions with a significant turnover of radiographers, a restless, uncooperative patient (especially hyperactive persons, i.e. children with autism), and the risk of transient compliance by radiographers, it should be noted that the ovaries are located almost outside of the area intended to be protected by the shield (true pelvis), it is demonstrated that even accurate positioning of the shield will not provide protection to the ovaries in over one third of children.²⁸ This concept can also be concluded from ICRP report 34⁴⁵ and other reliable sources in the literature,^{26,31} stating that gonad shielding can decrease the radiation exposure to the ovaries by 50%. This degraded level of protection of the ovaries is due to the location of the ovaries almost

Table 2. Incorrectly positioning of the gonadal shields according to patients gender.

Male	No. of radiographs with shield		Percentage of radiographs with inaccuracy positioning of the shield (when employed)		References
	Female	Total	Male	Female	
82	57	139	64	72	McCarty <i>et al.</i> (2001) ³²
102	107	209	44.1	59.8	Kenny and Hill (1992) ²⁰
52	30	82	46	90	Karami <i>et al.</i> (2016) ³⁰
86	46	132	38.3	58.7	Wainwright (2000) ³⁴
611	550	1161	52	73.6	Fawcett <i>et al.</i> (2009) ³⁷
2	2	4	100	100	Doolan <i>et al.</i> (2004) ⁷
193	373	566	61.6	91.9	Gursu <i>et al.</i> (2012) ³³
—	76	76	—	94.7	Tsai <i>et al.</i> * (2015) ⁴¹
193	307	500	66	91	Frantzen <i>et al.</i> (2012) ³¹
—	62	62	—	98	Liakos <i>et al.</i> * (2001) ¹⁵
34	32	66	41	94	Warlow <i>et al.</i> (2014) ¹⁴
—	—	1359	59	71	McManus <i>et al.</i> (2015) ³⁸
109	—	109	34	—	Kriisa <i>et al.</i> ** (2012) (42)

*Only provided data on ovarian shielding, **Only provided data on scrotum shielding.

Table 3. The total prevalence rate of gonad shielding and adequate shielding (95% confidence interval).

Gonad shielding	No. of studies	No. of radiographs	Prevalence (95% CI)	I ² %	Heterogeneity test			
					Q	P	I ²	
Prevalence of Shielding	18	11543	0.58 (0.40 – 0.74)	99.70	5916.5	<0.001	0.69	0.50
Adequate Shielding	18	11543	0.34 (0.25- 0.44)	97.70	743.93	<0.001	0.57	0.58

Table 4. The prevalence rate of gonad shielding in males and females (95% confidence interval).

Gonad Shielding	No. of studies	Prevalence of shielding (95% CI)	I ² %	Heterogeneity Test		Egger test	
				Q	P	t	P
Male	7	0.45*(0.21– 0.70)	99	1163	< 0.001	1.25	0.27
Female	7	0.38*(0.19 – 0.60)	99	694	< 0.001	0.74	0.5

*Z= 0.27, *P-value = 0.79

Table 5. Inaccuracy positioning of gonad shield in males and females, when a shield was present (95% confidence interval).

Gonad Shielding	No. of studies	No. of radiographs	Inaccuracy positioning of the shield (95% CI)	I ² %	Heterogeneity Test		Egger test	
					Q	P	t	P
Male	11	1464	0.52*(0.46 – 0.58)	83.6	61	< 0.001	0.73	0.48
Female	12	1642	0.85*(0.76 – 0.92)	95	202	< 0.001	0.71	0.49

*Z = 17.78, * P-value < 0.001

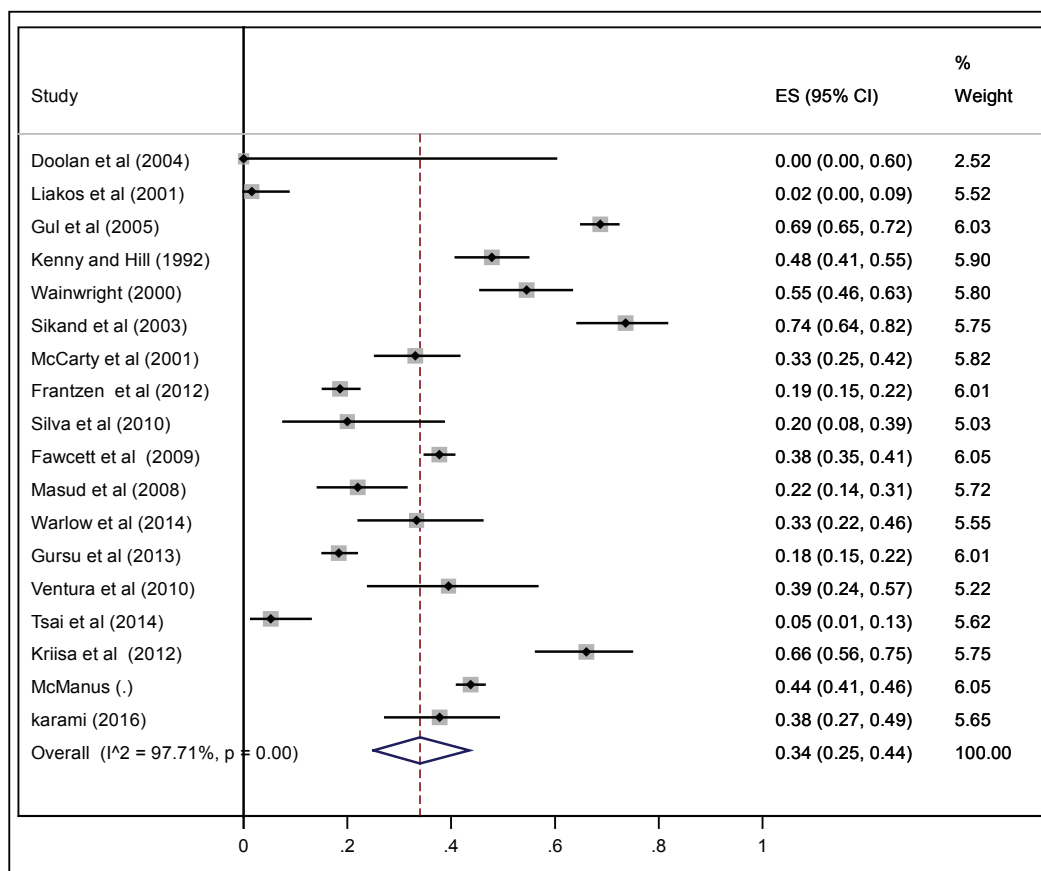


Figure 3. Proportion of Adequate Shielding and Its 95% Confidence Interval.

outside the true pelvis. Optimal radiation protection of ovaries needs covering the entire pelvis which is not possible in practice as it obscures pelvic anatomy (See Bardo *et al.*²⁷ their Figure 5).

If we accept that gonad shields were inaccurately positioned in 85% of female radiographs and for the remaining 15%, the shield did not necessarily provide protection to the ovaries, use of gonad shields during female pelvic radiography may not be justified. Reducing tissue weighting factor of gonads from 0.20 to 0.08 in 2007 is also reinforced in these statements.¹³ Considering the results of this study associated with ICRP-103 recommendation that states, “any decision that alters the radiation exposure

situation should do more good than harm”,¹³ it seems better to discontinue ovarian shielding during females pelvic radiography. However, decision on the use of gonad shields in male subjects is controversial and depends on the skill and efforts of radiographers in accurate positioning of the shield. Indeed, we need to train the best qualified radiographers and strive to reinforce motivation toward the use of gonad shields in males. Provision of written gonad shielding protocols associated with re-design of shields may also improve accurate positioning of the shield in male subjects. We are currently undertaking a study on design and dosimetry of new gonadal shields for females and also re-design

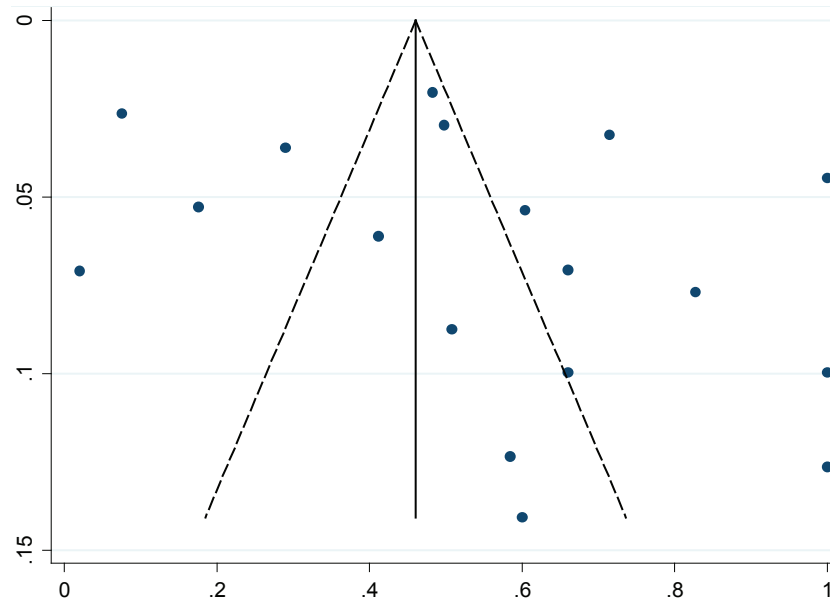


Figure 4. Funnel plot for the prevalence rate of gonad shielding.

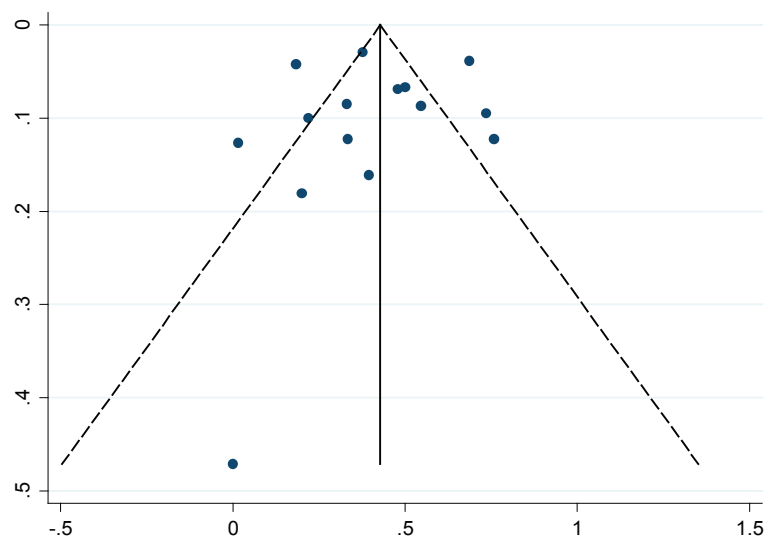


Figure 5. Funnel plot for the adequate positioning of the shield.

of current gonadal shields in males using materials that attenuate radiation beam yet allow sufficient X-ray beams to pass to be able to yield an acceptable diagnostic image of pelvis.⁵⁰

Limitations

Firstly, in five studies^{1,2,14,32,34} owing to the institutional policy, the initial pelvic radiographs were performed without shield and were excluded from the study; while other studies did not follow these criteria.

Secondly, in some studies, the reported prevalence and accurate positioning of shields during radiographies were not specified for males and/or females. Furthermore, the sample size of some studies was not reported.

Conclusion

Our meta-analysis demonstrates that the current practice of ovarian shielding should be no longer considered as an effective method to address ALARA and there is enough evidence to abandon ovarian shielding during female pelvic radiography. However, training the best qualified radiographers is key to accurate positioning of the shield in male subjects.

Advances in knowledge

- Ovarian shielding during female pelvic radiography is not an effective radiation protection technique and it is better to be discontinued.

- The practice of gonad shielding in the male subjects is controversial and depends on the skill and efforts of radiographers in accurate positioning of the shield that will be improved with better practical training.

Authors' contributions

Guarantor of integrity of entire study, M.Z.; study concepts/ study design or data acquisition or data interpretation, V.K., M.Z.; manuscript drafting or manuscript revision for important intellectual content, V.K., M.Z., N.S.; approval of final version of submitted manuscript, V.K., M.Z., N.S., A.S.; literature research, an expert librarian with inputs of V.K., M.Z.; statistical analysis, A.S.; and manuscript editing, M.Z., N.S.

References

- Gul A, Zafar M, Maffulli N. Gonadal shields in pelvic radiographs in pediatric patients. *Bull Hosp Jt Dis*. 2005; 63(1/2): 13 – 14.
- Sikand M, Stinchcombe S, Livesley P. Study on the use of gonadal protection shields during paediatric pelvic X-rays. *Ann R Coll Surg Engl*. 2003; 85(6): 422 – 425.
- Chan C, Fung K. Dose optimization in pelvic radiography by air gap method on CR and DR systems—A phantom study. *Radiography*. 2015; 21(2015): 214 – 223.
- Manning-Stanley AS, Ward AJ, England A. Options for radiation dose optimisation in pelvic digital radiography: a phantom study. *Radiography*. 2012; 18(4): 256 – 263.
- Almen A, Mattsson S. The radiation dose to children from X-ray examinations of the pelvis and the urinary tract. *Br J Radiol*. 1995; 68(810): 604 – 613.
- Tugwell J, Everton C, Kingma A, Oomkens D, Pereira G, Pimentinha D, et al. Increasing source to image distance for AP pelvis imaging—Impact on radiation dose and image quality. *Radiography*. 2014; 20(4): 351 – 355.
- Doolan A, Brennan PC, Rainford LA, Healy J. Gonad protection for the antero-posterior projection of the pelvis in diagnostic radiography in Dublin hospitals. *Radiography*. 2004; 10(1): 15 – 21.
- Holmberg O, Malone J, Rehani M, McLean D, Czarwinski R. Current issues and actions in radiation protection of patients. *Eur J Radiol*. 2010; 76(1): 15 – 19.
- Mettler F, Huda W, Yoshizumi T, Mahesh M. Effective doses in radiology and diagnostic nuclear medicine: a catalog. *Radiology*. 2008; 248(1): 254 – 263.
- Culp MP, Barba JR, Jackowski MB. Shield Placement: Effect on Exposure. *Radiol Technol*. 2014; 85(4): 369 – 376.
- Ofori EK, Antwi WK, Scutt DN, Ward M. Patient Radiation Dose Assessment in Pelvic X-ray Examination in Ghana. *OMICS J Radiology*. 2013; 2(8): 1 – 5.
- Ofori EK, Antwi WK, Scutt DN, Ward M. Optimization of patient radiation protection in pelvic X-ray examination in Ghana. *J Appl Clin Med Phys*. 2012; 13(4): 165.
- Recommendations of the International Commission on Radiological Protection. ICRP publication 103. *Ann ICRP* 2007; 37(2-4): 1 – 332.
- Warlow T, Walker-Birch P, Cosson P. Gonad shielding in paediatric pelvic radiography: Effectiveness and practice. *Radiography*. 2014; 20(3): 178 – 182.
- Liakos P, Schoenecker PL, Lyons D, Gordon JE. Evaluation of the efficacy of pelvic shielding in preadolescent girls. *J Pediatr Orthop*. 2001; 21(4): 433 – 435.
- Winfeld M, Strubel N, Pinkney L, Lala S, Milla S, Babb J, et al. Relative distribution of pertinent findings on portable neonatal abdominal radiographs: can we shield the gonads? *Pediatr Radiol*. 2013; 43(10): 1295 – 1302.
- Zuckerman S. The sensitivity of the gonads to radiation. *Clin Radiol*. 1965; 16(1): 1 – 15.
- Hall EJ, Giaccia AJ. *Radiobiology for the Radiologist*. Philadelphia: Lippincott Williams & Wilkins; 2006.
- Banaee N, Nedaie H. Evaluating the effect of energy on calibration of thermo-luminescent dosimeters 7-LiF: Mg, Cu, P (GR-207A). *Int J Radiat Res*. 2013; 11(1): 51 – 54.
- Kenny N, Hill J. Gonad protection in young orthopaedic patients. *BMJ*. 1992; 304(6839): 1411 – 1413.
- MacKay M, Hancy C, Crowe A, D'Rozario R, Ng C. Attitudes of medical imaging technologists on use of gonad shielding in general radiography. *Radiographer*. 2012; 59(2): 35 – 39.
- Wall B, Fisher E, Shrimpton PC, Rae S. *Current Levels of Gonadal Irradiation from a Selection of Routine Diagnostic X-ray Examinations in Great Britain*. Harwell (UK): National Radiological Protection Board; 1980.
- Hodges PC, Strandjord NM, McCrea A. A testicular shield. *JAMA*. 1958; 167(10): 1239 – 1240.
- Dowd SB, Tilson ER. *Practical Radiation Protection and Applied Radiobiology*. Philadelphia, PA: WB Saunders; 1999.
- Karami V, Zabihzadeh M, Gholami M. Gonad shielding for patients undergoing conventional radiological examinations: Is there cause for concern? *Jentashapir J Health Res*. 2015; 7(2): 1 – 4.
- Raissaki MT. Pediatric radiation protection. *Eur Radiol Suppl*. 2004; 14(1): 74 – 83.
- Bardo DM, Black M, Schenk K, Zaritzky MF. Location of the ovaries in girls from newborn to 18 years of age: reconsidering ovarian shielding. *Pediatr Radiol*. 2009; 39(3): 253 – 259.
- Fawcett S, Gomez A, Barter S, Ditchfield M, Set P. More harm than good? The anatomy of misguided shielding of the ovaries. *Br J Radiol*. 2014; 85(2012): 442 – 447.
- Long BW, Frank ED, Ehrlich RA. *Radiography Essentials for Limited Practice*. 2nd ed. Philadelphia, PA: Saunders, 2005: 152 – 154.
- Silva C, Silva P, Ventura SMR. The use and relevance of gonad protection shields in children during hips radiography. I Congresso Internacional da Saúde Gaia-Porto; 2010: Instituto Politécnico do Porto. Escola Superior de Tecnologia da Saúde do Porto-Politema.
- Frantzen MJ, Robben S, Postma AA, Zoetelief J, Wildberger JE, Kemerink GJ. Gonad shielding in paediatric pelvic radiography: disadvantages prevail over benefit. *Insights Imaging*. 2012; 3(1): 23 – 32.
- McCarty M, Waugh R, McCallum H, Montgomery RJ, Aszkenasy OM. Paediatric pelvic imaging: improvement in gonad shield placement by multidisciplinary audit. *Pediatr Radiol*. 2001; 31(9): 646 – 649.
- Gürsu S, Gürsu T, Camurcu Y, Yıldırım T, Gürsu A, Şahin V. Efficacy of gonadal shielding in pediatric pelvis X-rays [in Turkish]. *Ekleml Hastalıklar Cerrahisi*. 2012; 24(2): 87 – 90.
- Wainwright A. Shielding reproductive organs of orthopaedic patients during pelvic radiography. *Ann R Coll Surg Engl*. 2000; 82(5): 318 – 321.
- Wilcher TF, Clarke R, McLennan C, Dickson S, Buxton A, Stonehouse M, et al. The use of gonadal shielding in singular common diagnostic radiographic procedures. *Radiographer*. 2007; 54(2): 13 – 17.
- Moher D, Liberati A, Tetzlaff J, Altman DG. Preferred reporting items for systematic reviews and meta-analyses: the PRISMA statement. *Ann Intern Med*. 2009; 151(4): 264 – 269.
- Fawcett SL, Barter SJ. The use of gonad shielding in paediatric hip and pelvic radiographs. *British J Radiol*. 2009; 82(977): 363 – 370.
- McManus A, Davis N. The gonad shield in pelvic X-rays covering a multitude of sins? Available from: URL: <http://www.epos.efort.org/public/Sorrentoeposters/3958.ppt> (Accessed 1 Oct 2015).
- Masud S, Mehra A, Clothier J. Study on the use of gonadal shields in paediatric pelvic x-rays. *J Bone Joint Surg Br Vol*. 2008; 90(SUPP II): 338.
- Ventura SMR, Monteiro A, editors. Radiographic outcomes and evaluation of developmental dysplasia of the hip in children. I Congresso Internacional da Saúde Gaia-Porto; 2010: Instituto Politécnico do Porto. Escola Superior de Tecnologia da Saúde do Porto-Politema.
- Tsai YS, Liu YS, Chuang MT, Wang CK, Lai CS, Tsai HM, et al. Shielding during x-ray examination of pediatric female patients with developmental dysplasia of the hip. *J Radiol Prot*. 2014; 34(4): 801 – 809.
- Kriisa M, Silluta S, Tallinn E. Male gonad shielding efficiency and use in pelvic area x-ray examinations in Estonia. 2012: 1 – 10.
- Karami V, zabihzadeh M, Sarikhani S. Evaluation of the frequency and accuracy of gonad shield placement in patients undergoing pelvic radiography. *Brazilian J Radiation Sci*. 2016; 4(1): 1 – 8.
- Clancy CL, O'Reilly G, Brennan PC, McEntee MF. The effect of patient shield position on gonad dose during lumbar spine radiography. *Radiography*. 2010; 16(2): 131 – 135.
- International Commission on Radiological Protection (ICRP). Protection of the patient in diagnostic radiology, ICRP Publication 34. *Ann ICRP*. 1982; 9: 22 – 40.

46. Fochem K, Pape R. Problematik des ovarialschizes bei rontgenaufnahmen des beckens. *Fortschr Geb Roentgenstr Nuklearmed.* 1962; 97(12): 785 – 793.
47. Memon A, Godward S, Williams D, Siddique I, Al-Saleh K. Dental x-rays and the risk of thyroid cancer: a case-control study. *Acta Oncologica.* 2010; 49(4): 447 – 453.
48. Featherstone C, Harnett A, Brunt A. Ultrasound localization of the ovaries for radiation-induced ovarian ablation. *Clin Oncol.* 1999; 11(6): 393 – 397.
49. Counsell R, Bain G, Williams M, Dixon A. Artificial radiation menopause: Where are the ovaries? *Clin Oncol.* 1996; 8(4): 250 – 253.
50. Karami V, Zabihzadeh M, Gholami M. Design and dosimetry of bismuth gonadal shield to radioprotection to the gonads during pediatric pelvic radiography. Ahvaz Jundishapur University of Medical Sciences; 2016.
51. Nicholson R, Coucher J, Thornton A, Connor F. Effect of a full and empty bladder on radiation dose to the uterus, ovaries and bladder from lumbar spine CT and X-ray examinations. *Br J Radiol.* 2000; 73(876): 1290 – 1296.