

Case Report

Hepatobiliary Cystadenoma Mimicking Liver Hydatid Cyst

Bitra Geramizadeh MD¹, Maryam Asadian MD¹, Mohammad Hassan Hourang MD²

Abstract

Hepatobiliary cystadenoma is a rare tumor which is difficult to diagnose before surgery and pathologic examination. Herein we present the case of a 32-year-old woman from an endemic area for hydatid cysts who presented with the impression of hydatid cyst of the liver, which was completely resected. Histopathologic examination revealed a mucinous hepatic cystadenoma with ovarian-like stroma. She had an uneventful postoperative course and now, after one year, she is doing well.

Keywords: hepatobiliary cystadenoma, hydatid cyst, liver

Introduction

Hepatobiliary cystadenoma is a rare epithelial tumor of the liver.¹ This cystic tumor represents less than 5% of the hepatic cystic tumors that are of biliary origin.²

Hepatobiliary cystadenoma with mesenchymal ovarian type stroma is less common and occurs exclusively in females.³

Herein we report an unusual case that presented in an endemic area for hydatid cyst, which was operated with the clinical and paraclinical impression of hydatid cyst.³

Case Report

A 32-year-old woman presented with flank pain. She was found to have a hepatic cyst by sonography in the medial segment of the left hepatic lobe, which measured 70 mm in diameter (Figure 1) and was confirmed by CT scan (Figure 2).

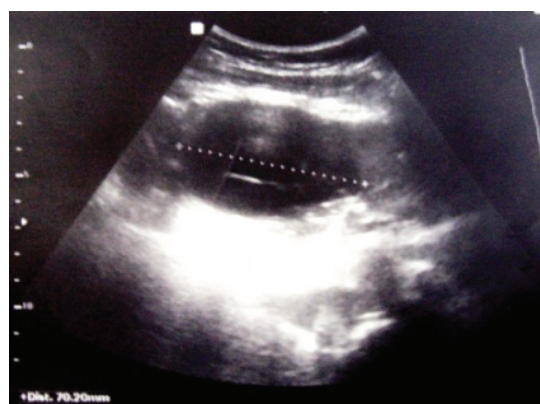

Figure 1. Sonography of the hepatic mass

Authors' affiliation: ¹Transplant Research Center, Pathology Department, Shiraz University of Medical Sciences, Shiraz, Iran, ² Department of Surgery, Fassa University of Medical Sciences, Fassa, Iran.

Corresponding author and reprints: Bitra Geramizadeh MD, Transplant Research Center, Department of Pathology, Shiraz University of Medical Sciences, Shiraz, Iran. P.O. Box: 71345-1864, Telefax: +98-711-647-4331, E-mail: geramib@sums.ac.ir
Accepted for publication: 14 April 2010

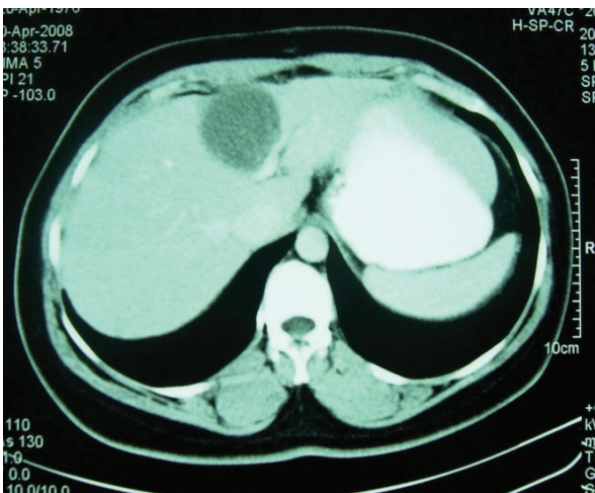


Figure 2. CT scan shows a liver mass

The patient lived on a farm in an endemic area for hydatid cyst and had positive immunodiagnostic tests for echinococcal antibody. Surgical operation revealed a 7 cm mass in the left liver lobe.

The cyst was excised by segmentectomy and microscopic examination showed some loculated cysts lined by mucinous epithelium and a mesenchymal ovarian type stroma (Figure 3).

Her post-operative course was uneventful and she was discharged in good condition. Now, after one year, she is doing well.

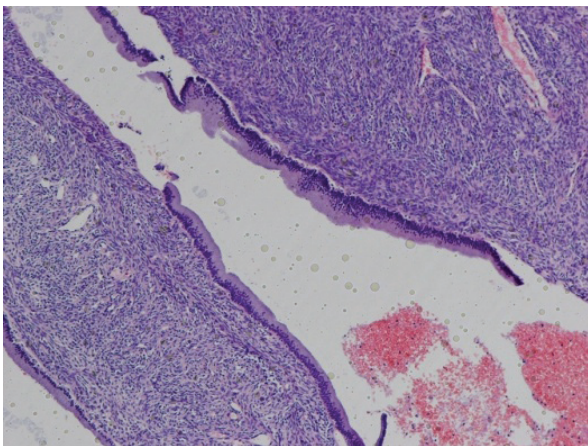


Figure 3. Sections from the liver cyst show two components (epithelial lining of mucinous epithelium and ovarian type mesenchymal stroma) (H&E 250×)

Discussion

Hepatobiliary cystadenoma is a rare tumor, the histogenesis of which is uncertain.

One of the proposed theories according to its histo-

genesis is that it derives from an ectopic ovary.⁴ The other theory considers a congenital origin from an aberrant intrahepatic biliary duct or from misplaced germ cells.¹

Rare cases of cystadenoma with ovarian type stroma are reported in the literature.⁵ They are exclusively reported in middle-aged women and have two essential tumor components: a cyst lining of columnar to cuboidal mucin secreting epithelium and moderate-to-dense cellular stroma composed of spindle cells.⁶

These tumors can be clinically silent and only discovered on ultrasonography. Reported complications are internal bleeding, infection, rupture, and malignant transformation.⁷ Although pain, mass, jaundice, and abnormal liver function tests may point to a hepatobiliary abnormality, this suspicion is usually low.⁷

Our case presented with vague flank pain from an endemic area for hydatid cyst and also a positive counter current immunoelectrophoresis (CCIEP) for hydatid cyst, thus the patient underwent surgical removal with the impression of a parasitic cyst.

Until now, no hepatobiliary cystadenoma has been reported that mimicks a hydatid cyst.

The treatment of choice is surgery and a study has reported that 30% of the hepatic cystadenocarcinomas arise from preexisting biliary cystadenoma; therefore malignant transformation is of distinct importance.¹

Our case underwent surgery with no complications and currently she is completely well after one year.

In conclusion, these types of cysts should also be considered in the differential diagnosis of hydatid cyst, even in endemic countries such as Iran.

References

1. Beuran M, Venter MD, Dumitra L. Large mucinous biliary cystadenoma with ovarian like stroma: a case report. *World J Gastroenterol.* 2006; **12**: 3779 – 3781.
2. Sutton CD, White SA, Berry DP, Dennison AR. Intrahepatic biliary cystadenoma causing luminal common bile duct obstruction. *Dig Surg.* 2000; **17**: 297 – 299.
3. Mohan H, Bal A, Arya S, Jain P, Bawa AS. Hepatobiliary cystadenoma with mesenchymal stroma-a case report. *Indian J Pathol Microbiol.* 2006; **49**: 291 – 293.
4. Abdul-Al HM, Makglouf HR, Goodman ZD. Expression of estrogen and progesterone receptors and inhibin- α in hepatobiliary cystadenoma: an immunohistochemical study. *Virchows Arch.* 2007; **450**:

- 691 – 697.
5. Pedram-Canihac M, Le Bail B, Rivel J, Blanc JF, Saric J, Bioulac-Sage P. Hepatobiliary cystadenoma with mesenchymal stroma: a hormonal dependant tumor. Report of five cases with immunohistochemical study of hormone receptors. *Ann Pathol.* 2000; **20**: 14 – 18.
 6. Wheeler DA, Edmonson HA. Cystadenoma with mesenchymal stroma (CMS) in the liver and bile ducts. A clinicopathologic study of 17 cases, 4 with malignant change. *Cancer.* 1985; **56**: 1434 – 1445.
 7. Akwari OE, Tucker A, Seigler HF, Itani KM. Hepatobiliary cystadenoma with mesenchymal stroma. *Ann Surg.* 1990; **211**: 18 – 27.