

Original Article

The Prevalence of Prostatic Stromal Tumor of Uncertain Malignant Potential in Specimens Diagnosed as Prostatic Hyperplasia

Maral Mokhtari MD¹, Maryam Homayoun MD², Shahrzad Yazdan Panah MD¹

Abstract

Background: Prostatic stromal tumors of uncertain malignant potential (STUMPs) are rare tumors arising from the specialized prostatic stroma. These tumors share certain histological and clinical features of benign prostatic hyperplasia, resulting in misdiagnosis of STUMP as prostatic hyperplasia. However, in contrast to prostatic hyperplasia, occasional cases have been documented to recur rapidly after resection and few of them have progressed to prostatic stromal sarcoma and distant metastasis. In this study, we aimed to estimate the prevalence of prostatic STUMP in specimens initially diagnosed as prostatic hyperplasia.

Material and Method: A total of 702 consecutive pathology slides with a diagnosis of prostatic hyperplasia between 2009 to 2014 in specimens were obtained by prostatectomy or trans-urethral resection of the prostate. Those slides were submitted to Faghihi hospital, affiliated to Shiraz University of Medical Sciences, and were reviewed retrospectively in order to search the findings in favor of STUMP.

Results: Based on histological findings, STUMP was identified in 3 cases (0.43%), which revealed hypercellular stroma, infiltrating between the hyperplastic glands. Cells showed some degree of pleomorphism, nuclei with vesicular chromatin and few mitotic figures. No recurrence was reported in patients.

Conclusion: Although STUMP can be histologically and clinically misdiagnosed as BPH, the differences in prognosis and treatment modalities highlight the importance of rendering the correct diagnosis.

Keywords: Prostate, prostatic hyperplasia, stromal tumor of uncertain malignant potential

Cite this article as: Mokhtari M, Homayoun M, Yazdan Panah S. The prevalence of prostatic stromal tumor of uncertain malignant potential in specimens diagnosed as prostatic hyperplasia. *Arch Iran Med.* 2016; **19(7)**: 488 – 490.

Introduction

Prostatic stromal tumors of uncertain malignant potential (STUMPs), are distinct and quite rare lesions which arise from specialized prostatic stroma.¹ Classically, they present in the sixth and seventh decades of life² and have the potential to infiltrate the entire prostate gland, as well as adjacent tissues.²⁻⁵ The clinical course is unpredictable, ranging from a focal incidental finding on biopsy that never progresses, to a highly aggressive lesion leading to widespread metastases and death.⁶

The clinical, laboratory, and imaging abnormalities associated with STUMPs are generally nonspecific. The most common presenting signs and symptoms were chronic lower urinary tract obstructive symptoms, abnormal digital rectal examination findings, hematuria, hematospermia, rectal dysfunction and/or a sensation of fullness, acute urinary retention, and elevated prostate specific antigen levels.^{3,6-10} On rectal examination, the prostate may be diffusely enlarged, nodular, or soft, spongy, and cystic.³

Histologically, STUMPs may have four distinct patterns based on the degree of stromal cytologic atypia. The presence and appearance of a non-neoplastic epithelial component and patterns

may coexist in the same specimen. The first pattern, degenerative atypia, demonstrating marked cellular atypia, is the most common one, which accounts for at least 50% of cases. It is composed of normal to slightly hypercellular stroma with scattered cytologically atypical cells interdigitating between benign prostatic glands.

The second histological pattern, hypercellular, consists of hypercellular stroma composed of bland, and fusiform cells with eosinophilic cytoplasm. The third pattern is composed of an expanded stroma and proliferating benign glandular elements, reminiscent of the phyllodes tumor of the breast.^{3,9,11,12} The stroma is hypocellular, fibrotic, leaf-like in configuration, and devoid of mitotic figures. The fourth pattern, myxoid, is composed of an expansive overgrowth of the bland stromal cells within a myxoid background.^{2,7,8,10,11,13}

Clinical and histological features of STUMP may closely mimic benign prostatic hyperplasia (BPH), but recognition of this entity is an important therapeutic and prognostic implication due to the risk of recurrence and possibility of progression to malignant prostatic stromal sarcoma.

This study was designed to evaluate the prevalence of prostatic STUMP in a large, high-quality sample initially diagnosed as BPH.

Material and Method

The pathology reports of the Shahid Faghihi Hospital in Shiraz, Iran were searched in this retrospective study. A total of 702

Authors' affiliations: ¹Pathology Department, Shiraz University of Medical Sciences, Shiraz, Iran, ²Student Research Committee, Shiraz University of Medical Sciences, Shiraz, Iran.

Corresponding author and reprints: Maral Mokhtari MD, Pathology Department, Shiraz University of Medical Sciences, Zand St, Shiraz, Iran, P. O. box: 71345-1864, Fax: +98-71-32301784, E-mail: Maral_mokhtari@yahoo.com. Accepted for publication: 11 May 2016

Table 1. Characteristics and Clinical Courses of Patients with Prostatic STUMP Initially Diagnosed as BPH

| Case number | Age | Clinical presentations | Procedure | Diagnosis | F/U (years) | Outcome |
|-------------|-----|------------------------|--------------------|-----------|-------------|---------|
| Case 1 | 57 | LUTS | TURP | STUMP | 3 | NED |
| Case 2 | 89 | LUTS | Open prostatectomy | STUMP | 1.8 | NED |
| Case 3 | 58 | LUTS | TURP | STUMP | 0.7 | NED |

LUTS: lower urinary tract symptoms; STUMP: stromal tumor of uncertain malignant potential; NED: no evidence of disease; TURP: transurethral resection of prostate

consecutive pathology reports with a diagnosis of BPH after transurethral resection of prostate (TURP) or prostatectomy were identified from March 21, 2009 to March 20, 2014 through a computer database search. Hematoxylin and Eosin stained sections were available in each case. With a focus on the stromal components, all slides were independently reviewed by a pathologist while blinded to the clinical outcomes. The following histologic features were assessed in the stromal components: cellularity, cell shape, nuclear atypia, mitotic figures, necrosis, and stromal overgrowth. Cellularity was judged to be normal, increased, or markedly increased based on comparison to non-lesional prostate stroma. Nuclear atypia was recognized in specimens showing nuclear enlargement, pleomorphism, hyperchromasia, or irregularity of chromatin pattern. Patients were diagnosed with prostatic STUMP if they exhibited one of this histological patterns or a mixture of them described by Guadin, et al.¹¹

The clinical information and follow-up were obtained from the medical records and by contacting the referring urologist in each case with final diagnostic of prostatic STUMP.

Results

A total of 702 consecutive patients with pathologic reports of BPH after TURP or prostatectomy in a 5-year period were identified. Of these, three (0.43%) received a diagnosis of prostatic STUMP on the basis of histological findings, and 699 (99.57%) cases truly diagnosed as BPH. Table 1 lists the characteristics and clinical courses of these three histologically confirmed cases of prostatic STUMP.

In these three cases, histological examination revealed hypercellular

stroma infiltrating between hyperplastic glands. The cells showed some degree of pleomorphism, nuclei with vesicular chromatin and few mitotic figures, consistent with pattern 1 and 2 of prostatic STUMP (Figures 1 and 2). The immunohistochemical study on these prostatic specimens revealed immunoreactivity for CD34 and progesterone receptor and negativity for S100, smooth muscle actin, desmin and keratin. The patients' follow up ranged from 0.7 to 3 years, but none of them reported recurrence.

Discussion

Prostatic STUMP is a newly described entity that encompasses a broad spectrum of histological patterns and clinical behaviors. Unfortunately, owing to the rarity of these lesions, only a limited number of studies have been performed that address the clinical and histological features associated with these lesions. However, it is a tumor with high incidence of recurrence, as well as progression and malignant potential.^{2,11} STUMP represents a diagnostically challenging entity and mimic BPH, clinically and histologically. In our series of 702 consecutive cases, in which a diagnosis of BPH was made on the base of histological findings, the prevalence of prostatic stump was 0.43% (3/702 subjects). These findings are similar to those we expected to be, regarding the previous studies and reported cases. Our patients' age range was 57 – 89 years, with a mean age of 73 years. Besides, there has been no evidence of recurrence, progression of the disease or metastasis for our patients after TURP or prostatectomy with follow-up ranging from 0.7 to 3 years.

Since 1998, there have been only a few published large case series on prostatic STUMP.^{2,3,11} Guadin, et al.¹¹ based on the degree

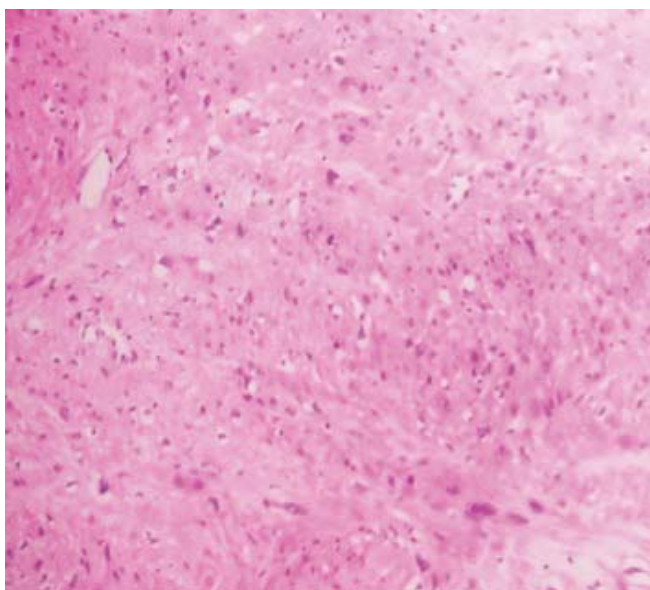


Figure 1. Stromal overgrowth with scattered atypical pleomorphic cells, H&E, X250.

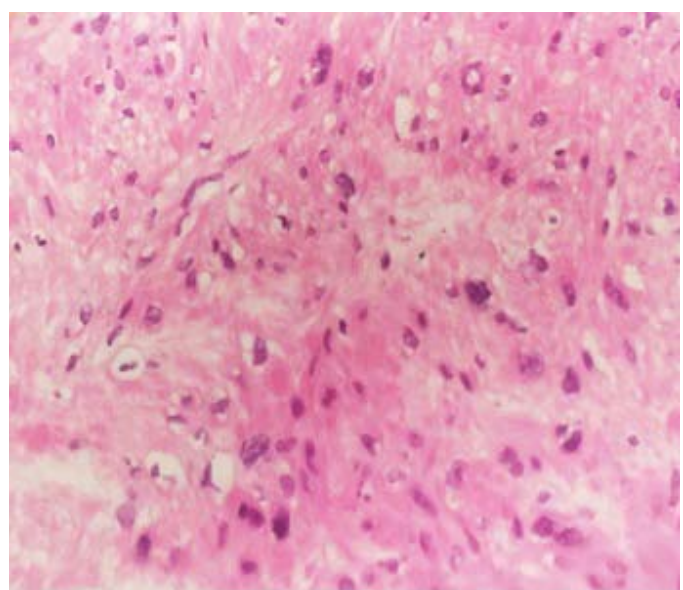


Figure 2. Scattered stromal cell with a high Nucleo to cytoplasmic ratio and nuclear pleomorphism, H&E, X400.

of stromal cellularity and the presence of mitotic figures, necrosis, and stromal overgrowth, classified them into two groups: cases with prostatic STUMP and those with prostatic stromal sarcoma. Patients ranged in age from 25 to 86 years; mean age was 54 years, and peak incidence was in the sixth and seventh decades. Researchers reported a recurrence rate of 46% in patients who didn't undergo definitive local therapy at the time of diagnosis.

In 2004, Bostwick, et al.³ studied a large series of phyllodes tumors. In this study, the patients' age range was 25 to 86 years (mean 55) that usually presented with urinary obstructive symptoms and hematuria. The researchers analyzed five histological features, including cellularity, cytologic atypia, the number of mitotic figures per 10 high power fields, the stroma-to-epithelial ratio and necrosis. Accordingly, they sub-grouped their cases into low, intermediate and high-grade tumors. Local recurrence, distant metastasis and dedifferentiation into stromal sarcoma have been reported.

In 2006, Herawi and Epstein⁷ analyzed clinicopathologic features of 50 cases with specialized stromal tumors of the prostate with particular regard to their prognosis. Patients ranged in age from 27 to 83 years (mean 58 years) at the time of presentation. They reported the histology pure STUMP as follows: cases composed of stroma with scattered cytologically atypical cells associated with benign glands; tumors resembling glandular-stromal hyperplasia but with hypercellular stroma; lesions with extensive myxoid stroma; and one with phyllodes pattern. Besides, the researchers found that 14% of prostate stromal tumors they analyzed were STUMPs associated with sarcoma, either concurrently or subsequently.

Considering the above mentioned studies and findings of our own work, STUMP can be readily misdiagnosed as BPH. In the past, the first pattern was often reported as BPH with atypia.¹⁴ Also, the myxoid pattern of STUMP can resemble the stromal nodules of BPH and the hypercellular pattern without atypia essentially looks like glandular-stromal BPH, yet with a greater degree of stromal cellularity. The histologic findings in favor of BPH are nodular growth of stroma with well-defined margins, presence of inflammatory cells and thick walled blood vessels.^{7,8} Also, the glandular component of STUMP may show glandular crowding, basal layer hyperplasia, and papillary infoldings, which are readily seen in BPH.^{7,13} In contrast to BPH, STUMPs are often located at the peripheral zone of the prostate and may occur in younger patients.^{7,13}

Given the variety of histological appearances of STUMP, other proliferations of the specialized prostatic stroma must be considered in the differential diagnosis. STUMP is often difficult to distinguish from low-grade prostatic stromal sarcoma by morphology, especially in cases with a preponderance of large, bizarre, and degenerative nuclei. While primary prostatic stromal sarcomas are rare, their differentiation is critical as the long-term survival in patients with stromal sarcoma is poor, with a 5-year disease-free survival of 38%.¹⁵ The presence of necrosis, atypical mitotic figures, marked hyper-cellularity, and nuclear pleomorphism without degenerative features are features of sarcoma, rather than STUMP.⁷ Sarcomatoid transformation of a high-grade prostatic adenocarcinoma may present with atypical spindle cells and may consider as a differential diagnosis of STUMP with degenerative atypia pattern. The presence of adjacent typical prostatic adenocarcinoma, combined with at least focal positivity for cytokeratins, may be helpful in separating

these two.

Other spindle cell lesions that rarely involve the prostate may enter the differential diagnosis, including inflammatory myofibroblastic tumor, solitary fibrous tumor, rhabdomyosarcoma, smooth muscle tumors, and direct extension of gastrointestinal stromal tumor from the adjacent colon.^{8,10,15}

In conclusion, although STUMP can be histologically and clinically misdiagnosed as BPH, the differences in prognosis and treatment modalities highlight the importance of rendering the correct diagnosis.

Acknowledgments

The authors would like to thank the Shiraz University of Medical Sciences, Shiraz, Iran and also Center for Development of Clinical Research of Nemazee Hospital and Dr. Nasrin Shokrpour for editorial assistance.

References

- Colombo P, Ceresoli GL, Boiocchi L, Taverna G, Grizzi F, Bertuzzi A, et al. Prostatic stromal tumor with fatal outcome in a young man: histopathological and immunohistochemical case presentation. *Rare Tumors*. 2010; 31: 2(4): e57.
- Wee HM, Ho SH, Tan PH. Recurrent prostatic stromal tumour of uncertain malignant potential (STUMP) presenting with urinary retention 6 Years after transurethral resection of prostate (TURP). *Ann Acad Med Singapore*. 2005; 34(7): 441 – 442.
- Bostwick DG, Hossain D, Qian J, Neumann RM, Yang P, Young RH, et al. Phyllodes tumor of the prostate: long-term follow-up study of 23 cases. *J Urol*. 2004; 172(3): 894 – 899.
- Klausner AP, Unger P, Fine EM. Recurrent prostatic stromal proliferation of uncertain malignant potential: a therapeutic challenge. *J Urol*. 2002; 168(4 Pt 1): 1493 – 1494.
- De Berardinis E, Busetto GM, Antonini G, Giovannone R, DiPlacido M, Magliocchia FM, et al. Incidental prostatic stromal tumor of uncertain malignant potential (STUMP): Histopathological and immunohistochemical findings. *Urologia*. 2012; 79(1): 65 – 68.
- Lee HY, Kim JJ, Ko ES, Kim SW, Lee SH, Kang HH, et al. Prostatic stromal tumor of uncertain malignant potential (STUMP) presenting with multiple lung metastasis. *Tuberc Respir Dis*. 2010; 69(4): 284 – 287.
- Herawi M, Epstein JI. Specialized stromal tumors of the prostate: A clinicopathologic study of 50 cases. *Am J Surg Pathol*. 2006; 30(6): 694 – 704.
- Hansel DE, Herawi M, Montgomery E, Epstein JI. Spindle cell lesions of the adult prostate. *Mod Pathol*. 2007; 20(1): 148 – 158.
- Sauder KJ, MacLennan GT. Phyllodes tumor of the prostate. *J Urol*. 2005; 174(6): 2373
- Murer LM, Talmon GA. Stromal tumor of uncertain malignant potential of the prostate. *Arch Pathol Lab Med*. 2014; 138(11): 1542 – 1545.
- Gaudin PB, Rosai J, Epstein JI. Sarcomas and related proliferative lesions of specialized prostatic stroma: A clinicopathologic study of 22 cases. *Am J Surg Pathol*. 1998; 22(2): 148 – 162.
- Johnson MHCarter HB. Stromal Tumor of Uncertain Malignant Potential (STUMP) With PSA > 500 ng/mL: A Case Report. *Urol Case Rep*. 2015; 3(5): 175 – 177.
- Nagar M, Epstein JI. Epithelial proliferations in prostatic stromal tumors of uncertain malignant potential (STUMP). *Am J Surg Pathol*. 2011; 35(6): 898 – 903.
- Hossain D, Meijers I, Qian J, MacLennan GT, Bostwick DG. Prostatic stromal hyperplasia with atypia: follow-up study of 18 cases. *Arch Pathol Lab Med*. 2008; 132(11): 1729 – 1733.
- Sexton WJ, Lance RE, Reyes AO, Pisters PW, Tu SM, Pisters LL. Adult prostate sarcoma: The M.D. Anderson Cancer Center Experience. *J Urol*. 2001; 166(2): 521 – 525.