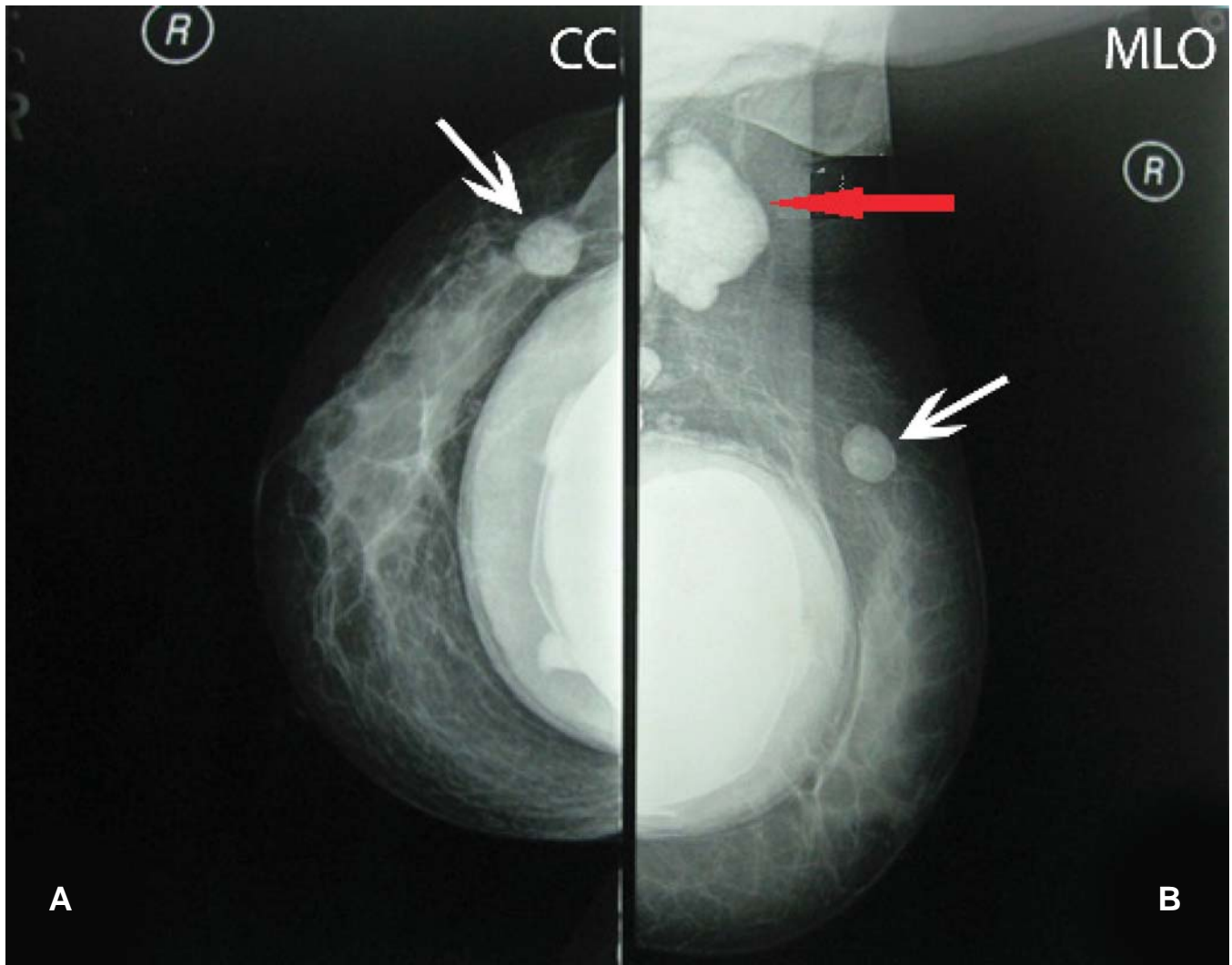


## Photoclinic



**Figure 1.** A), B) shows silicone granuloma on CC and MLO views in the mammogram. White and red arrows show silicone granuloma and reactive lymphadenopathy, respectively. Note a focus of irregular out pouching of the silicone implant margin, which suggests extra capsular implant rupture.

Cite this article as: Negahban S, Mirfazaelian H, Vahidi E, Salahshour F, Daneshbod Y. Photoclinic. *Arch Iran Med.* 2016; **19(7)**: 523 – 524.

**A** 37-year-old woman presented to the outpatient clinic with 1-month history of mass in her right breast. She had a history of augmentation mammoplasty with silicone gel implant 6 months ago, with no other significant medical or family

**Shahzad Negahban MD<sup>1</sup>, Hadi Mirfazaelian MD<sup>2</sup>, Elnaz Vahidi MD<sup>3</sup>, Faeze Salahshour MD<sup>4</sup>, Yahya Daneshbod MD<sup>1</sup>**

**Author's affiliations:** <sup>1</sup>Shiraz Molecular Pathology Research Centre, Dr. Daneshbod Laboratory, Shiraz, Iran, <sup>2</sup>Emergency Medicine Department, Imam Khomeini Hospital, Tehran University of Medical Sciences, Tehran, Iran, <sup>3</sup>Emergency Medicine Department, Dr. Shariati Hospital, Tehran University of Medical Sciences, Tehran, Iran, <sup>4</sup>Radiology Department, Imam Khomeini Hospital, Tehran University of Medical Sciences, Tehran, Iran.

**Corresponding author and reprints:** Elnaz Vahidi MD, Emergency Medicine Department, Dr. Shariati Hospital, Tehran University of Medical Sciences, Tehran, Iran. Tel: +98-912-5948762, E-mail: evahidi62@yahoo.com.

Accepted for publication: 11 May 2016

history. On physical examination, a small firm mass was found in upper outer quadrant (UOQ) of the right breast, with mild pain on palpation. On craniocaudal (CC) and mediolateral oblique (MLO) views of mammogram, a small, well-defined, round, and relatively dense mass was found in UOQ of right breast along with enlarged dense ipsilateral axillary lymphadenopathy. There was also subpectoral silicone implantation. There was a focus of irregular, out pouching of the implant margin in right side, which suggests extra capsular implant rupture (Figure 1). A biopsy of the mass was performed.

**What is your diagnosis?  
See the next page for diagnosis**

**Photoclinic Diagnosis:****Silicone Granuloma**

Injectable silicone has been utilized for breast tissue augmentation for more than five decades. Nowadays the use of silicone for soft tissue augmentation has become controversial due to the complications reported with its usage. The most commonly observed complications are granuloma formation and migration. Silicone rupture is also reported as silicone injection's complication, but it is rare. Critics argue that the complications associated with silicone implant are frequent enough to make it unacceptable for cosmetic purposes. Here, authors report one patient with silicone granuloma following breast silicone injection.

Silicone granuloma or siliconoma is a foreign body reaction caused by the capsule surrounding the implant.<sup>1</sup> There are many studies in the literature reporting SG as a complication of silicone insertion anywhere along the body. The main cause of developing this reaction is not clear, as several theories (e.g. industrial grade products, large volume injections and poor techniques) have been mentioned regarding the SG formation.

While the most common presentation is the nodule formation detected by patients, there are many modalities, which can help physicians in diagnosis, including: X-rays, ultrasound, magnetic resonance imaging (MRI) and biopsy.<sup>2</sup>

It is important to differentiate patients with simple SG with other diagnosis. For example, SG can mimic all presentations of breast

cancer in radiographs or even physical examinations. The best treatment would be silicone excision.

**Author's Contribution**

*All authors made an individual contribution to the writing of the article, including: conception and design, acquisition of data or analysis, and interpretation of data; drafting the article or revising it critically for important intellectual content; final approval of the version published.*

**Competing interests:** *None declared.*

**Patient consent:** *Obtained.*

**References**

1. Woodard BH, Rosenberg SI, Farnham R, Adams DO. Incidence and nature of primary granulomatous inflammation in surgically removed material. *Am J Surg Pathol.* 1999; 6(2): 119 – 129.
2. Travis WD, Balogh K, Abraham JL. Silicone granulomas: Report of three cases and review of the literature. *Hum Pathol.* 1985; 16(1): 19 – 27.