

Original Article

A Novel Nonsense Mutation in Exon 5 of *KIND1* Gene in an Iranian Family with Kindler Syndrome

Mohammad Mehdi Heidari PhD¹, Mehri Khatami PhD¹, Saeed Kargar MD², Mojdeh Azari MSc¹, Hassan Hosseinzadeh MSc¹, Hamideh Fallah MSc¹

Abstract

Background: Kindler syndrome (KS) is an autosomal recessive skin disease characterized by actual blistering, photosensitivity and a progressive poikiloderma. The disorder results from rare mutations in the *KIND1* gene. This gene contains 15 exons and expresses two kindlin-1 isoforms.

Objective: The aim of this investigation was to analyze mutations in the exons 1 to 15 of *KIND1* gene in an Iranian family clinically affected with Kindler syndrome.

Methods: The mutations analysis of 15 coding exons of *KIND1* gene was performed with PCR-SSCP and direct sequencing in 14 subjects from one Iranian family clinically affected with Kindler syndrome.

Results: We identified eight new nucleotide changes in *KIND1* in this family. These changes were found in g.3892delA, g.3951T>C, g.3962T>G, g.4190G>T, g.7497G>A, g.11076T>C, g.11102C>T and g.13177C>T positions. Among them, the g.13177C>T mutation resulting in the formation of a premature stop codon (Q226X) was detected only in seven affected family individuals as homozygous but was not present in 100 unrelated healthy controls.

Conclusions: This study suggests that nonsense mutation may lead to incomplete and non-functional protein products and is pathogenic and has meaningful implications for the diagnosis of patients with Kindler syndrome.

Keywords: Kindler syndrome, *KIND1* gene, mutation, PCR-SSCP

Cite this article as: Heidari MM, Khatami M, Kargar S, Azari M, Hosseinzadeh H, Fallah H. A Novel Nonsense Mutation in Exon 5 of *KIND1* Gene in an Iranian Family with Kindler Syndrome. *Arch Iran Med.* 2016; **19**(6): 403 – 408.

Introduction

Kindler Syndrome (KS) is an autosomal recessive genodermatosis (OMIM 173650).¹ The main characteristics in infancy are acral trauma induced blistering and photosensitivity that improves with age. Telangiectases, progressive poikiloderma with diffuse cutaneous atrophy and reticulate pigmentation develop during in life. Other clinical manifestations may include ectropion formation of the eyelids, chronic inflammation of the oral mucosa, nail dystrophy, webbing of fingers and toes, and anal, esophageal, urethral, or vaginal stenosis.²

The molecular basis of KS is loss of function mutations in the *KIND1* gene, encoding for the 677–amino acid protein kindlin-1 that is located on chromosome 20p12.3.^{3,4} To date, more than 60 different mutations have been described in this gene.⁵⁻⁷ Four functional domains are found in the kindlin-1 protein that have homologies to other polypeptides. The C-terminal and the N-terminal domains have homology with talin and filopodin, respectively. These domains are considered components in the linkage of the actin cytoskeleton to the extracellular matrix and as such, are proposed to have both structural and cell-signaling functions.^{4,8} Therefore, the kindlin-1 protein has structural functions, including cell differentiation, normal cell growth, directing cell migration, and signal transduction.⁹⁻¹¹ Two kindlin-1 isoforms are expressed

in these cells, namely the full length 74 kDa kindlin-1 protein and a shorter 43 kDa isoform.^{12,13} Some KS patients may have severe gastrointestinal symptoms, resembling ulcerative colitis.¹⁴ Previous studies suggest that these patients harbor pathogenic *KIND1* mutations in the shorter kindlin-1 isoform that is encoded by exons 2–7.¹⁵ In the present study, we searched for mutations in 15 coding exons of *KIND1* gene in an Iranian KS family.

Materials and Methods

Patients

In this study, seven patients and seven non-affected subjects from one family with KS were studied (Figure 1). The clinical diagnosis of KS was made based on physical examination and endoscopy analysis (Table 1). All study participants or their parents completed a questionnaire and signed an informed consent.

A 31-year-old Iranian man (proband), born of consanguineous parents, developed acral blistering during infancy, which appeared spontaneously or after trauma, followed by progressive skin atrophy and poikiloderma.

Molecular Analysis

Following approval by the local Ethics Committee of Yazd University, DNA samples from seven affected and seven non-affected family members and 100 unrelated healthy controls were genotyped by PCR (Polymerase chain reaction-single strand conformation polymorphism) amplification of genomic DNA was performed using 15 pairs of primers, scanning the coding 15 exons of *KIND1* gene (Table 2). PCR amplification was performed in a final volume of 25 µL containing 100 ng total DNA as a template,

Authors' affiliations: ¹Department of Biology, Faculty of Science, Yazd University, Yazd, Iran. ²Department of Surgery, Shahid Sadoughi Hospital, Shahid Sadoughi University of Medical Sciences and Health Services, Yazd, Iran

•**Corresponding author and reprints:** Mohammad Mehdi Heidari PhD, Department of Biology, Faculty of Science, Yazd University, Yazd, Iran. Tel: +98-35-31233381; Fax: +98-35-38210644, E-mail: Heidarimm@yazd.ac.ir
Accepted for publication: 13 April 2016

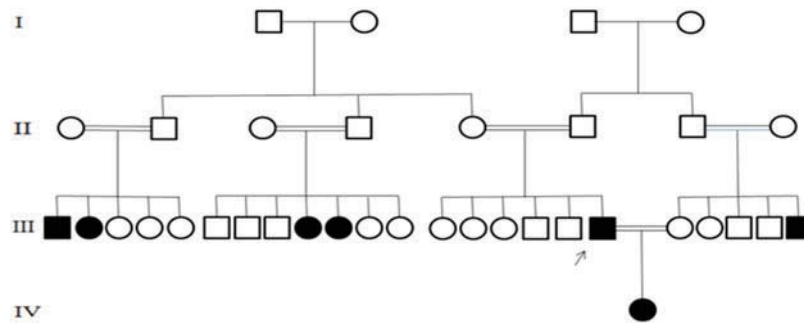


Figure 1. The pedigrees of Iranian Kindler syndrome family.

Table 1. Clinical characteristics of seven affected family members with Kindler syndrome.

Subject	Gender/ Age	Blistering	Skin atrophy	Poikiloderma	Photosensitivity	Dental problem	Gastrointestinal problem
III1	Male/32	Blistering at birth	Skin atrophy particularly on dorsal aspects of the hand and feet	Progressive poikiloderma affecting the neck, face, knee, elbow	Present	Sever gingivitis	Urethral stenosis, dysphagia and sever constipation
III2	Female/25	Blistering at birth appeared spontaneously or after trauma	Dystrophic nails	Progressive poikiloderma affecting the neck, face, knee, elbow	Present	No dental problem	Dysphagia from 10 years old, constipation
III9	Female/22	Blistering at 1 years	Not document	Present	Present	Not document	Dysphagia
III10	Female/26	Blistering at birth	Not document	Present	Present	Widespread with macules in the buccal mucosa	Not document
III18	Male/31	Developed acral blistering during infancy	Progressive skin atrophy	Progressive poikiloderma affecting the neck, face, knee, elbow	Present	Gingival bleeding and atrophy and loss of teeth	Progressive dysphagia, urethral stenosis, constipation
III23	Male/ 18	Blistering at birth	Not document	Present	Present	No dental problem	Not document
IV1	Female/7	Blistering at birth	Not document	Present	Present	Not document	Not document

0.5 μ L each primers (10 pmol), 0.8 μ L $MgCl_2$, 0.5 μ L of dNTP, 2.5 μ L of 10X PCR buffer and 2 units Taq DNA polymerase. PCR was performed under following conditions: initial denaturation at 94°C for 5 min; followed by 35 cycles including denaturation at 94°C for 30 s, annealing according to Table 2 for each exon in 40 s, and extension at 72°C for 1 min; and a final extension at 72°C for 5 min. The PCR products were electrophoresed on 1.5% agarose gel and stained with ethidium bromide. SSCP method was used to screen for mutations. For this analysis, 6 μ L of PCR products were mixed with 9 μ L of SSCP loading dye. The samples were denatured at 94°C for 10 min and cooled on ice. The fragments showed abnormal migration to elucidate the type of mutation, samples with different band were sent for direct sequencing (Figure 2). The control samples were selected from 100 unrelated, ethnically normal controls.

Results

Mutation analysis of the 15 coding exons and of the exon-intron boundaries of *KIND1* gene in 14 family members was performed by PCR-SSCP analysis and direct sequencing. DNA fragments showing abnormal banding patterns on SSCP analyses were sequenced to identify the exact mutations (Figure 2).

These nucleotide changes include two novel intronic variants: g.3892delA, g.3951T>C, located in -99 and -40 of starting of exon 2 respectively, a reported intronic change, g.3962T>G found in -29 of exon 2, g.4190G>T located 49 nucleotides upstream of exon 2, g.7497G>A located 4 nucleotides upstream of the exon 3 and g.11076T>C and g.11102C>T located in -9 and -35 of the start of exon 4, respectively. Also, we found a homozygous g.13177C>T mutation that leads to premature stop codons (Q226X) in exon 5 of the *KIND1* gene in proband and six affected family individuals.

The proband developed photosensitivity since the age of 3 and suffered from gingival bleeding and atrophy and loss of teeth, his nails were dystrophic, he had excessive sweating and ictuses. He suffered from progressive dysphagia since 10 years old and urethral stenosis and he complained of constipation for 5 years that was associated with rectorrhagia due to grade 3 hemorrhoids, for which he underwent dysphagia balloon dilatation at 30 years of age. He was married to his unaffected cousin who had an affected brother with similar symptoms. Their 7-year-old daughter has skin symptoms like her father and developed skin blistering 3 days after birth and recently suffered from dysphagia. Also, the proband has 4 affected cousin with similar symptoms including congenital blistering, progressive poikiloderma, and photosensi-

Table 2. PCR primers and conditions.

Fragment	Primer sequence(5'-3')	Tm (°C)	Amplicon size (bp)
Exon 1	F: CTTCGCCAGCGCCCGCTC R:GTTTATTTTGGGCCAGATG	61	293
Exon 2	F:ATATCTGGAGCACCTGGAAC R:ATTGCTCTCCAGGGCATTAC	57	417
Exon 3	F:TCGCACACAATGAAATTGACTC R: AAGAGTCTACAGGGCACAGG	57	364
Exon 4	F:GACCCCTGAGTCTTAGAAGGA R:GCCTTTCCTCATCACATCAG	60	343
Exon 5	F:CCTGGATTCTCATATCATAG R:GAAACGTGACATCCCATCTC	58	328
Exon 6	F: TTTCTAGTTGGCTAGACTCCTC R: GTTGCTTACTTTAGGATTCAAG	60	119
Exon 7	F: GCCTCAGTTGTTTCAGAATC R: TTGGTTGTCTCCTTCCAGAG	62	232
Exon 8	F: ATACCTCATTACACACACAC R: TATGAAACTTCAAGCAGAAC	54	214
Exon 9	F: ATCACTTATGAAGTTCCTGC R: TAAACTCCTGCACCTTTATC	56	169
Exon 10	F: GCGTGTCCACATTTCTGGG R: TTACGATGAGCCACAGCAAG	59	199
Exon 11	F:ACACCTGATGTTTATTAACAG R: CTTAGTGGAGGTGAAGTGAC	59	216
Exon 12	F: GAGCTTGCTTCTCAACCTTC R:CAAACAATTGCCCTAACAAAG	57	285
Exon 13	F: CTGGAGCTAACAGGGTGATC R: AATGAGAAAAGTGGGGCTCC	59	273
Exon 14	F:TTGTATTATAGGAAGCAGTTG R: AGGGACACACATTTATAGGC	56	228
Exon 15	F: CCATCTGTTATCCACCTCAGC R: CCAGCGGTGAATGTATGTTG	60	409

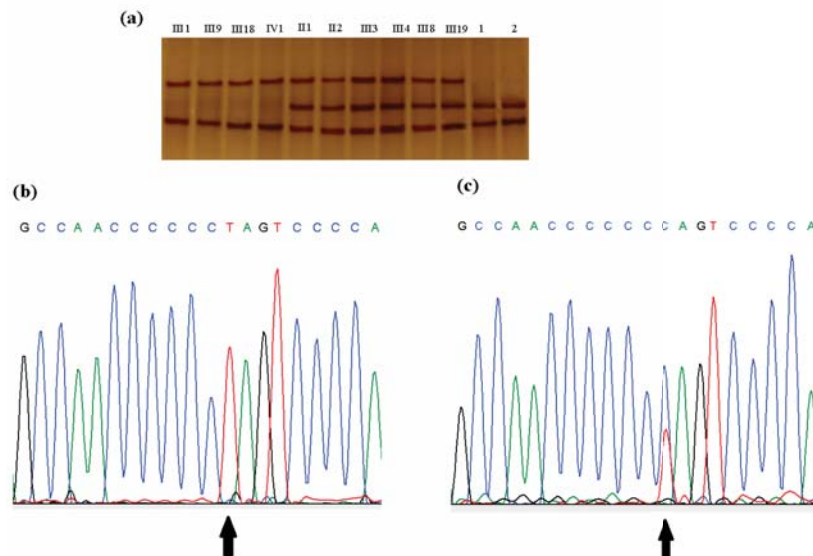


Figure 2. Single-strand conformation polymorphism (SSCP) analysis of exon 5 and DNA sequence analysis. **(a)** SSCP analysis of exon 5: Lanes III-1, III-9, III-18 and IV-1 represents g.13177 TT (homozygous state); lanes II-1, II-2, III-4, III-4, III-18 and III-19 represent normal related individuals (g.13177 CT) (heterozygous state); lanes 1 and 2 show normal g.13177 CC (homozygous). **(b)** Sequence electropherogram from a homozygous patient (IV-1). **(c)** Sequence electropherogram from a heterozygous parent (III-19).

tivity, who are born of consanguineous parents.

Using homology searches through protein databases (www.expasy.org/) and functional domains in kindlin-1 protein, g.13177C>T mutation is predicted to cause loss of the FERM and PH domains of the protein. This mutation is localized in the F1 segment of FERM and PH domains and would lead to protein truncation.

Discussion

KS is a skin disease characterized by atrophy of the epidermis and followed by blistering of the epidermis, skin pigmentation disorders and skin cancer.¹⁶ Several studies show that KS may not only involve the skin but also most KS patients suffer from gastrointestinal disorders.^{10,12}




Figure 3. The wild-type Kindlin-1 protein sequence and its domains structure (panel A) and nonsense (Q226X) mutant form ((panel B).

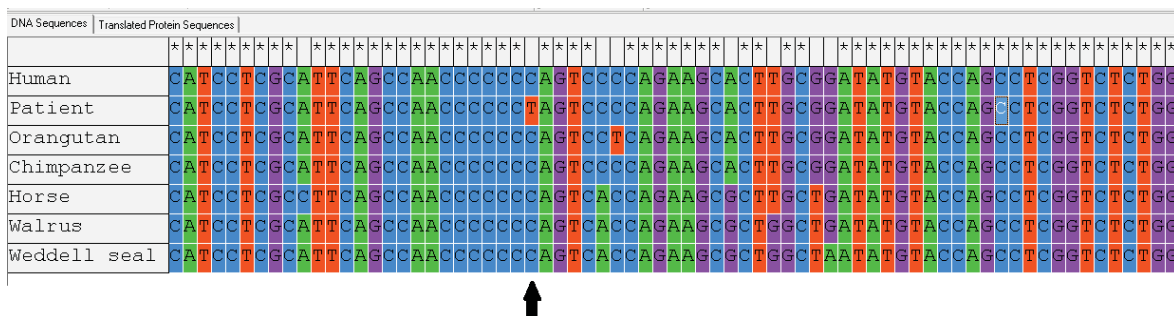


Figure 4. Multiple sequence alignment of g.13177 C>T in *KIND1* gene of human with other species. The arrow shows the site of mutation.

Mutation analysis by Sadler *et al.* in exon 2 of the *KIND1* gene of KS patients revealed a homozygous status for the novel mutation 20/21delTT resulting in a preterminal stop codon creating a non-functional peptide 17 amino acids in length.¹⁷ Arita *et al.* showed that kindlin-1 in the patient’s skin was completely absent by immunostaining technique. They found a homozygous splice-site mutation at the -6 position (IVS9-6T>A).¹⁸

All patients described here had severe gastrointestinal tract involvement such as dysphagia. To the best of our knowledge, there is a possible link between intestinal pathology in KS and

mutations present within 15 coding exons of *KIND1* gene.¹⁴ In our study, we detected seven nucleotide variations in introns 1, 2, 3 and 4 of *KIND1* gene in the Iranian KS syndrome. The effect of these SNPs on intron splicing and KS or function has yet to be tested.

A homozygous sequence variant C- to -T at position 676 in exon 5 (g.13177C>T) resulting in the codon 226 CAG for Glutamine change to TAG, stop codon (Q226X) were found in seven patients. This mutation was found to be homozygous in the proband and heterozygous in his normal wife while it was homozygous in

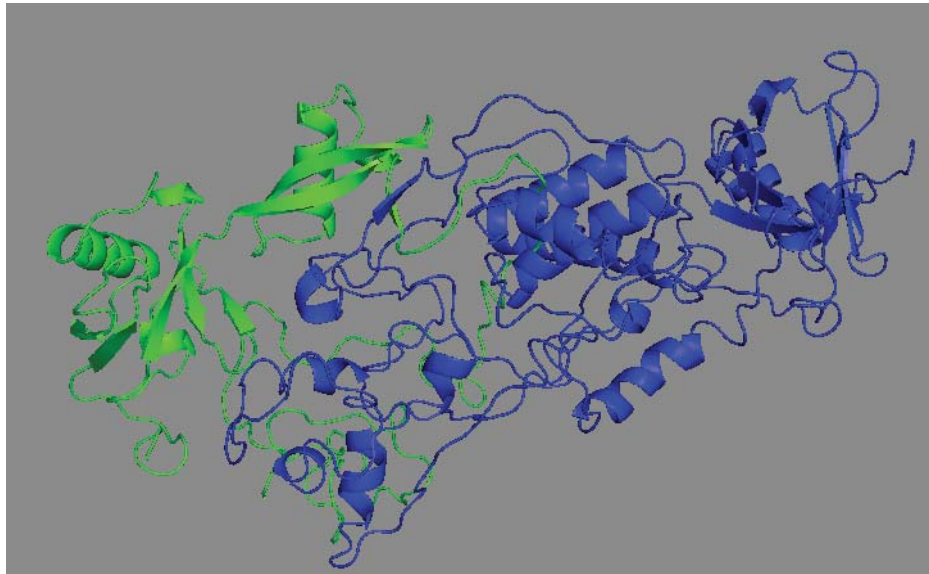


Figure 5. Molecular model of human Kindlin-1 protein with Protein Model Portal (PMP) server and visualizing with PyMol software. Green segment shows N-terminal of protein and blue segment shows C-terminal of protein that are lost with nonsense mutation (Q226X).

their child. The novel nonsense mutation Q226X results in a truncated protein with loss of the FERM (filopodin and ezrin/radixin/moesin) and PH (pleckstrin homology) domains in the kindlin-1 protein and consequently impairs the function of the protein (Figure 3). This mutation is conserved during the evolution and is located in a structurally/functionally important region (Figure 4). As the crystal structure of kindlin-1 protein has not been solved yet, we used Protein Model Portal (PMP) server (<http://www.protein-modelportal.org/>) for a three-dimensional structure model prediction of kindlin-1 protein. Using PyMol software, the effect of this nonsense mutation was evaluated (Figure 5). This mutation was not present in 100 unrelated healthy controls.

In conclusion, our results and previously published data suggest that the identification of new mutations and their associated phenotypes is very important to predict disease prognosis, clarify their clinical importance, and to provide better genetic counseling for affected families.

Acknowledgments

The authors would like to thank of Research Council Yazd University, IUT Research Council for financial support of this research. We thank the Kindler syndrome family for their participation in this scientific research. The study was approved by Human Research Ethics Committee of Yazd University.

Conflict of interest: None declared

Reference

1. Siegel DH, Ashton GH, Penagos HG, Lee JV, Feiler HS, Wilhelmson KC, et al. Loss of kindlin-1, a human homolog of the *Caenorhabditis elegans* actin-extracellular-matrix linker protein UNC-112, causes Kindler syndrome. *Am J Hum Genet.* 2003; 73(1): 174 – 187.
2. Fischer IA, Kazandjieva J, Vassileva S, Dourmishev A. Kindler syndrome: a case report and proposal for clinical diagnostic criteria. *Acta Dermatovenereol Alp Panonica Adriat.* 2005; 14(2): 61 – 67.
3. Lai-Cheong JE, Parsons M, Tanaka A, Ussar S, South AP, Gomathy S, et al. Loss-of-function FERMT1 mutations in kindler syndrome implicate a role for fermitin family homolog-1 in integrin activation. *Am J Pathol.* 2009; 175(4): 1431 – 1441.
4. Meves A, Stremmel C, Gottschalk K, Fassler R. The Kindlin protein family: new members to the club of focal adhesion proteins. *Trends Cell Biol.* 2009; 19(10): 504 – 513.
5. Techanukul T, Sethuraman G, Zlotogorski A, Horev L, Macarov M, Trainer A, et al. Novel and recurrent FERMT1 gene mutations in Kindler syndrome. *Acta Derm Venereol.* 2011; 91(3): 267 – 270.
6. Has C, Yordanova I, Balabanova M, Kazandjieva J, Herz C, Kohlhase J, et al. A novel large FERMT1 (KIND1) gene deletion in Kindler syndrome. *J Dermatol Sci.* 2008; 52(3): 209 – 212.
7. Has C, Castiglia D, del Rio M, Diez MG, Piccinni E, Kiritsi D, et al. Kindler syndrome: extension of FERMT1 mutational spectrum and natural history. *Hum Mutat.* 2011; 32(11): 1204 – 1212.
8. Lai-Cheong JE, Ussar S, Arita K, Hart IR, McGrath JA. Colocalization of kindlin-1, kindlin-2, and migfilin at keratinocyte focal adhesion and relevance to the pathophysiology of Kindler syndrome. *J Invest Dermatol.* 2008; 128(9): 2156 – 2165.
9. Herz C, Aumailley M, Schulte C, Schlotzer-Schrehardt U, Bruckner-Tuderman L, Has C. Kindlin-1 is a phosphoprotein involved in regulation of polarity, proliferation, and motility of epidermal keratinocytes. *J Biol Chem.* 2006; 281(47): 36082 – 36090.
10. Ussar S, Moser M, Widmaier M, Roggoni E, Harrer C, Genzel-Boroviczeny O, et al. Loss of Kindlin-1 causes skin atrophy and lethal neonatal intestinal epithelial dysfunction. *PLoS Genet.* 2008; 4(12): e1000289.
11. Kern JS, Herz C, Haan E, Moore D, Nottelmann S, von Lilien T, et al. Chronic colitis due to an epithelial barrier defect: the role of kindlin-1 isoforms. *J Pathol.* 2007; 213(4): 462 – 4670.
12. Lai-Cheong JE, Parsons M, McGrath JA. The role of kindlins in cell biology and relevance to human disease. *Int J Biochem Cell Biol.* 2010; 42(5): 595 – 603.
13. Natsuga K, Nishie W, Shinkuma S, Nakamura H, Matsushima Y, Tatsuta A, et al. Expression of exon-8-skipped kindlin-1 does not compensate for defects of Kindler syndrome. *J Dermatol Sci.* 2011; 61(1): 38 – 44.
14. Mansur AT, Elcioglu NH, Aydingoz IE, Akkaya AD, Serdar ZA, Herz C, et al. Novel and recurrent KIND1 mutations in two patients with Kindler syndrome and severe mucosal involvement. *Acta Derm Venereol.* 2007; 87(6): 563 – 565.
15. Burch JM, Fasshi H, Jones CA, Mengshol SC, Fitzpatrick JE, McGrath JA. Kindler syndrome: a new mutation and new diagnostic possibilities. *Arch Dermatol.* 2006; 142(5): 620 – 624.

16. Ashton GH, McLean WH, South AP, Oyama N, Smith FJ, Al-Suwaid R, et al. Recurrent mutations in kindlin-1, a novel keratinocyte focal contact protein, in the autosomal recessive skin fragility and photosensitivity disorder, Kindler syndrome. *J Invest Dermatol.* 2004; 122(1): 78 – 83.
17. Sadler E, Klausegger A, Muss W, Deinsberger U, Pohla-Gubo G, Laimer M, et al. Novel *KIND1* gene mutation in Kindler syndrome with severe gastrointestinal tract involvement. *Arch Dermatol.* 2006; 142(12): 1619 – 1624.
18. Arita K, Wessagowit V, Inamadar AC, Palit A, Fassihi H, Lai-Cheong JE, et al. Unusual molecular findings in Kindler syndrome. *Br J Dermatol.* 2007; 157(6): 1252 – 1256.