

Case Report

A Clone with 5, 17 and 18 Monosomies as Stemline in a Patient with *De novo* Acute Myeloid Leukemia

Davood Zare-Abdollahi PhD¹, Abolfazl Movafagh PhD¹, Shamsi Safari MSc¹, Mir Davood Omrani PhD^{1*}

Abstract

In brief, we present a case of acute myeloid leukemia (AML) with 5, 17 and 18 monosomies as stemline clonal abnormality in his cytogenetic analysis. To the best of our knowledge, this is the first report of such a chromosomal abnormality as a clonal aberration in AML with M0 French-American-British (FAB) type. It seems that this monosomal karyotype imposed adverse prognosis on this patient and could be related to the rapid and malignant course of the disease as seen.

Keywords: Acute myeloid leukemia (AML), karyotype, monosomy, stemline

Cite this article as: Zare-Abdollahi D, Movafagh A, Safari S, Omrani MD. A clone with 5, 17 and 18 monosomies as stemline in a patient with *de novo* acute myeloid leukemia. *Arch Iran Med.* 2016; **19**(5): 379 – 380.

Introduction

The cytogenetic classification of patients with AML is based either on the clonal number of chromosomes or the specific cytogenetic abnormalities acquired by the leukemic cells. Although monosomy 5 has been observed as a recurrent chromosomal abnormality in *de novo* AML, it occurs with greater frequency in secondary AML arising from precedent myelodysplastic syndrome (MDS-AML) or due to genotoxic therapy for a previous malignancy (therapy related-AML). With the reported frequency of about 2% in adult AML aged 16 – 59.^{1,2} and 3% – 5% in older patients with AML,³ monosomy 5 regarded as one of the most numerical chromosomal changes in AML, surpassed in frequency only by +8, -7, +21 and -Y. Monosomy 5 is most often present together with other abnormalities and only few cases with monosomy 5 as single change have been reported.

Case Report

In this report, we present a 79-year-old male who had been suffering from weakness, anorexia and mild fever for two months. On physical examination, he showed severe pallor, slight dehydration and a large soft abdomen and without tenderness. Blood analysis showed: Hb 8.1 g/dL, WBC 32,600/ μ L (60% blasts), platelets 30,000/ μ L. Bone marrow aspirate showed hypercellularity with 80% of cells identified as undifferentiated myeloblasts, fulfilling the FAB criteria of M0. Cytogenetic analysis was performed on bone marrow, using overnight and 48 hours synchronized cultures. Metaphase chromosomes were G-banded and karyotyped, according to the recommendations of the International System for Human Cytogenetic Nomenclature (ISCN). Metaphases were

analyzed using Applied Spectral Imaging Case Data Manager 6.0.

Twenty cells were studied and in our analysis, we found a hypodiploid metaphase with 43 chromosomes, which leads to further explore. Finally, after 52 cells were studied, we found another 3 cells with 43 chromosomes in association with normal 46 chromosomes (Figure 1). The karyotype was defined as 43,XY,-5,-17,-18[4]/46,XY[48].

Chemotherapy was deferred and the patient was initiated on antibiotic therapy and supportive cares including red cells and platelet transfusions, as well as low-dose corticosteroid. The patient died from pulmonary infection, 8 days after admission.

Discussion

A review of the literature and the Mitelman Database of Chromosome Aberrations in Cancer⁴ showed no AML case with M0 FAB type and 43, XY, -5, -17, -18 as a stemline clonal aberration. Hirai, et al. presented two MDS-AML cases, with 44, XY, -5, -17 karyotype, previously.⁵ Recall that, there are some aberration in MDS and AML that can occur in each, as a driver and specific abnormality. For example, most patients with t(1;7)(p11;p11) have MDS at the time of diagnosis, however some of them have full-fledged AML at first.⁶ Taking in to account the widespread overlapping chromosomal abnormalities, the possibility of precedent MDS in our patient with rapid progression to AML, should not be rejected. Using the accepted definition of clonal aberration in malignancy, the loss of each of the chromosomes 5, 17 and 18 can be considered as clonal, as each was missing in at least three cells. In addition, because we could not identify any of these founded monosomies solely, it seems that malignant clone raised with these monosomies together at first. Recently Breems, et al. defined a category of monosomal karyotype positive (MK⁺) patients characterized by the presence of an autosomal monosomy in conjunction with at least one other autosomal monosomy or one structural abnormality and with poor prognosis.² In this study, in 25 patients aged 15 to 60 years and with monosomy 5, they did not find monosomy 5 as sole abnormality and hence, stratified them in MK⁺ subgroup. In addition, they emphasized on poorest

Authors' affiliations: ¹Department of Medical Genetics, Faculty of Medicine, Shahid Beheshti University of Medical Sciences, Tehran, Iran.

***Corresponding author and reprints:** Mir Davood Omrani PhD, Department Medical Genetics, Shahid Beheshti University of Medical Sciences, Tehran, Iran. Tel/ Fax: +98-21-23872572, E-mail: davood_omrani@sbumu.ac.ir, davood_omrani@yahoo.co.uk.

Accepted for publication: 14 October 2015

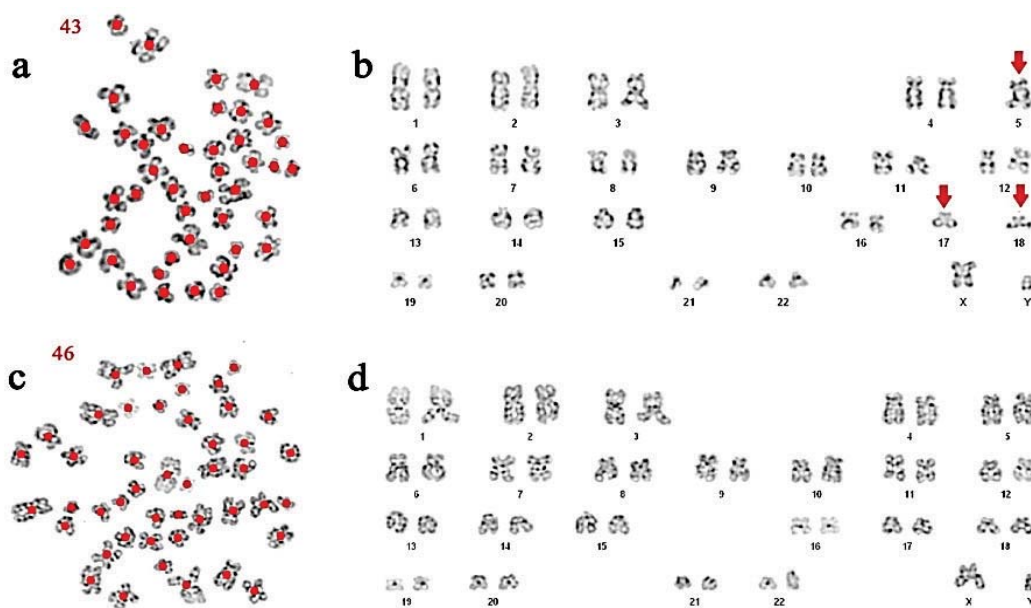


Figure 1. Bone marrow karyogram of the reported case with karyotype: 43,XY,-5,-17,-18[4]/46,XY[48].

prognosis of monosomy 5 compared to others in MK⁺ subgroup.² These results confirmed in subsequent study.³ In light of these premises, the rapid and malignant course of the disease in our case can be imposed by the adverse prognosis of his monosomal karyotype. In addition, light hypodiploid clones, seen after further cytogenetic analysis, is another remarkable thing about our case that must be kept in mind for diagnostic setting, when faced with samples of older people and M0 FAB type.

Conflict of interest: None.

Acknowledgments

We would like to thank the patient who participated in this study.

References

- Grimwade D, Hills RK, Moorman AV, Walker H, Chatters S, Goldstone AH, et al. Refinement of cytogenetic classification in acute

myeloid leukemia: determination of prognostic significance of rare recurring chromosomal abnormalities among 5876 younger adult patients treated in the United Kingdom Medical Research Council trials. *Blood.* 2010; 116(3): 354 – 365.

- Breems DA, Van Putten WL, De Greef GE, Van Zelder-Bhola SL, Gerssen-Schoorl KB, Mellink CH, et al. Monosomal karyotype in acute myeloid leukemia: a better indicator of poor prognosis than a complex karyotype. *J Clin Oncol.* 2008; 26(29): 4791 – 4797.
- Perrot A, Luquet I, Pigneux A, Mugneret F, Delaunay J, Harousseau JL, et al. Dismal prognostic value of monosomal karyotype in elderly patients with acute myeloid leukemia: a GOELAMS study of 186 patients with unfavorable cytogenetic abnormalities. *Blood.* 2011; 118(3): 679 – 685.
- Mitelman Database of Chromosome Aberrations and Gene Fusions in Cancer (2014). Mitelman F, J.B.A.M.F.E. Available from: URL: <http://cgap.nci.nih.gov/Chromosomes/Mitelman>.
- Hirai H, Okada M, Mizoguchi H, Mano H, Kobayashi Y, Nishida J, et al. Relationship between an activated N-ras oncogene and chromosomal abnormality during leukemic progression from myelodysplastic syndrome. *Blood.* 1988; 71(1): 256 – 258.
- Pedersen B. Survival of patients with t(1;7)(p11;p11). Report of two cases and review of the literature. *Cancer Genet Cytogenet.* 1992; 60(1): 53 – 59.