

## Case Report

# Left Inguinal Bladder Hernia that Causes Dilatation in the Ureter

Mustafa Ugur MD<sup>1</sup>, Nesrin Atci MD<sup>2</sup>, Cem Oruc MD<sup>1</sup>, Seckin Akkucuk MD<sup>1</sup>, Akin Aydogan MD<sup>1</sup>

## Abstract

The scrotal bladder hernia is a rare condition that may present as scrotal swelling and urinary system obstruction or infection symptoms. Diagnosis of this condition before the operation decreases the severe complications like bladder injury during operation.

In this article, a 75-year-old man presented to our clinic with right inguinal swelling and lower urinary system infection. Inguinal bladder hernia was diagnosed after performing a computed tomography. The hernia was repaired without any complications.

**Keywords:** Bladder, computed tomography, inguinal hernia

**Cite this article as:** Ugur M, Atci N, Oruc C, Akkucuk S, Aydogan A. Left inguinal bladder hernia that causes dilatation in the ureter. *Arch Iran Med.* 2016; **19**(5): 376 – 378.

## Introduction

Inguinoscrotal herniation of the bladder is a rare condition that is caused by an increased intra-abdominal pressure and a weakness of the abdominal wall. Inguinal herniation of the bladder generally affects older males and may present as a urinary system obstruction with scrotal swelling or infection signs. If these patients are not treated, complications like ureter obstruction, vesicoureteral reflux, and kidney failure may occur.<sup>1</sup>

In this article, a 75-year-old man who was diagnosed with inguinal bladder hernia presented to our clinic with urinary system infection.

## Case Report

A 75-year-old man, with pain and swelling in the left groin, and burning sensation during urination, presented to our clinic. According to the anamnesis, these symptoms started one year ago and increased gradually. During the last four months, he complained of having a burning sensation during urination and frequent urination. He also stated that he needed to void every two hours during the day and every three hours during the night. In the last two months, he had to push the swelling in left inguinal region to urinate. According to his background, he had hypertension and he was taking 160 mg valsartan. During physical examination, a 15 × 10 cm mass that was compatible with inguinal hernia was detected. After the urination the inguinal swelling seemed to be diminished. No pathological finding was observed in blood tests. Abdominal ultrasonography revealed grade 2 hydronephrosis in the left kidney and many cystic lesions. The bladder was not in its anatomical place and was detected in a hernia sac in the left

inguinal region. In abdominal CT imaging, many cystic lesions which were evaluated as simple cysts, detected in both kidneys. Grade 2 ectasia in the left kidney was detected. Dilated left ureter was proceeding in the hernia pouch and opening to the bladder in the hernia pouch (Figure 1a, 1b). An approximately 5 cm defect on the left inguinal region with a 10 × 8 cm hernia sac including bladder and fat tissue was detected (Figure 1c, 1d). In these circumstances, elective surgery was decided. Before operation, the patient was diagnosed with benign prostate hypertrophy by urology clinic. A foley catheter was applied and then the hernia sac was explored with left inguinal incision. It was seen that the bladder was herniating through the approximately 4 cm defect in the inguinal region (Figure 2). After the defect was widened, bladder has been replaced to its anatomical position. Then, the defect was repaired with number 0 prolene suture. The operation was completed after a 10 × 8 cm prolene mesh was fixed to the posterior abdominal wall. The foley catheter was taken out on the first postoperative day. The patient was discharged on postoperative fourth day without any complication.

## Discussion

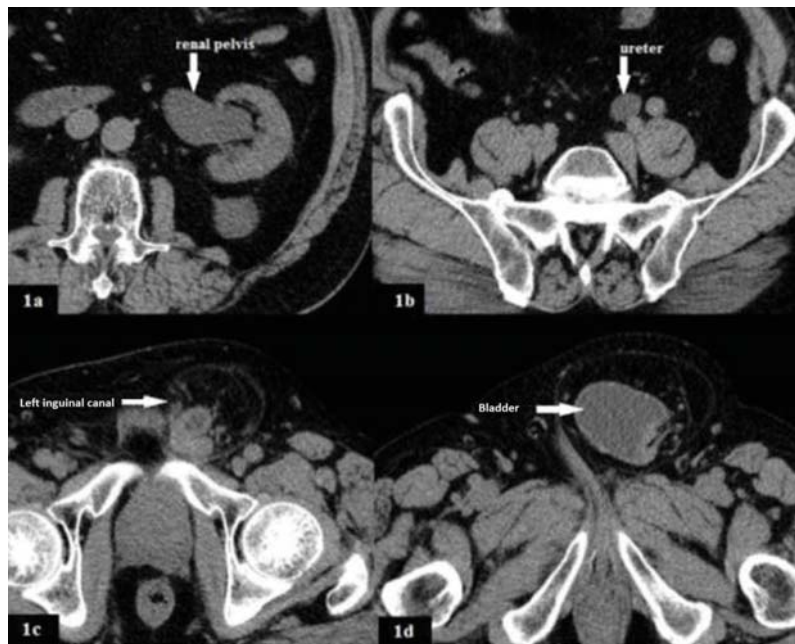
Inguinal bladder hernias occur in 1% – 4% of cases of inguinal hernias. However, its prevalence increases with age and may increase up to 10% of all inguinal hernias. Inguinal bladder hernias are more common in males and are usually seen in the right side.<sup>2</sup> Herniation of a bladder partially or totally through inguinal canal is more common than scrotum. Conditions like the bladder outlet obstruction (benign prostate hyperplasia, bladder neck strictures), sliding type direct inguinal hernia, male gender, advanced age, decreased bladder tonus, obesity and weakened abdominopelvic wall are the most known etiopathogenic factors.<sup>3</sup> In our case, the bladder hernia was observed on the left side which is very rare. Advanced age, male gender, and benign prostate hyperplasia were considered as etiopathologic factors.

In most of the cases, the hernias are asymptomatic, and sizes of them are small. Hernias are generally diagnosed during radiological studies or herniorrhaphy surgeries incidentally. However, the

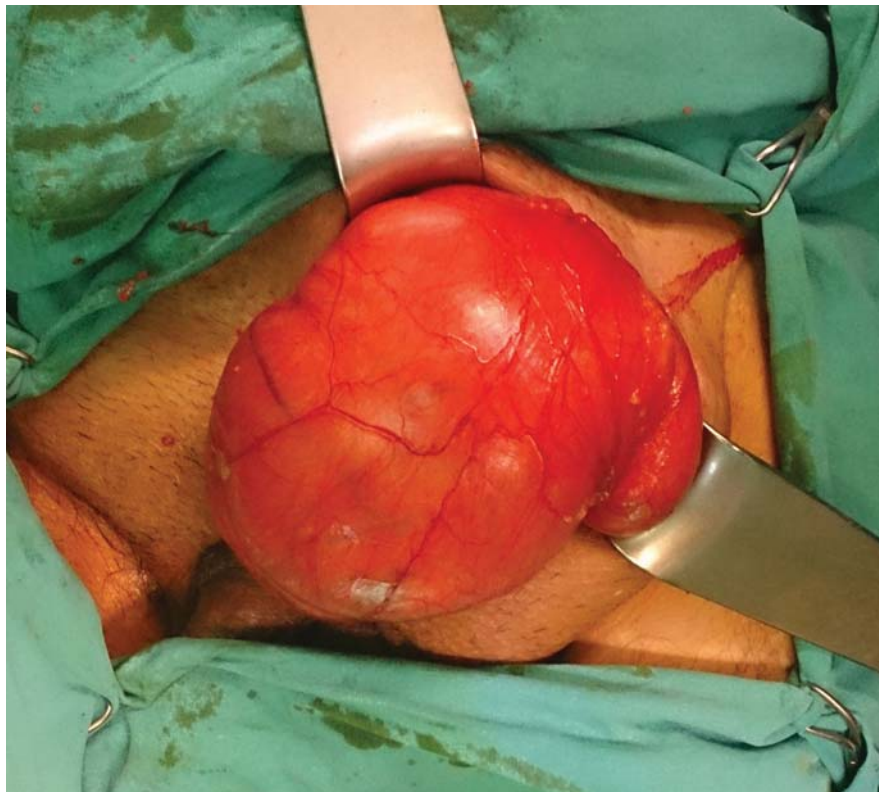
**Authors' affiliations:** <sup>1</sup>Department of General Surgery, Medicine School of Mustafa Kemal University, Hatay, Turkey, <sup>2</sup>Department of Radiology, Medicine School of Mustafa Kemal University, Hatay, Turkey.

**•Corresponding author and reprints:** Mustafa Ugur MD, Mustafa Kemal Üniversitesi, Tıp Fakültesi, Genel Cerrahi A.D. 31100, Serinyol Hatay/Turkey. Tel: +90-326 229 1000, Fax: +90-326 245 5654, Cell Phone: +90-505 3463209, E-mail: drmustafaugur@gmail.com.

Accepted for publication: 14 October 2015



**Figure 1.** The computed tomography images of bladder herniation through canalis inguinalis. **A)** Dilated left renal pelvis; **B)** Dilated left ureter; **C)** Dilated left canalis inguinalis; **D)** Bladder herniation through left canalis inguinalis.



**Figure 2.** Intraoperative view of herniated bladder

bigger hernias may cause lower urinary system symptoms, such as intermittent inguinal or scrotal swelling, pollakiuria, nocturia, urgency. In these patients, urination is completed in two steps. In the first step, patients start to urinate naturally. In the second step, patients push the swelling on their groin or scrotum to empty their bladder completely. The size of the hernias decreases after urination.<sup>3</sup>

The inguinoscrotal hernia is mainly diagnosed with the anamnesis, physical examination and radiological studies. Ultrasonography, cystography, intravenous pyelography, computed tomography

and magnetic resonance imaging are considered as radiological studies to diagnose the inguinoscrotal hernias. The computed tomography is the most valuable study that can specify the content of the hernia and show the complications due to the herniation like strangulation and hydronephrosis.<sup>4</sup> In our case, the patient presented to us with urinary system infection symptoms. He stated in his medical history that he could urinate only by pushing the swelling on his left groin. This information was the most important factor that made us to consider the bladder hernia before the

operation. We performed ultrasonography and computed tomography to confirm our diagnosis and detect possible complications. Ultrasonography revealed left inguinal bladder hernia. Computed tomography revealed that the left ureter was dilated and ended in the hernia pouch.

Inguinoscrotal bladder hernia may cause serious complications like bladder stones, vesicoureteral reflux, sepsis, obstruction of one ureter or both, renal failure, ischemia or perforation of the herniated bladder wall.<sup>5</sup> In patients with bladder hernia, the urological cancer ratio (mostly bladder cancer) is higher than the normal population.<sup>6</sup> In our case, we performed elective surgery after we had determined that there were no serious complications due to the bladder herniation.

Standard herniorrhaphy operation after reduction or resection of the bladder is suggested for inguinoscrotal bladder hernia treatment. Indications for bladder resections are necrosis on the bladder wall, and tumor or diverticula detection in the herniated bladder.<sup>3</sup> In our case, a Foley catheter was inserted into the patient preoperatively. During the operation, the diameter of the hernia neck was measured as 4 cm. There was no necrosis or any other lesion in the bladder, so resection of the bladder was not performed. The posterior abdominal wall was repaired using polypropylene mesh. In conclusion; patients at high risk of inguinoscrotal hernia must be questioned in details. Risk factors were considered to be age (> 50 years), male gender, obesity, urination in two phases, nocturia, and symptoms like pollakiuria. In the management of the inguino-

scrotal bladder hernia, abdominal computed tomography should be performed. Preoperative radiologic evaluation of the hernia sac may avoid severe complications.

### Conflict of Interest

*The authors declare that there is no conflict of interest in this study.*

### References

1. Karatzas A, Christodoulidis G, Spyridakis M, Stavaras C, Aravantinos E, Melekos M. A giant inguinoscrotal bladder hernia as a cause of chronic renal failure: A rare case. *Int J Surg Case Rep.* 2013; 4(3): 345 – 347.
2. Bisharat M, O'Donnell ME, Thompson T, MacKenzie N, Kirkpatrick D, Spence RA, et al. Complications of inguinoscrotal bladder hernias: a case series. *Hernia.* 2009; 13(1): 81 – 84.
3. Moufid K, Touiti D, Mohamed L. Inguinal bladder hernia: four case analyses. *Rev Urol.* 2013; 15(1): 32 – 36.
4. Kim KH, Kim MU, Jeong WJ, Lee YS, Kim KH, Park KK, et al. Incidentally detected inguinoscrotal bladder hernia. *Korean J Urol.* 2011; 52(1): 71 – 73.
5. Westera J, Meyer J, Reynolds J, Lambrianides A. Massive inguinoscrotal bladder hernia. *J Surg Case Rep.* 2012; 5: 5.
6. Oruç MT, Akbulut Z, Ozozan O, Coşkun F. Urological findings in inguinal hernias: a case report and review of the literature. *Hernia.* 2004; 8(1): 76 – 79.