

Original Article

Repeated Intraportal Injection of Mesenchymal Stem Cells in Combination with Pioglitazone in Patients with Compensated Cirrhosis: A Clinical Report of Two Cases

Massoud Vosough MD PhD^{1,#}, Shirin Moossavi MD MSc^{2,3,#}, Soura Mardpour MSc¹, Shahram Akhlaghpour MD⁴, Vajiheh Azimian MSc¹, Neda Jarughi MSc¹, Seyedeh-Esmat Hosseini BSc¹, Mandana Ashrafi MD^{2,3}, Sepideh Nikfam MD^{2,3}, Nasser Aghdami MD PhD¹, Reza Malekzadeh MD^{2,3}, Mehdi Mohamadnejad MD^{2,3}, Hossein Baharvand PhD¹

Abstract

Background: Transplantation of mesenchymal stem cells (MSCs) in combination with pioglitazone, an agonist of peroxisome proliferator-activated receptor- γ (PPAR- γ), can reduce liver fibrosis in models of liver injury. In this study, we conducted a pilot study of intraportal infusion of autologous MSCs in combination with pioglitazone to assess safety, feasibility, and effectiveness in patients with compensated cirrhosis.

Methods: Two patients with compensated cirrhosis were enrolled in this study. Intraportal autologous bone marrow-derived MSCs were transplanted twice (6 months interval) to the patients. Meanwhile, 30 mg/day pioglitazone was prescribed for 12 months. Patients were assessed at baseline and months 1, 3, 6, and 12 post-infusion.

Results: Procedural complications or any major adverse effects did not occur in this pilot study. The patients' clinical conditions remained stable with no evidence of deterioration during the course of the study. A transient improvement in the Model for End-Stage Liver Disease (MELD) score was observed at month 3 post-infusion in one patient, which eventually returned to baseline at month 12.

Conclusion: The combination of pioglitazone with MSCs is safe and feasible. The data justify further study of the combination therapy in cirrhotic patients.

Keywords: Cell therapy, cirrhosis, mesenchymal stem cell, pioglitazone, PPAR- γ

Cite this article as: Vosough M, Moossavi S, Mardpour S, Akhlaghpour S, Azimian V, Jarughi N, Hosseini SE, Ashrafi M, Nikfam S, Aghdami N, Malekzadeh R, Mohamadnejad M, Baharvand H. Repeated Intraportal Injection of Mesenchymal Stem Cells in Combination with Pioglitazone in Patients with Compensated Cirrhosis: A Clinical Report of Two Cases. *Arch Iran Med.* 2016; 19(2): 131 – 136.

Introduction

Liver fibrosis is a transient, reversible immune-mediated response characterized by excessive production of extracellular matrix due to acute or self-limited liver injury. Changes in non-persistent irritation of the liver are usually temporary and normal liver architecture can be restored if the pathologic cause disappears. However, sustained injuries in chronic disorders result in progressive and, under certain circumstances, irreversible fibrogenesis.^{1,2} The extent of fibrosis depends on the dynamic equilibrium of the fibrogenesis and fibrolysis processes. During the early stages of liver injury, myofibroblasts, the activated version of hepatic stellate cells (HSCs), appear and secrete an excess amount of extracellular matrix proteins.³ It is proposed that stel-

late cell resolution can result in fibrosis reversal and hence, plausibly, cirrhosis regression.⁴

Pioglitazone, which is commonly used in type 2 diabetes, is an agonist of peroxisome proliferator-activated receptor (PPAR)- γ . It is known to reduce insulin resistance in muscle, fat and liver cells, in addition to regulation of fat metabolism.^{5,6} PPAR- γ has been recently implicated in extracellular matrix remodelling and fibrosis.⁷ A reduced level of PPAR- γ has been observed in liver fibrosis.^{8,9} Activation of PPAR- γ has been shown to down-regulate the expression of extracellular matrix genes and myofibroblast transformation in HSCs, hepatocytes, and hepatoma cells *in vitro*. Boosted expression of PPAR- γ receptor significantly suppresses the expression of α -SMA and type I collagen in myofibroblasts.¹⁰ In addition, activation of PPAR- γ reduces fibrosis in choline-deficient, l-amino acid-defined (CDAA) diet induced hepatic fibrosis, methionine choline deficient (MCD) diet-induced fibrosing steatohepatitis, thioacetamide-hepatoma cell induced hepatic fibrosis, *Schistosoma japonicum* induced hepatic fibrosis, and bile duct ligation induced hepatic fibrosis.^{7,11,12}

Pioglitazone mitigates some clinical complications of cirrhosis, which are due to portal hypertension, by its immuno-modulatory effect on inflammation and angiogenesis in cirrhotic and non-cirrhotic rats.¹³ In addition, peroxisome proliferator-activated receptor- γ activation in cirrhosis induced subsequent to bile duct ligation attenuates motor and cognition impairments in the rat animal model.¹⁴

The therapeutic benefits of pioglitazone have been investigated in non-alcoholic steatohepatitis (NASH).¹⁵⁻²⁵ In 2006, the New

Authors' affiliations: ¹Department of Regenerative Medicine, Cell Science Research Center, Royan Institute for Stem Cell Biology and Technology, ACECR, Tehran, Iran. ²Liver and Pancreatobiliary Diseases Research Center, Digestive Diseases Research Institute, Tehran University of Medical Sciences, Tehran, Iran. ³Digestive Diseases Research Center, Digestive Diseases Research Institute, Tehran University of Medical Sciences, Tehran, Iran. ⁴Noor Medical Imaging Center, Tehran, Iran

•**Corresponding author and reprints:** Mehdi Mohamadnejad MD, Director Digestive Disease Research Institute, Tehran University of Medical Sciences, Shariati Hospital, Kargar Shomali Ave., Tehran 14117, Iran. Telefax: +98 21 82415104, Fax: +98 21 8241 5400, E-mail: mehdim@ams.ac.ir. Hossein Baharvand PhD, Department of Regenerative Medicine, Cell Science Research Center, Royan Institute for Stem Cell Biology and Technology, ACECR, P.O. Box 19395-4644, Tehran, Iran. Tel: +98 21 22306485, Fax: +98 21 23562507, E-mail: Baharvand@RoyanInstitute.org.

#: These authors contributed equally in this work.

Accepted for publication: 15 December 2015

England Journal of Medicine published a placebo-controlled trial of daily pioglitazone in patients with NASH. Belford and colleagues reported improvement in histologic findings in terms of steatosis, ballooning necrosis, and inflammation compared with control group after administration of pioglitazone. Despite the remarkable reduction in necroinflammation, the regression in the extent of fibrosis was not significant in the study group compared to controls.²⁶ In another pilot study, the combination of pioglitazone and vitamin A resulted in a significant decrease in peri-cellular fibrosis, steatosis, cytologic ballooning and Mallory's hyaline.²⁷

Regenerative medicine and stem cell therapy in end-stage liver disease have gained significant appreciation in recent years.²⁸⁻³¹ Mesenchymal stem cells (MSCs) are commonly investigated in a therapeutic setting in cirrhosis.³²⁻³⁵ It has been observed that MSCs can reduce the level of fibrosis.³⁶⁻³⁸

It was demonstrated that repeated administration of MSCs resulted in more effective cell therapy in different experimental models.³⁹⁻⁴¹ Furthermore, repeated transplants of hepatocytes supported liver regeneration and prevented the disease.^{42,43} Boost administration of hematopoietic stem cells led to lasting amelioration in the clinical course of cirrhosis over long-term follow-up.⁴⁴ Moreover, we have reported that repeated infusion was three times more effective in homing of transplanted MSCs compared with the single transplant.⁴⁵ On the other hand, we have previously observed that the combination of Pioglitazone and MSC reduced liver fibrosis more effectively than either of them alone in mice.⁴⁶ We hypothesized that a combination of both boost MSC injections and Pioglitazone administration would augment the anti-fibrotic effects of each treatment alone. The main objective of this study is to assess the safety and feasibility of combination therapy in compensated cirrhosis. In addition, we also assessed the reversibility of liver fibrosis and improvement of liver function.

Patients and Methods

Patients

We enrolled two patients diagnosed with compensated cirrhosis at the Digestive Disease Research Institute, Tehran University of Medical Sciences between June 2010 and August 2010. The diagnosis of compensated cirrhosis was made based on clinical symptoms; biochemical indices of liver failure; and fibroscan findings or compatible findings on liver biopsy. The inclusion criteria were: age 15–65 years and confirmed diagnosis of cirrhosis based on liver biopsy six months prior to enrolment (stages 5 or 6 based on Ishak score).⁴⁷ Exclusion criteria included decompensated cirrhosis based on clinical and laboratory data (Child Class B or C); grades III or IV hepatic encephalopathy during 6 months prior to study entry; refractory ascites; elevated serum transaminases levels three times the normal values; active autoimmune hepatitis manifested as increased level of serum gamma-globulin more than twice the normal limit; serum creatinine of more than 1.5 mg/dL; positive HIV Ab or HCV Ab; HBV DNA level more than 200 IU/mL; primary sclerosing cholangitis; hepatocellular carcinoma (HCC); active infectious disease; positive history of esophageal variceal bleeding one month prior to enrolment; portal and/or hepatic vein thrombosis diagnosed by Doppler ultrasound; co-morbid conditions that included cardiovascular, pulmonary, neurologic, or nephrologic problems; malignancy; substance abuse; alcohol consumption; or hepatotoxic medication prescrip-

tion at least three months prior to enrolment.

This study was approved by the Ethics Committee of the Digestive Disease Research Institute, Tehran University of Medical Sciences. The study was conducted in accordance with the Declaration of Helsinki. Written informed consent was obtained from patients. The study was registered at the U.S. National Institute of Health Clinical Trials Database (Identifier: NCT01454336).

Study design

This pilot study was conducted on two patients who suffered from compensated cirrhosis to determine the safety and feasibility of combined daily Pioglitazone and autologous MSC transplantation. Patients were visited at Shariati Hospital, Tehran, Iran one day prior to the intervention. BM aspiration and isolation of MSCs were performed once for the first patient and twice for the second patient at Royan Institute, Tehran, Iran. Due to the abundant harvest of the second patient's MSCs, half of the cells were frozen for the second injection. MSC transplantation was performed twice at 6-month intervals. Patients were admitted to the hospital for transplantation where they were observed for 24 hours post-infusion. An interventional radiologist conducted the infusion under ultrasound guidance. A total of 20 mL of cell suspension was infused through a 20 G catheter (PSK, Japan) into the portal vein under light sedation and local anesthesia over 5–10 minutes. Pioglitazone was taken orally at the dose of 30 mg per day for 12 months. The study design is schematically illustrated in Figure 1. The primary objective was to assess safety and feasibility of the study. Secondary outcomes were absolute changes in MELD score, liver function tests, and liver volumes at months 3 and 12 post-infusion.

Harvesting and culture of MSCs

MSCs were harvested and cultured as previously described.³² Briefly, the mononuclear fraction was isolated by Ficoll-Hypaque density gradient centrifugation at 435 g for 30 min at room temperature and seeded at a density of 1×10^6 cells/cm² into T150 cell culture flasks (Nunc, Austria). The cells were plated in γ -irradiated Dulbecco's modified Eagle's medium-low glucose (DMEM-LG; Gibco, UK), supplemented with 10% fetal calf serum (Sigma, Germany), 1% penicillin and streptomycin (Gibco, UK), and incubated at 37°C with 5% CO₂. Cells were sub-cultured for 2–3 times. In the final passage, cells were washed with Tyrode salt solution and incubated in M199 (Gibco, UK) for one hour at 37°C. Subsequently, the cells were harvested by incubation with 0.25% trypsin/1 mM EDTA (Gibco, UK) and washed three times with M199 supplemented with 1% human serum albumin (HSA). Cells were then suspended in heparinized M199 to the final concentration of 1×10^6 cells/mL. The suspension was filtered to remove cell aggregates. Cell viability was evaluated by the Trypan blue exclusion dye method. Characterization of harvested MSCs was performed based on typical surface protein markers. Briefly, cells were fixed with 4% paraformaldehyde and immunophenotyping analysis was conducted using a BD FACS Calibur flow cytometry system (BD Biosciences, San Jose, CA, USA). The list of antibodies of the characterisation plan is provided in Table 1.

All samples passed quality control tests and contamination was ruled out by microbiology assays, complementary mycoplasma analysis, and an endotoxin assay. Cytogenetic analysis was performed to ensure the intact karyotype of MSCs. The Quality Assurance unit at the cGMP Facility at Royan Institute approved the release of the cells based on regular SOPs and QC measurements.

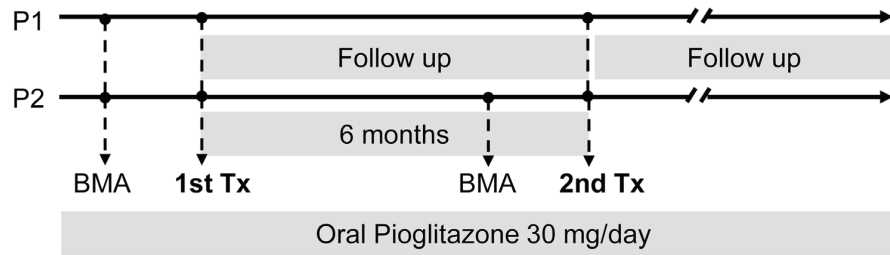


Figure 1. Study design. BMA = bone marrow aspiration, Tx = cell transplantation, P = patient.

Follow up

Patients were visited by a physician at baseline and at months 1, 3, 6, and 12. They were examined for signs and symptoms of ascites, edema, and encephalopathy on each follow-up visit. The following blood tests were requested prior to and 24 hours after MSC transplantation and then every three months: complete blood count (CBC), serum aspartate aminotransferase (AST), serum alanine aminotransferase (ALT), serum alkaline phosphatase (AlkP), serum total bilirubin, blood urea nitrogen (BUN), serum creatinine, serum alpha fetoprotein (AFP), prothrombin time (PT), and international normalized ratio (INR). In addition, 10 mL of venous blood was obtained and the plasma stored at -70°C . A trans-abdominal Doppler ultrasound was performed to assess the liver and portal vein at baseline, following transplantation, and at the end of the follow up period.

Results

Patients

There were two patients recruited for this study. Patient 1 was a 40-year-old female with cryptogenic cirrhosis and patient 2 was a 52-year-old male with cirrhosis due to NASH. Quantity, viability, and characteristic of MSCs are summarized in Tables 2 and 3. The baseline characteristics of these patients are summarized in Table 4.

Evaluation of safety and feasibility

Patients were evaluated on each visit for procedural complications and major adverse effects that included acute renal failure, portal hypertension, and progressive elevation in serum AFP. None of these events occurred in our patients.

Table 1. The list of antibodies used in this study.

Antibody	Host Species	Supplier and Cat. no.	Conjugated with
CD73, cloneAD2	Mouse	BD 550257	PE
CD90, clone5E10	Mouse	BD 555595	FITC
CD105, clone266	Mouse	BD 560839	PE
CD45/CD34	Mouse	BD 341071	FITC/PE
CD44, cloneC26	Mouse	BD 555478	FITC
IgG2b ,clone GC198	Mouse	Millipore MABC006F	FITC
IgG1/ IgG1	Mouse	Dako X0932	FITC/PE
IgG1,k isotype control, clone MOPC-21	Mouse	BD 551436	PE

Table 2. Quantity and viability of transplanted MSCs in the first and second injections. Bone marrow (BM) aspiration was performed once for patient 1 for whom the BM aspirate was divided into two parts and used for both transplantations.

Patients	MNC 1 st BMA/mL	MNC 2 nd BMA /mL	MSCs 1 st Tx (Vi)	MSCs 2 nd Tx (Vi)
Patient 1	6.2×10^8	—	2.31×10^8 (74%)	2.15×10^8 (95%)
Patient 2	1.25×10^8	2.2×10^8	1.4×10^8 (99%)	2.58×10^8 (96%)

BMA = bone marrow aspiration; MNC = mononuclear cell; MSCs = mesenchymal stem cells; Tx = transplantation; Vi = % viability

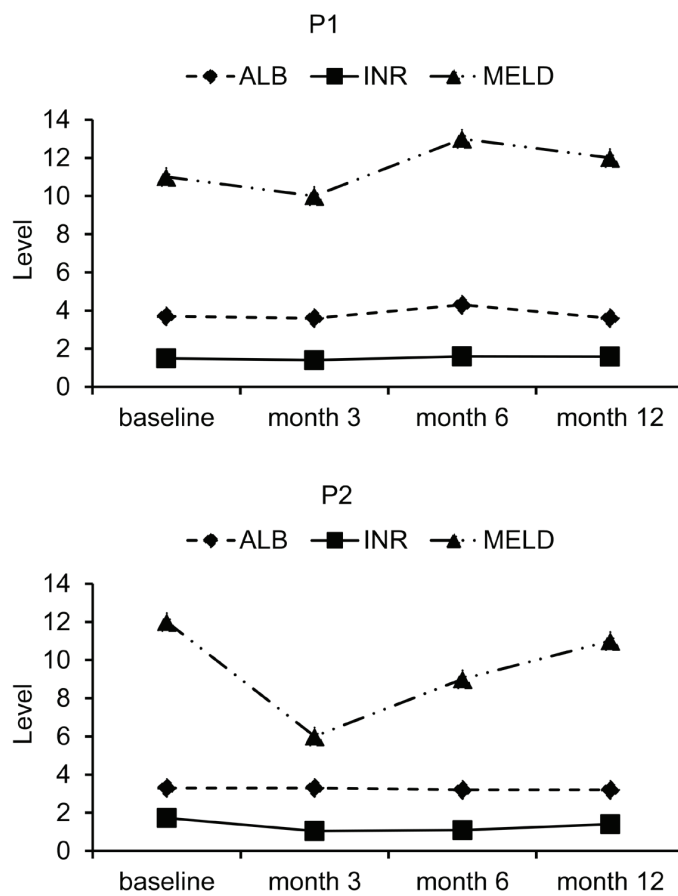
Table 3. Characterization of MSCs before the first and second injections. BM aspiration was performed once for patient 1 and twice for patient 2.

Patients	CD 90	CD 105	CD 73	CD 44
Patient 1	95.0%	95.7%	97.7%	96.3%
Patient 2 (first aspiration)	99.4%	99.4%	95.0%	95.5%
Patient 2 (second aspiration)	98.7%	97.1%	97.9%	96.4%

Table 4. Clinical and laboratory parameters of the patients.

Parameters	Patient 1				Patient 2			
	Baseline	Month 3	Month 6	Month 12	Baseline	Month 3	Month 6	Month 12
Albumin (g/dL)	3.7	3.6	4.3	3.6	3.3	3.3	3.2	3.2
PT (sec)	16.6	15.1	16.2	16.3	14.9	11.2	11.5	13.2
INR	1.5	1.4	1.6	1.59	1.73	1.04	1.09	1.4
Cr (mg/dL)	0.74	0.76	0.74	0.68	0.94	0.94	1.12	1.06
Total bilirubin (mg/dL)	0.94	0.73	1.28	0.75	0.77	0.79	1.19	0.77
Direct bilirubin (mg/dL)	0.34	0.29	0.43	0.28	0.29	0.29	0.36	0.28
AST (U/L)	36	22	32	34	29	27	33	28
ALT (U/L)	34	17	19	22	15	13	15	15
AFP (ng/mL)	1.37	1.09	1.42	1.18	2.9	2.8	3.1	2.5
MELD score	11	10	13	12	12	6	9	11
Fibroscanscore (kPa)	8.5	—	—	11	48	—	—	48

AFP = alpha fetoprotein; ALT = alanine aminotransferase; AST = aspartate aminotransferase; Cr = creatinine; INR = international normalized ratio; MELD = Model for End-Stage Liver Disease; PT = prothrombin time; kPa = Kilopascal.

**Figure 2.** The albumin level, INR and MELD score changes were illustrated for first (P1) and second (P2) patients. INR = international normalized ratio; MELD = Model for End-Stage Liver disease.

Liver function assessment

Serum albumin did not change after infusions at baseline and month 3 (Table 4). A slight increase in serum albumin was observed in patient 1 at month 6 which returned to baseline at month 12. MELD score decreased slightly at month 3 and then increased again until month 6 and decreased to the level of baseline at month 12 in patient 1. In patient 2, MELD score decreased sharply at month 3 with a subsequent, gradual increase to the level of

baseline at month 12. INR remained constant in patient 1. However, INR decreased at month 3 and then remained constant up to month 6. Subsequently, there was a slight increase at month 12 in patient 2 (Table 4). The fibroscan score slightly increased in patient 1 from 8.5 at baseline to 11 at month 12. However, the fibroscan score remained unchanged in patient 2 (Table 4). The albumin level, INR and MELD score changes were illustrated for both patients in Figure 2.

Discussion

Fibrosis is a dynamic process that follows chronic inflammatory response to various pathogenic events. Fibrosis is characterized by deposition of excessive amounts of ECM proteins. Necrosis and apoptosis of hepatocytes initiate inflammatory signaling by pro-inflammatory mediators and result in accelerated recruitment of immune cells and activation of resident HSCs. Current medical therapeutics include modification of immune injury and pathogen eradication.

Pioglitazone, an effective medicine in glucose homeostasis, is a well-known agonist of the PPAR- γ receptor. Activation of PPAR- γ signaling pathway by Pioglitazone results in decreased fibrogenesis.^{26,27} The intensity of HSC activation to myofibroblasts is mediated by molecular interactions between the TGF- β signaling pathway and PPAR- γ -axis, which is suppressed by ligands of the PPAR- γ receptor.⁴⁸

MSCs have been extensively examined in various diseases, including cirrhosis.³²⁻³⁵ MSCs produce several biochemical mediators that can potentially suppress the immune system, the most important of which are TGF- β , IL-10 and PG E2.^{49,50} We have previously observed that combined treatment with BM-MSCTransplantation and Pioglitazone leads to significant reduction of both relative and total hepatic fibrosis in mice while each treatment strategy alone has weak anti-fibrotic properties in CCl4-induced liver damage in mice model.⁴⁶

In our previous randomized controlled trial, we infused MSCs in single administration through the peripheral vein in cirrhosis.⁵¹ However, in this study, we repeated MSCs injection twice through portal vein and combined it with one year of daily Pioglitazone therapy. We demonstrated the safety and feasibility of the combined application of pioglitazone and autologous MSCs transplantation in two patients.

Two patients with compensated cirrhosis were recruited for this study. We did not observe any procedural complications and major adverse effects during the follow up. One patient's status neither improved nor deteriorated during the course of this study. However, in the second patient, we observed a transient reduction in MELD score at month 3 which eventually returned to the baseline level. Although we did not detect a persistent reduction in MELD score, this score did not increase during the follow up period, either. This transient improvement might be related to temporary beneficial effects of MSCs in combination with pioglitazone. Li *et al.* tracked human MSCs after an intraportal infusion in pigs. They observed that the transplanted MSCs were widely distributed in hepatic lobules up to 10 weeks after infusion. However, the number of transplanted cells significantly decreased at week 15 post-infusion.⁵² This might explain the transient improvement of the MELD score observed in our study. The transient improvement in MELD score could also be ascribed to the natural course of cirrhosis in this patient.

Pioglitazone has thus far been examined only in NASH¹⁵⁻²⁵ which is believed to be the hepatic manifestation of the metabolic syndrome. Therefore, the beneficial effect of pioglitazone on NASH could plausibly be mediated via its effect on regulation of insulin sensitivity and glucose metabolism.⁵³ The anti-fibrogenic role of PPAR agonists has not been examined in cirrhosis in humans. This was the first report of a combination of Pioglitazone with MSC in cirrhosis. Overall, we demonstrated the safety and feasibility of Pioglitazone plus MSC transplantation in two

cirrhotic patients. However, to assess its beneficial effect, randomized clinical trials that include large sample sizes would be required in the future.

Conflict of interest: None declared.

Author contributions

Massoud Vosough: Conception and design, provision of study material or patients, data analysis and interpretation, drafting article, final approval of manuscript

Shirin Moossavi: Data analysis and interpretation, drafting article, statistics, final approval of manuscript

Soura Mardpour, Shahram Akhlaghpour, Vajiheh Azimian, Neda Jarughi, Seyede-Esmat Hosseini, Mandana Ashrafi and Sepideh Nikfam: Data collection, and/or assembly of data, data analysis and interpretation

Nasser Aghdami: Conception and design, provision of study material or patients, administrative support,

Reza Malekzadeh: Conception and design, provision of study material or patients, administrative support, financial support

Mehdi Mohamadnejad: Conception and design, administrative support, provision of study material or patients, final approval of manuscript,

Hossein Baharvand: Conception and design, financial support, administrative support, provision of study material or patients, final approval of manuscript

Acknowledgments

The study was supported by grants from Royan Institute for Stem Cell Biology and Technology, Digestive Disease Research Institute of Tehran University of Medical Sciences, and Iranian Council for Stem Cell Research and Technology. We express our appreciation to all members of the liver Program at Royan Institute for their helpful deliberations and consultation during this work.

References

- Schuppan D, Kim YO. Evolving therapies for liver fibrosis. *J Clin Invest.* 2013; 123(5): 1887 – 1901.
- Ramachandran P, Iredale JP. Liver fibrosis: a bidirectional model of fibrogenesis and resolution. *QJM.* 2012; 105(9): 813 – 817.
- Wells RG, Schwabe RF. Origin and function of myofibroblasts in the liver. *Semin Liver Dis.* 2015; 35(2): 97 – 106.
- Lee UE, Friedman SL. Mechanisms of hepatic fibrogenesis. *Best Pract Res Clin Gastroenterol.* 2011; 25(2): 195 – 206.
- Pfutzner A, Weber MM, Forst T. Pioglitazone: update on an oral antidiabetic drug with antiatherosclerotic effects. *Expert Opin Pharmacother.* 2007; 8(12): 1985 – 1998.
- Jones JR, Barrick C, Kim KA, Lindner J, Blondeau B, Fujimoto Y, et al. Deletion of PPARgamma in adipose tissues of mice protects against high fat diet-induced obesity and insulin resistance. *Proc Natl Acad Sci U S A.* 2005; 102(17): 6207 – 6212.
- Wei J, Bhattacharyya S, Jain M, Varga J. Regulation of Matrix Remodeling by Peroxisome Proliferator-Activated Receptor-gamma: A Novel Link Between Metabolism and Fibrogenesis. *Open Rheumatol J.* 2012; 6: 103 – 115.
- Miyahara T, Schrum L, Rippe R, Xiong S, Yee HF, Jr., Motomura K, et al. Peroxisome proliferator-activated receptors and hepatic stellate cell activation. *J Biol Chem.* 2000; 275(46): 35715 – 35722.
- Yang L, Chan CC, Kwon OS, Liu S, McGhee J, Stimpson SA, et al. Regulation of peroxisome proliferator-activated receptor-gamma in liver fibrosis. *Am J Physiol Gastrointest Liver Physiol.* 2006; 291(5): G902 – G911.
- Wang Z, Xu JP, Zheng YC, Chen W, Sun YW, Wu ZY, et al. Peroxisome proliferator-activated receptor gamma inhibits hepatic fibrosis in rats.

- Hepatobiliary Pancreat Dis Int.* 2011; 10(1): 64 – 71.
11. Uto H, Nakanishi C, Ido A, Hasuike S, Kusumoto K, Abe H, et al. The peroxisome proliferator-activated receptor-gamma agonist, pioglitazone, inhibits fat accumulation and fibrosis in the livers of rats fed a choline-deficient, L-amino acid-defined diet. *Hepatol Res.* 2005; 32(4): 235 – 242.
 12. Kawaguchi K, Sakaida I, Tsuchiya M, Omori K, Takami T, Okita K. Pioglitazone prevents hepatic steatosis, fibrosis, and enzyme-altered lesions in rat liver cirrhosis induced by a choline-deficient L-amino acid-defined diet. *Biochem Biophys Res Commun.* 2004; 315(1): 187 – 195.
 13. Schwabl P, Payer BA, Grahovac J, Klein S, Horvatits T, Mitterhauser M, et al. Pioglitazone decreases portosystemic shunting by modulating inflammation and angiogenesis in cirrhotic and non-cirrhotic portal hypertensive rats. *J Hepatol.* 2014; 60(6): 1135 – 1142.
 14. Aghaei I, Shabani M, Doustar N, Nazeri M, Dehpour A. Peroxisome proliferator-activated receptor-gamma activation attenuates motor and cognition impairments induced by bile duct ligation in a rat model of hepatic cirrhosis. *Pharmacol Biochem Behav.* 2014; 120: 133 – 139.
 15. Hajiaghahmohammadi AA, Ziaee A, Oveisi S, Masroor H. Effects of metformin, pioglitazone, and silymarin treatment on non-alcoholic fatty liver disease: a randomized controlled pilot study. *Hepat Mon.* 2012; 12(8): e6099.
 16. Bell LN, Wang J, Muralidharan S, Chalasani S, Fullenkamp AM, Wilson LA, et al. Relationship between adipose tissue insulin resistance and liver histology in nonalcoholic steatohepatitis: a pioglitazone versus vitamin E versus placebo for the treatment of nondiabetic patients with nonalcoholic steatohepatitis trial follow-up study. *Hepatology.* 2012; 56(4): 1311 – 1318.
 17. Gastaldelli A, Harrison S, Belfort-Aguilar R, Hardies J, Balas B, Schenker S, et al. Pioglitazone in the treatment of NASH: the role of adiponectin. *Aliment Pharmacol Ther.* 2010; 32(6): 769 – 775.
 18. Musso G, Gambino R, Cassader M, Pagano G. A meta-analysis of randomized trials for the treatment of nonalcoholic fatty liver disease. *Hepatology.* 2010; 52(1): 79 – 104.
 19. Sanyal AJ, Chalasani N, Kowdley KV, McCullough A, Diehl AM, Bass NM, et al. Pioglitazone, vitamin E, or placebo for nonalcoholic steatohepatitis. *N Engl J Med.* 2010; 362(18): 1675 – 1685.
 20. Gastaldelli A, Harrison SA, Belfort-Aguilar R, Hardies LJ, Balas B, Schenker S, et al. Importance of changes in adipose tissue insulin resistance to histological response during thiazolidinedione treatment of patients with nonalcoholic steatohepatitis. *Hepatology.* 2009; 50(4): 1087 – 1093.
 21. Chalasani NP, Sanyal AJ, Kowdley KV, Robuck PR, Hoofnagle J, Kleiner DE, et al. Pioglitazone versus vitamin E versus placebo for the treatment of non-diabetic patients with non-alcoholic steatohepatitis: PIVENS trial design. *Contemp Clin Trials.* 2009; 30(1): 88 – 96.
 22. Aithal GP, Thomas JA, Kaye PV, Lawson A, Ryder SD, Spendlove J, et al. Randomized, placebo-controlled trial of pioglitazone in nondiabetic subjects with nonalcoholic steatohepatitis. *Gastroenterology.* 2008; 135(4): 1176 – 1184.
 23. Lutchman G, Modi A, Kleiner DE, Promrat K, Heller T, Ghany M, et al. The effects of discontinuing pioglitazone in patients with nonalcoholic steatohepatitis. *Hepatology.* 2007; 46(2): 424 – 429.
 24. Lutchman G, Promrat K, Kleiner DE, Heller T, Ghany MG, Yanovski JA, et al. Changes in serum adipokine levels during pioglitazone treatment for nonalcoholic steatohepatitis: relationship to histological improvement. *Clin Gastroenterol Hepatol.* 2006; 4(8): 1048 – 1052.
 25. Promrat K, Lutchman G, Uwaifo GI, Freedman RJ, Soza A, Heller T, et al. A pilot study of pioglitazone treatment for nonalcoholic steatohepatitis. *Hepatology.* 2004; 39(1): 188 – 196.
 26. Belfort R, Harrison SA, Brown K, Darland C, Finch J, Hardies J, et al. A placebo-controlled trial of pioglitazone in subjects with nonalcoholic steatohepatitis. *N Engl J Med.* 2006; 355(22): 2297 – 2307.
 27. Sanyal AJ, Mofrad PS, Contos MJ, Sargeant C, Luketic VA, Sterling RK, et al. A pilot study of vitamin E versus vitamin E and pioglitazone for the treatment of nonalcoholic steatohepatitis. *Clin Gastroenterol Hepatol.* 2004; 2(12): 1107 – 1115.
 28. Vosough M, Moslem M, Pournasr B, Baharvand H. Cell-based therapeutics for liver disorders. *Br Med Bull.* 2011; 100: 157 – 172.
 29. Lorenzini S, Andreone P. Stem cell therapy for human liver cirrhosis: a cautious analysis of the results. *Stem Cells.* 2007; 25(9): 2383 – 2384.
 30. Gilchrist ES, Plevris JN. Bone marrow-derived stem cells in liver repair: 10 years down the line. *Liver Transpl.* 2010; 16(2): 118 – 129.
 31. Pai M, Spalding D, Xi F, Habib N. Autologous bone marrow stem cells in the treatment of chronic liver disease. *Int J Hepatol.* 2012; it does not have it: 307165.
 32. Mohamadnejad M, Alimoghaddam K, Mohyeddin-Bonab M, Bagheri M, Bashtar M, Ghanaati H, et al. Phase I trial of autologous bone marrow mesenchymal stem cell transplantation in patients with decompensated liver cirrhosis. *Arch Iran Med.* 2007; 10(4): 459 – 466.
 33. Kharaziha P, Hellstrom PM, Noorinayer B, Farzaneh F, Aghajani K, Jafari F, et al. Improvement of liver function in liver cirrhosis patients after autologous mesenchymal stem cell injection: a phase I-II clinical trial. *Eur J Gastroenterol Hepatol.* 2009; 21(10): 1199 – 1205.
 34. Peng L, Xie DY, Lin BL, Liu J, Zhu HP, Xie C, et al. Autologous bone marrow mesenchymal stem cell transplantation in liver failure patients caused by hepatitis B: short-term and long-term outcomes. *Hepatology.* 2011; 54(3): 820 – 828.
 35. Zhao W, Li JJ, Cao DY, Li X, Zhang LY, He Y, et al. Intravenous injection of mesenchymal stem cells is effective in treating liver fibrosis. *World J Gastroenterol.* 2012; 18(10): 1048 – 1058.
 36. Abdel Aziz MT, Atta HM, Mahfouz S, Fouad HH, Roshdy NK, Ahmed HH, et al. Therapeutic potential of bone marrow-derived mesenchymal stem cells on experimental liver fibrosis. *Clin Biochem.* 2007; 40(12): 893 – 899.
 37. Motawi TM, Atta HM, Sadik NA, Azzam M. The therapeutic effects of bone marrow-derived mesenchymal stem cells and simvastatin in a rat model of liver fibrosis. *Cell Biochem Biophys.* 2014; 68(1): 111 – 125.
 38. Rabani V, Shahsavani M, Gharavi M, Piryaee A, Azhdari Z, Baharvand H. Mesenchymal stem cell infusion therapy in a carbon tetrachloride-induced liver fibrosis model affects matrix metalloproteinase expression. *Cell Biol Int.* 2010; 34(6): 601 – 605.
 39. Lee SR, Lee SH, Moon JY, Park JY, Lee D, Lim SJ, et al. Repeated administration of bone marrow-derived mesenchymal stem cells improved the protective effects on a remnant kidney model. *Ren Fail.* 2010; 32(7): 840 – 848.
 40. Chang DY, Yoo SW, Hong Y, Kim S, Kim SJ, Yoon SH, et al. The growth of brain tumors can be suppressed by multiple transplantation of mesenchymal stem cells expressing cytosine deaminase. *Int J Cancer.* 2010; 127: 1975 – 1983.
 41. Ho JH, Tseng TC, Ma WH, Ong WK, Chen YF, Chen MH, et al. Intravenous transplantations of mesenchymal stem cells effectively restore long-term blood glucose homeostasis by hepatic engraftment and beta cell differentiation in streptozosin-induced diabetic mice. *Cell Transplant.* 2012; 21(5): 997 – 1009.
 42. Rajvanshi P, Kerr A, Bhargava KK, Burk RD, Gupta S. Efficacy and safety of repeated hepatocyte transplantation for significant liver repopulation in rodents. *Gastroenterology.* 1996; 111(4): 1092 – 1102.
 43. Sauer V, Sijaj R, Stoppeler S, Bahde R, Spiegel HU, Kohler G, et al. Repeated transplantation of hepatocytes prevents fulminant hepatitis in a rat model of Wilson's disease. *Liver Transpl.* 2012; 18(2): 248 – 259.
 44. Yannaki E, Anagnostopoulos A, Kapetanios D, Xagorari A, Iordanidis F, Batsis I, et al. Lasting amelioration in the clinical course of decompensated alcoholic cirrhosis with boost infusions of mobilized peripheral blood stem cells. *Exp Hematol.* 2006; 34(11): 1583 – 1587.
 45. Miryounesi M, Piryaee A, Pournasr B, Aghdami N, Baharvand H. Repeated versus single transplantation of mesenchymal stem cells in carbon tetrachloride-induced liver injury in mice. *Cell Biol Int.* 2013; 37(4): 340 – 347.
 46. Mohamadnejad M, Sohail MA, Swenson ES, Popov Y, Sverdlov DY, Sharma A. Bone marrow-derived mesenchymal stem cell transplantation to enhance the anti-fibrotic effect of pioglitazone in hepatic fibrosis. *Hepatology.* 2009; 50: 811A.
 47. Ishak K, Baptista A, Bianchi L, Callea F, De Groote J, Gudat F, et al. Histological grading and staging of chronic hepatitis. *J Hepatol.* 1995; 22(6): 696 – 699.
 48. Cohen-Naftaly M, Friedman SL. Current status of novel antifibrotic therapies in patients with chronic liver disease. *Therap Adv Gastroenterol.* 2011; 4(6): 391 – 417.
 49. Deans RJ, Moseley AB. Mesenchymal stem cells: biology and potential clinical uses. *Exp Hematol.* 2000; 28(8): 875 – 884.
 50. Hou R, Liu R, Niu X, Chang W, Yan X, Wang C, et al. Biological characteristics and gene expression pattern of bone marrow mesenchymal stem cells in patients with psoriasis. *Exp Dermatol.* 2014; 23(7): 521 – 523.
 51. Mohamadnejad M, Alimoghaddam K, Bagheri M, Ashrafi M, Abdollahzadeh L, Akhlaghpour S, et al. Randomized placebo-controlled trial of mesenchymal stem cell transplantation in decompensated cirrhosis. *Liver Int.* 2013; 33(10): 1490 – 1496.
 52. Li J, Zhang L, Xin J, Jiang L, Li J, Zhang T, et al. Immediate intraportal transplantation of human bone marrow mesenchymal stem cells prevents death from fulminant hepatic failure in pigs. *Hepatology.* 2012; 56(3): 1044 – 1052.
 53. Voican CS, Perlemuter G. Insulin resistance and oxidative stress: two therapeutic targets in non-alcoholic steatohepatitis. *J Hepatol.* 2011; 54(2): 388 – 391.