

## Case Report

# Mycosis Fungoides of the True Vocal Cord: A Case Report and Review of the Literature

Zahra Maleki MD<sup>1</sup>, Farrukh Azmi MD PhD<sup>2</sup>

## Abstract

Mycosis fungoides is the most common type of cutaneous malignant T cell lymphoma which primarily affects skin. However, extracutaneous manifestation may occur in advanced stages, mostly observed in postmortem studies.

We present a case of mycosis fungoides that disseminated to the true vocal cord of a 48 year-old African American man who presented with hoarseness. Only two cases that have also demonstrated a rare involvement of the true vocal cord have been reported in the English literature. In both cases, mycosis fungoides infiltration of the true vocal cord was seen post-mortem, along with visceral dissemination of mycosis fungoides. We herein describe a single extracutaneous manifestation of mycosis fungoides in the true vocal cord of a living patient with a 21-year diagnosis of mycosis fungoides.

Vocal cord involvement by mycosis fungoides must be considered as one of the differential diagnoses in any mycosis fungoides patients who complain of persistent hoarseness. Awareness of this entity is clinically important due to the necessity of a different management.

**Keywords:** hoarseness, mycosis fungoides, true vocal cord

## Introduction

Mycosis fungoides (MF) was first described in 1806 by French dermatologist Jean-Louis-Marc Alibert. MF is a rare malignant T cell lymphoma with an abnormal CD4 expression that usually manifests with a primary cutaneous presentation. The skin surface can display erythematous and pruritic patches, plaques, tumors with ulcerations, and a leukemic phase (Sézary syndrome). The latter is seen in more severe cases.

Laryngeal involvement is an extremely rare presentation with only six reported cases in the literature review. Although MF infiltration of the larynx is principally considered a visceral dissemi-

nation of MF, evidence of primary extracutaneous lesion of the larynx has been reported, as well.<sup>1,2</sup> Earlier data have also suggested a tendency of MF to infiltrate the arytenoids, aryepiglottic fold and laryngeal surface of the epiglottis in the larynx.<sup>3</sup> To the best of our knowledge, this is the first reported case of MF involving the true vocal cord as the only extracutaneous manifestation in a living patient.

The accurate diagnosis of this rare entity is critical due to its specific treatment and management.

## Case Report

A 48-year-old African American male presented with pruritic patches in 1981 and was diagnosed with MF in 1984. His treatment for MF included: topical chemotherapy (nitrogen mustard), total body electron beam radiation therapy and extracorporeal photopheresis with chemotherapy (recombinant alpha interferon, methotrexate). In addition to MF, his past medical history was complicated by systemic

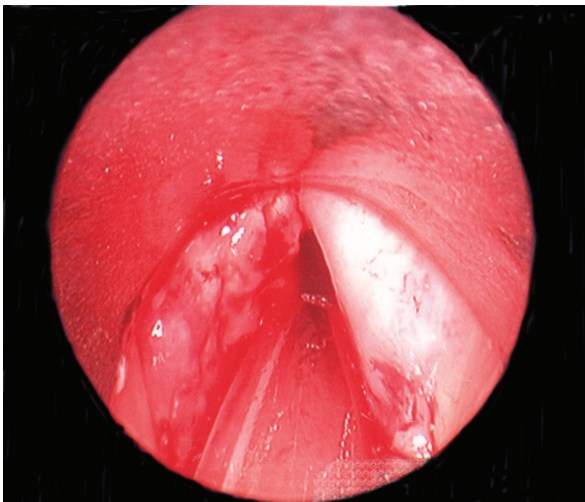
**Authors' affiliations:** <sup>1</sup>Department of Pathology, Johns Hopkins Hospital, Baltimore, MD, USA, <sup>2</sup>The Dermatopathology Laboratory, 5001 Centre Ave., Pittsburgh, PA, USA.

**Corresponding author and reprints:** Zahra Maleki MD, Department of Pathology, Johns Hopkins Hospital, 600 N. Wolfe Street, Baltimore, MD 21287, USA. Tel: +1-410-955-3520, Fax: +1-410-614-7986, E-mail: Zmaleki1@jhmi.edu

Accepted for publication: 21 October 2009

hypertension, congestive heart failure and diabetes mellitus. His past hospitalizations were due to neutropenic fever, pleural effusion, and pneumonia. In June 2002, the patient presented with shortness of breath, odynophagia, dysphagia, and hoarseness for three weeks duration. Physical findings were relevant for numerous ulcerative lesions on his skin. He was referred to an otolaryngologist for further work-up. Radiographs of the neck revealed a soft tissue opacity overlying the proximal esophagus and trachea under the hyoid bone.

A direct laryngoscopy was performed which showed a bulging mass and maceration of the left true vocal fold with extension into the subglottic region causing partial obstruction of the airway (Figure 1). No other lesions were found in the oral cavity, oropharynx, or hypopharynx. A biopsy was taken of the glottic lesion and the otolaryngology surgeons proceeded to debulk the remaining tumor. The patient continued with chemotherapy and radiotherapy for MF, and was subsequently discharged from the hospital. After debulking his larynx, he was hospitalized several times for dehydration, urinary tract infections, multiple abscesses, cellulitis, and pneumonia. However; pruritic plaques, nodules, and skin breakdown continued to persist in the patient all of them appeared to be refractory to current therapies.

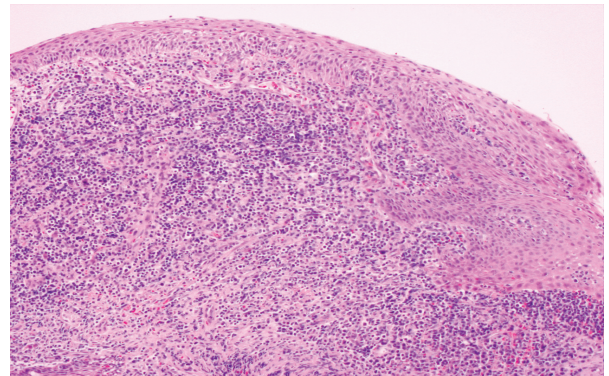


**Figure 1.** Direct laryngoscopy shows bulging of the tumor on the left vocal cord before biopsy

### Histopathology

Microscopic examination of the laryngeal mass showed an intense infiltrate of slightly enlarged

lymphocytes with convoluted nuclei and irregular borders focally extending into the vocal cord mucosa (Figure 2). Immunohistochemistry results demonstrated that the tumor cells were CD3<sup>+</sup>, CD4<sup>+</sup>, CD7<sup>-</sup>, CD8<sup>-</sup>, and CD20<sup>-</sup> which were suggestive of a diffuse T cell lineage in the tumor cell population. T and B-cell receptor gene rearrangement studies further revealed the presence of a monoclonal T cell lymphocyte population without B cell monoclonality. Multiple peripheral blood smears were negative for Sézary cells. A diagnosis of MF was confirmed by immunohistochemistry and T cell gene rearrangement.



**Figure 2.** Demonstrates an intense infiltrate of lymphocytes into the vocal cord (H&E, low magnification)

### Discussion

MF is the most common cutaneous T cell lymphoma. It occurs more frequently in males than females (2:1 ratio), typically in the fourth to ninth decades of life. The disease is more common in African Americans than in Caucasians.<sup>4</sup> Postmortem studies<sup>1</sup> show visceral dissemination in approximately 70% of cases that present with advanced stage MF. Cases presenting with generalized erythroderma, ulcers, or lymphadenopathy have an increased risk of developing visceral involvement.<sup>5</sup> The most commonly affected organs include the lungs, spleen, liver, kidneys, thyroid gland, pancreas, bone marrow, and heart. Extracutaneous manifestations of MF in the oral cavity,<sup>3,6,7</sup> esophagus,<sup>8</sup> larynx,<sup>1-4,5,8</sup> oropharynx,<sup>3,7</sup> nasopharynx,<sup>6</sup> and hypopharynx<sup>3,7,8</sup> have been reported by various authors.

In the case presented here, persistent hoarseness was an indication for direct laryngoscopy which re-

vealed a fungating mass of the true vocal cord. Differential diagnoses included tuberculosis, fungal infection, and squamous cell carcinoma. MF was the last in our differentials due to the rarity of laryngeal involvement with MF and all imaging studies were negative for extracutaneous involvement. A vocal cord biopsy revealed atypical lymphocytic infiltration with no evidence of fungal infection, granulomatous process such as tuberculosis and/or squamous cell carcinoma. Ancillary studies confirmed a diagnosis of MF.

Gordon et al.<sup>4</sup> published a case of MF with lesions on the laryngeal surface of the epiglottis that extended to the pyriform sinus. MF dissemination to the arytenoids, aryepiglottic fold and pyriform sinus has been described in a case report by Ferlito et al.<sup>1</sup> Kuhn et al.<sup>3</sup> reported a case of MF with a laryngeal mass that involved the left epiglottis, left aryepiglottic fold, left false vocal cord and left arytenoid with left vocal cord paralysis. Paresis of the vocal cord was attributed to infiltration of the recurrent laryngeal nerve. A second case presented by the authors also showed an invasion of multiple laryngeal structures including microscopic invasion of the true vocal cord in a postmortem evaluation.

True vocal cord manifestations of MF along with cutaneous and laryngeal involvement were seen during the autopsy of a case presented by Hood et al.<sup>2</sup>

Lippert et al.<sup>5</sup> published a case of a female patient who developed a supraglottic lesion that extended toward the false vocal cords and a secondary lesion in the nasal cavity that infiltrated into the maxillary sinus.

Esophageal manifestations of MF have been reported by Redleaf et al.,<sup>8</sup> in which friable lesions of the hypopharynx, arytenoids, and cervical esophagus were observed. The authors have suggested that MF development in the upper gastrointestinal tract presents a pattern in which it starts from the proximal esophagus and progresses to the distal.

Differential diagnosis for laryngeal lymphocytic infiltrates include other hematologic malignancies such as other types of lymphomas, multiple myelo-

ma, Hodgkin's disease, and acute or chronic leukemias.<sup>1,6</sup>

In conclusion, MF rarely displays laryngeal involvement and is less common when it is the only extracutaneous manifestation of the disease. However, it should be included in the differential diagnosis in any MF patients who complain of hoarseness and shortness of breath, due to its specific therapeutic modalities and prognostic implications.

### Acknowledgment

*The authors thank the constructive comments by William Westra, MD, Professor of Pathology at the Johns Hopkins University.*

### References

1. Ferlito A, Recher G. Laryngeal involvement by mycosis fungoides. *Ann Otol Rhinol Laryngol.* 1986; **95**: 275 – 277.
2. Hood AF, Mark GJ, Hunt JV. Laryngeal mycosis fungoides. *Cancer.* 1979; **43**: 1527 – 1532.
3. Kuhn JJ, Wenig BM, Clark DA. Mycosis fungoides of the larynx. Report of two cases and review of the literature. *Arch Otolaryngol Head Neck Surg.* 1992; **118**: 853 – 858.
4. Gordon LJ, Lee M, Conley JJ, Bufill J, Vonderheid E. Mycosis fungoides of the larynx. *Otolaryngol Head Neck Surg.* 1992; **107**: 120 – 123.
5. Lippert BM, Hoft S, Teymoortash A, Wiedow O, Rovert J, Werner JA. Mycosis fungoides of the larynx: case report and review of the literature. *Otolaryngol Pol.* 2002; **56**: 661 – 667.
6. Damm DD, White DK, Cibull ML, Drummond JF, Cramer JR. Mycosis fungoides: initial diagnosis via palatal biopsy with discussion of diagnostic advantages of plastic embedding. *Oral Surg Oral Med Oral Pathol.* 1984; **58**: 413 – 419.
7. Strahan RW, Calcaterra TC. Otolaryngologic aspects of mycosis fungoides. A case report. *Laryngoscope.* 1971; **81**: 1912 – 1916.
8. Redleaf MI, Moran WJ, Gruber B. Mycosis fungoides involving the cervical esophagus. *Arch Otolaryngol Head Neck Surg.* 1993; **119**: 690 – 693.