

Case Report

Congenital Posterior Spinal Agenesis Leads to L2-L3 Instability: a Case Report and Review of the Literature

Mohammad Samadian MD¹, Mehrdad Hosseinzadeh Bakhtevvari MD², Armin Jahangiri Babadi MD³, Naveed Nabizadeh MD⁴, Omidvar Rezaei MD⁵

Abstract

Congenital absence of posterior elements of the lumbar column is an extremely uncommon anomaly and we found no any reported cases of incomplete congenital absence of the posterior elements of lumbar vertebra in the literature.

Here, we present a case with congenital absence of posterior elements of lumbar vertebra. The patient was a 51-year-old man with a history of 20 years of back pain. Imaging of the lumbar spine revealed instability in L2 and L3 and there was evidence of retrolisthesis, agenesis of pars interarticularis, spinous processes, lamina, transverse processes and facets at L2 and L3. The patient underwent lumbar discectomy and posterior spinal fixation and instrumentation was then done using pedicle screw fixation. Four pedicle screws, two rods, and one cross link were employed to bilaterally fix the L2 and L3 and then we used autograft and allograft bone for interbody fusion, substitutes from iliac crest for posterior fusion. There were no postoperative complications, and at 6, 12 and 24 months of follow-up, his leg and back pain had improved, and the patient did not need any analgesic for pain relief.

Complete congenital absence of the lumbar posterior element has been rarely reported in the literature. Patients whose congenital anomalies lead to segmental instability are surgical fusion candidates, but if these anomalies occur in pars interarticularis such as spondylolysis isthmus, fixation and inter segmental fusion techniques are useful.

Key word: agenesis, congenital anomalies, instability, lumbar vertebra

Cite this article as: Samadian M, Hosseinzadeh Bakhtevvari M, Jahangiri Babadi A, Nabizadeh N, Rezaei O. Congenital Posterior Spinal Agenesis Leads to L2-L3 Instability: a Case Report and Review of the Literature. *Arch Iran Med.* 2015; **18(12)**: 861 – 864.

Introduction

Isolated anomalies of posterior elements of the spine are extremely rare. There are some reports of patients with complete absence of posterior elements of the axis and spinal instability.^{1,2,3} Congenital absence of posterior elements of the lumbar column is an uncommon anomaly. There are some documents that have reported the congenital absence of the lumbosacral articular facet joint.⁴⁻¹⁰ Yoshioka, *et al.* also reported a rare case of congenital absence of the L5-S1 facet joints.¹⁰ Our review of the literature did not reveal any reported cases of incomplete congenital absence of posterior elements of lumbar vertebra. Here, we present a rare case with congenital absence of posterior elements of lumbar vertebra.

In these cases, during the acute phase, conservative therapy is recommended and the majority of symptoms can be treated with conservative care, but surgery is considered in cases where conservative therapy fails and the patient remains symptomatic.^{11,12}

Authors' affiliations: ¹Associate Professor of Neurosurgery, Department of Neurosurgery, Loghman e Hakim Hospital, Shahid Beheshti University of Medical Sciences, Tehran, Iran. ²Resident of Neurosurgery, Department of Neurosurgery, Loghman e Hakim Hospital, Shahid Beheshti University of Medical Sciences, Tehran, Iran. ³Resident of Neurosurgery, Department of Neurosurgery, Loghman e Hakim Hospital, Shahid Beheshti University of Medical Sciences, Tehran, Iran. ⁴Assistant Professor of Orthopedic Spine Surgery, Department of Neurosurgery, Loghman e Hakim Hospital, Shahid Beheshti University of Medical Sciences, Tehran, Iran. ⁵Professor of Neurosurgery, Department of Neurosurgery, Loghman e Hakim Hospital, Shahid Beheshti University of Medical Sciences, Tehran, Iran.

Corresponding author and reprints: Mehrdad Hosseinzadeh Bakhtevvari MD, Resident of Neurosurgery, Department of Neurosurgery, Loghman e Hakim Hospital, Shahid Beheshti University of Medical Sciences, Tehran, Iran. Telefax: +9821-55414065; E-mail: mehrdaada@yahoo.com
Accepted for publication: 16 August 2015

Recently, several surgical methods have been used including single or multiple segment fixation, single vertebral body direct repair and isthmic repair and fusion. Although improvement after intervertebral body fusion was about 75%–100% and compensatory activities of adjacent vertebral segments were increased, the risk of second surgery due to diseases in the adjacent intervertebral space also increased.^{13,14} Many stabilization methods have been reported for treating congenital anomalies, including posterolateral spine fusion, posterior lumbar fusion, isthmic Buck screw fusion,¹⁵ stabilization of the diseased vertebra by wiring between the spinous process and the transverse process,¹⁶ stabilization by the combined use of pedicle screw and wiring or cable,¹⁷ stabilization by the joint use of pedicle screw and a hook screw,¹⁸ or stabilization with pedicle screw-V rod.^{19,20} Some investigators believe that this fusion may have biomechanical effects such as loss of motion at the fused segments and increase in the rate of degeneration of the adjacent unfused segment, especially in active and young patients.^{21,22} Nevertheless, in cases without degenerative changes, reconstruction and direct repair of the pars interarticularis seem a logical and less aggressive approach and can stabilize the motion segment with compression across the bone grafted defect to increase and ensure better fusion.^{23,24}

In order to treat congenital anomalies, conservative measures are often successful but those who remain symptomatic may benefit of pedicle screws and PLIF. We report a symptomatic case and the outcome of treatment.

Case Report

A 51-year-old man presented to our university hospital (Logh-

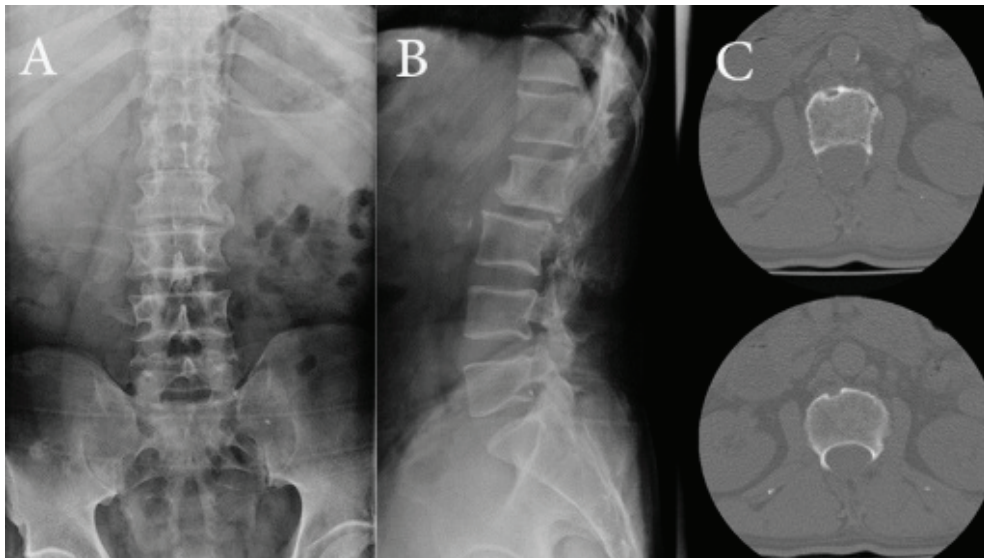


Figure 1. Plain radiographs of the lumbar spine. Anteroposterior (A) and lateral (B) views show instability in L2 and L3. Axial computed tomography (CT) image (C) reveals evidence of agenesis of the pars interarticularis, spinous processes, lamina, transverse processes and facets at L2 and partial L3.

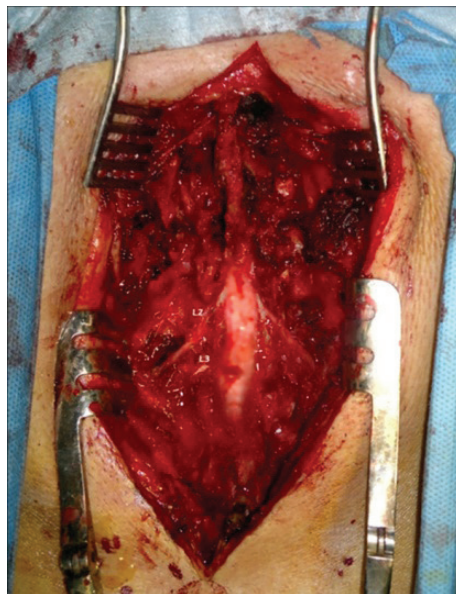


Figure 2. Intraoperative views of the procedure, L1-L4 vertebra are exposed and L2 roots are evident.

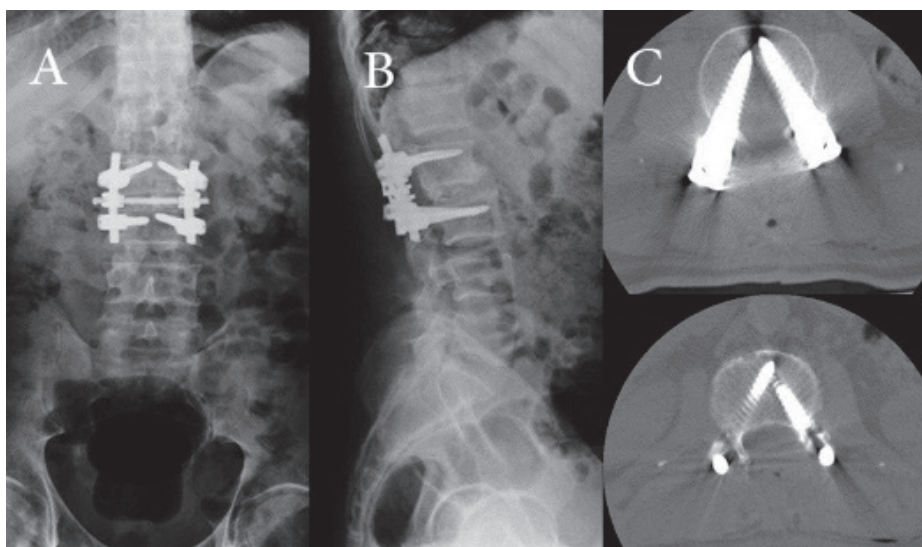


Figure 3. Postoperative anteroposterior and lateral radiographs, two rods, and one cross link are used.

man Hakim, Shahid Beheshti University of Medical Sciences) with a history of 20 years of back pain. The patient's pain had worsened considerably since the past 3 months radiating into the left lower limb through L2 and L3 spinal root pathway (anterior part of the thigh through the knee). The patient's pain was constant and worsened with activity while it was alleviated with rest. On physical examination, there was no skin anomaly, sphincter dysfunction or focal neurological complication. Also, the limbs' strength and reflexes were normal.

Imaging (Lumbosacral dynamic X-ray and CT scan) (Figure 1) showed instability in L2 and L3. There was evidence of retrolisthesis, agenesis of pars interarticularis, spinous processes, lamina, transverse processes and facets at L2 and partial L3. Laboratory tests, including WBC, Quantitative CRP, ESR, and Viral Markers were completely normal. Whole body bone scan, abdominopelvic CT scan and sonography and urogenital studies showed no abnormality.

The patient's pain persisted after 6 months of conservative and medical treatments; therefore, surgery was performed under general anesthesia. We exposed L1 and L4 spinous processes completely (one level above and one level below the defect). Then, L2 and L3, the vertebrae without posterior part (facet, lamina and spinous process), and their roots were exposed (Figure 2). The lesion in L2 and L3 was a congenital defect and there was no bony or cartilaginous structure in the posterior part of the spinal column and thecal sac, dura and roots were completely intact (Figure 2). During the surgery, we obtained soft tissue and bone samples for pathological studies which showed no abnormality.

Posterior spinal fixation and instrumentation was then done using pedicle screw fixation. Four pedicle screws, two rods, and one cross link were employed to bilaterally fix the L2 and L3 and then we used autograft and allograft bone for interbody fusion, substitutes from iliac crest for posterior fusion. Postoperative CT scan and X-ray (Figure 3) were performed to confirm the adequate placement of the instrumentation, as shown in the graphic representation, and to accurately evaluate the final constructs.

The patient had no postoperative complications and no neurological compromise. He could walk without support and was discharged from the hospital after two days. At 6 and 12 and 24 months of postoperative follow-up, his leg and back pain had improved, and the patient did not need any analgesic for pain relief.

Discussion

Congenital absence of posterior elements of the vertebra in the lumbar spine is rare. Our review of the literature revealed only a few reported cases of incomplete congenital absence of posterior elements. In some cases, this complication has been reported at C2.^{1,25} Trivedi, *et al.* reported a 31-year-old woman who had complete absence of the pedicles, laminae and spinous process of the axis.²⁶ There are some documents that report the congenital absence of the lumbosacral articular facet joint.^{4,6,8} Yoshioka, *et al.* also reported a rare case of congenital absence of the L5-S1 facet joint.¹⁰ Complete congenital absence of the lumbar posterior element has been rarely reported in the literature. In this case, we reported a rare case with congenital absence of posterior element of lumbar vertebra, including facet joint, lamina and spinous process that produced back pain and did not respond to conservative treatment and persisted as a more chronic illness. Because the patient did not respond to conservative management, we believed there

was an indication for surgery.

Cases whose congenital anomalies lead to segmental instability are surgical fusion candidates, but if these anomalies occur in pars interarticularis such as spondylolysis isthmus, fixation and intersegmental fusion techniques are useful.

Pars repair has been described in many studies using several techniques: Kimura in 1968, Buck's screw fixation in 1970, Morscher, *et al.* with hooks and screws in 1984, Scott's transverse process wiring in 1986, and others.^{25,27} Sairyo, *et al.* reported that the pedicle screw-V rod system directly repaired the isthmus of the vertebra and the procedure did not have an effect on adjacent vertebral segments and caused no injury to the diseased intervertebral disc.^{28,29} Also, the technique with two pedicle screws and bended rod was reported by Ulibarri, *et al.*³⁰ in a cadaver analysis and clinical study on five patients with a follow-up of 4.6 years. The biomechanical findings were promising and the clinical improvement was satisfactory.

In conclusion, complete congenital absence of lumbar posterior element has been rarely reported in the literature. Patients whose congenital anomalies lead to segmental instability are surgical fusion candidates. In this case report, we present a rare case without posterior elements in L2 and partial L3 who underwent posterior spinal fixation and posterolateral fusion. The intraoperative picture shows the precise type of surgery, with excellent over-bridging of the defect zone. The clinical outcome was satisfactory, with improvement in the functional status of the patient and pain level and progress during follow-up.

Conflict of interest

All authors certify that they have NO affiliations with or involvement in any organization or entity with any financial interest or non-financial interest in the subject matter or materials discussed in this manuscript.

"There is no funding or conflict of interest"

"There is no financial disclosures"

References

- Asakawa H, Yanaka K, Narushima K, Meguro K, Nose T. Anomaly of the axis causing cervical myelopathy. Case report. *J Neurosurg.* 1999; **91(1 Suppl)**: 121 – 123.
- O'Rahilly R, Müller F, Meyer DB. The human vertebral column at the end of the embryonic period proper. 2. The occipitocervical region. *J Anat.* 1983; **136(Pt 1)**: 181 – 195.
- VanGilder JC, Menezes AH, Dolan KD. The craniovertebral junction and its abnormalities. New York; Mount Kisco: Futura Publishing Company; 1987.
- Arcomano JP, Karas S. Congenital absence of the lumbosacral articular processes. *Skeletal Radiol.* 1982; **8(2)**: 133 – 134.
- Downey EF Jr, Whiddon SM, Brower AC. Computed tomography of congenital absence of posterior elements in the thoracolumbar spine. *Spine (Phila Pa 1976).* 1986; **11(1)**: 68 – 71.
- Ikedo K, Nakayama Y, Ishii S. Congenital absence of lumbosacral articular process: report of three cases. *J Spinal Disord.* 1992; **5(2)**: 232 – 236.
- Keim HA, Keagy RD. Congenital Absence of Lumbar Articular Facets A report of three cases. *J Bone Joint Surg Am.* 1967; **49(3)**: 523 – 526.
- Klinghoffer L, Murdock MG, Hermel MB. Congenital absence of lumbar articular facets: report of two cases. *Clin Orthop Relat Res.* 1975; **(106)**: 151 – 154.
- Lotan R, Al-Rashdi A, Yee A, Finkelstein J. Clinical features of conjoined lumbosacral nerve roots versus lumbar intervertebral disc herniations. *Eur Spine J.* 2010; **19(7)**: 1094 – 1098.
- Yoshioka S, Sairyo K, Sakai T, Yasui N. Congenital absence of lumbo-

- sacral articular facet joint associated with conjoined nerve root: a case report. *J Orthop Traumatol.* 2010; **11(3)**: 183 – 187.
11. Herman MJ, Pizzutillo PD, Cavalier R. Spondylolysis and spondylolisthesis in the child and adolescent athlete. *Orthop Clin North Am.* 2003; **34(3)**: 461 – 467.
 12. Steiner ME, Micheli LJ. Treatment of symptomatic spondylolysis and spondylolisthesis with the modified Boston brace. *Spine.* 1985; **10(10)**: 937 – 943.
 13. Ghiselli G, Wang JC, Bhatia NN, Hsu WK, Dawson EG. Adjacent segment degeneration in the lumbar spine. *J Bone Joint Surg Am.* 2004; **86-A(7)**: 1497 – 1503.
 14. Spruit M, Van Jonbergen JP, De Kleuver M. A concise follow-up of a previous report: posterior reduction and anterior lumbar interbody fusion in symptomatic low-grade adult isthmic spondylolisthesis. *Eur Spine J.* 2005; **14(9)**: 828 – 832.
 15. Bonnici A, Koka S, Richards D. Results of Buck screw fusion in grade I spondylolisthesis. *J R Soc Med.* 1991; **84(5)**: 270 – 273.
 16. Nicol RO, Scott JH. Lytic spondylolysis. repair by wiring. *Spine.* 1986; **11(10)**: 1027 – 1030.
 17. Songer MN, Rovin R. Repair of the Pars Interarticularis Defect With a Cable-Screw Construct: A Preliminary Report. *Spine.* 1998; **23(2)**: 263 – 269.
 18. Shin MH, Ryu KS, Rathi NK, Park CK. Direct Pars Repair Surgery Using Two Different Surgical Methods: Pedicle Screw with Universal Hook System and Direct Pars Screw Fixation in Symptomatic Lumbar Spondylosis Patients. *J Korean Neurosurg Soc.* 2012; **51(1)**: 14 – 19.
 19. Gillet P, Petit M. Direct repair of spondylolysis without spondylolisthesis, using a rod-screw construct and bone grafting of the pars defect. *Spine.* 1999; **24(12)**: 1252 – 1256.
 20. Teplick JG, Laffey PA, Berman A, Haskin ME. Diagnosis and evaluation of spondylolisthesis and/or spondylolysis on axial CT. *AJNR Am Soc Neuroradiol.* 1986; **7(3)**: 479 – 491.
 21. Lehmann TR, Spratt KF, Tozzi JE, Weinstein JN, Reinartz SJ, el-Khoury GY, et al. Long-term follow-up of lower lumbar fusion patients. *Spine (Phila Pa 1976).* 1987; **12(2)**: 97 – 104.
 22. Miyakoshi N, Abe E, Shimada Y, Okuyama K, Suzuki T, Sato K. Outcome of one-level posterior lumbar interbody fusion for spondylolisthesis and postoperative intervertebral disc degeneration adjacent to the fusion. *Spine.* 2000; **25(14)**: 1837 – 1842.
 23. Deguchi M, Rapoff AJ, Zdeblick TA. Biomechanical comparison of spondylolysis fixation techniques. *Spine (Phila Pa 1976).* 1999; **24(4)**: 328 – 333.
 24. Louis R. Pars interarticularis reconstruction of spondylolysis using plates and screws with grafting without arthrodesis. Apropos of 78 cases. *Rev Chir Orthop Reparatrice Appar Mot.* 1988; **74(6)**: 549 – 557.
 25. Koyama T, Tanaka K, Handa J. A rare anomaly of the axis: report of a case with shaded three-dimensional computed tomographic display. *Surg Neurol.* 1986; **25(5)**: 491 – 494.
 26. Trivedi P, Vyas KH, Behari S. Congenital absence of the posterior elements of C2 vertebra report: a case. *Neurol India.* 2003; **51(2)**: 250 – 251.
 27. Morscher E, Gerber B, Fase J. Surgical treatment of spondylolisthesis by bone grafting and direct stabilization of spondylolysis by means of a hook screw. *Arch Orthop Trauma Surg.* 1984; **103(3)**: 175 – 178.
 28. Sairyo K, Goel VK, Faizan A, Vadapalli S, Biyani S, Ebraheim N. Buck's direct repair of lumbar spondylolysis restores disc stresses at the involved and adjacent levels. *Clin Biomech.* 2006; **21(10)**: 1020 – 1026.
 29. Teplick J, Laffey P, Berman A, Haskin M. Diagnosis and evaluation of spondylolisthesis and/or spondylolysis on axial CT. *Am J Neuroradiol.* 1986; **7(3)**: 479 – 491.
 30. Ulibarri JA, Anderson PA, Escarcega T, Mann D, Noonan KJ. Biomechanical and clinical evaluation of a novel technique for surgical repair of spondylolysis in adolescents. *Spine.* 2006; **31(18)**: 2067 – 2072.