

Original Article

Impact of Whole Exome Sequencing among Iranian Patients with Autosomal Recessive Retinitis Pigmentosa

Maryam Beheshtian MD MPH¹, Samira Saeed Rad PhD^{2,3}, Mojgan Babanejad MSc¹, Marzieh Mohseni MSc¹, Hassan Hashemi MD³, Arash Eshghabadi MD³, Fedra Hajizadeh MD³, Mohammad Reza Akbari MD PhD^{4,5}, Kimia Kahrizi MD¹, Mohammad Riazi Esfahani MD³, Hossein Najmabadi PhD¹

Abstract

Background: Non-syndromic autosomal recessive Retinitis Pigmentosa (arRP) is a highly heterogeneous genetic visual disorder with a large number of causative genes. We aimed to determine the power of Whole Exome Sequencing (WES) in the identification of the genes responsible for non-syndromic arRP among Iranian patients.

Methods: We used WES, followed by the Sanger sequencing to identify the underlying gene mutations causing non-syndromic arRP.

Results: Our study revealed disease-causing mutations in known arRP genes for 10 of the 13 families studied (76.9%). These mutations included two-frameshift insertion/deletion in *CRB1* and *ABCA4*, one splicing mutation in *PDE6B*, four missense mutations in *RP1*, *CRB1*, *PANK2* and *IFT140*, as well as three stop codon mutations in *RDH12*, *PRCD*, and *C2orf71*. Three remaining families harbored no mutation in previously known RP genes. Of the 10 diseases causing mutations identified among the investigated Iranian patients with non-syndromic arRP, eight variants had not been reported previously. We confirmed segregation of all 10 mutations with disease phenotypes in our studied population.

Conclusion: This study supports the genetic heterogeneity of non-syndromic arRP in Iranian patients, and provides an opportunity to show the effectiveness of WES in the identification of pathogenic mutations among patients with non-syndromic arRP born to consanguineous parents.

Keywords: Autosomal recessive, consanguinity, Iran, non-syndromic, retinitis pigmentosa, whole exome sequencing.

Cite this article as: Beheshtian M, Saeed Rad S, Babanejad M, Mohseni M, Hashemi H, Eshghabadi A, Hajizadeh F, Akbari MR, Kahrizi K, Riazi Esfahani M, Najmabadi H. Impact of whole exome sequencing among Iranian patients with autosomal recessive retinitis pigmentosa. *Arch Iran Med.* 2015; **18(11)**: 776 – 785.

Introduction

Retinitis pigmentosa (RP) is a clinically and genetically heterogeneous group of inherited retinal degenerations that cause blindness in humans. RP has a worldwide prevalence of 1 case per 3000 persons to 1 case per 7000 persons.^{1,2} Progressive degeneration of the retina, typically start in the mid-periphery and advancing toward the macula and fovea. Nyctalopia followed by restriction of visual fields, leading to tunnel vision and finally complete blindness, are typical symptoms in RP patients. Although retinal changes start in the early teenage years, severe visual defects occur at ages of 40 to 50 years. However, early-onset RP such as Leber congenital amaurosis (LCA) and other late-onset forms have been reported.²

In some patients, a useful predictor of severity of RP is the underlying genetic cause, but the phenotype alone is not a reliable

predictor for the disease causing gene or mutation. Thus, the combination of clinical testing and molecular diagnosis of RP is the most powerful approach to resolve the complexity, eventually leading to diagnosis, treatment and prevention.² RP genetic mutations are transferred under different modes of inheritance including autosomal dominant, recessive, and X-linked, which account for 30%, 20% and 15% of cases, respectively.² Simplex or isolated RP accounts for about 35% of the remaining cases, probably including many recessive cases where there is only one affected individual in the family, but *de novo* mutations have also been reported in these cases.^{3,4} Some rare digenic and mitochondrial forms of the disease have also been described. RP can also be classified into non-syndromic, with no additional signs, and syndromic types as part of more complex disorders involving multiple organs and pleiotropic effects.²

Non-syndromic RP is the most frequent form of RP accounting for around 65% of all RP cases.^{1,2,5} To date, over 200 genes underlying retinal diseases have been reported (RETnet web site: <http://www.sph.uth.tmc.edu/RetNet/>). Vast efforts using various methods have contributed enormously to unraveling pathogenic mutations responsible for RP. Among them, linkage analysis in large extended families uses genetic markers to localize the causal gene mutation to a locus,⁶⁻¹¹ followed by different sequencing strategies to detect the underlying candidate genes.^{12,13}

Massively parallel next-generation sequencing (NGS), as a promising technology to detect disease-causing mutations associated with monogenic disorders,¹⁴⁻¹⁹ has been revolutionary in

Authors' affiliations: ¹Genetics Research Center, University of Social Welfare and Rehabilitation Sciences, Tehran, Iran, ²Dietary Supplements and Probiotic Research Center, Alborz University of Medical Sciences, Karaj, Iran, ³Noor Ophthalmology Research Center, Noor Eye Hospital, Tehran, Iran, ⁴Women's College Research Institute, Women's College Hospital, University of Toronto, Toronto, ON, Canada, ⁵Canada and Dalla Lana School of Public Health, University of Toronto, Toronto, ON, Canada.

Corresponding author and reprints: Hossein Najmabadi PhD, Genetics Research Center, University of Social Welfare and Rehabilitation Sciences, Koodakyar Alley, Daneshjoo Blvd., Evin St., Tehran, Iran. Postal Code: 1985713834. Tel: +98-21-22180138, E-mail: hnajm12@yahoo.com.

Accepted for publication: 22 September 2015

terms of turnaround time and cost for generating large quantities of sequence data. Due to its high throughput and low cost, it has been very attractive to use the NGS for gene discovery and mutation identification, particularly in highly heterogeneous monogenic diseases including RP. Iran, as a country with a high rate of consanguineous marriages (~40%), provides an appropriate platform to study gene mutations causing arRP.²⁰ To assess whether massively parallel NGS is an efficient option for arRP mutation identification in a community with a high consanguinity rate, we performed WES for probands of 13 arRP families using an Illumina HiSeq2500 sequencing system (Illumina, San Diego, CA, USA).

Materials and Methods

Subjects

The patients were a subset of family members with a high likelihood of having arRP, based on their pedigree analysis (Supplementary Figure 1). Thirteen Iranian families with a minimum of one child affected with non-syndromic arRP were selected from all around the country for this study. Detailed clinical and ophthalmic examinations comprising slit-lamp biomicroscopy, funduscopy, optical coherence tomography (OCT), and electroretinography (ERG), if applicable, have been carried out to diagnose RP. The study was approved by the National Iranian Ethics Committee for Medical Genetic Research. We obtained written informed consent from all study subjects.

Whole exome sequencing

Genomic DNA was isolated from peripheral blood leukocytes using standard methods. The Agilent SureSelect Human All Exon kit (V5) was used to capture sequence target regions. The captured regions for each sample were bar-coded. Every four samples were pooled and used for paired-end sequencing for 100 cycles (generating 100 bp reads) on a single lane of the flow cell in the Illumina HiSeq2500 sequencing system.

The sequence reads for each exome sequence of each individual were aligned to the reference sequence of the human genome (hg19, NCBI Build 37) using the Burrows-Wheeler Aligner (V7.10).²¹ The mean depth of coverage was 71× (range 57× to 86×). On average, 94.7% (range 94.1% to 95.3%) of the Consensus Coding Sequence (CCDS) exons were covered at 12 × depth of coverage and higher which was used for variant calling. The Unified Genotyper module of the Genome Analysis Toolkit (GATK) version 3.3.0,²² was used for calling both Single Nucleotide Polymorphisms (SNPs) and indels. The SNP & Variation Suite (GoldenHelix Inc., Bozeman, MT, USA) was used for annotating variants called.

Variants within 245 known retinal diseases genes (Supplementary Tables 1 and 2) in each patient were identified and those with a minor allele frequency of more than 1% in NHLBI exome sequence data (<http://evs.gs.washington.edu/EVS/>), G1000 project (<http://www.1000genomes.org/>)²³ and also 300 in-house Iranian exome sequencing data were excluded. Since twelve out of the 13 patients were from consanguineous families, first we focused on homozygous variants and those that truncate the protein (insertions, deletions and stop codon mutations) and variants on the consensus splice site, which are more likely to be dysfunctional. If we did not see any of those mutations in a patient, then we also looked for a causal candidate gene among missense mutations. The dbNSFP database was used to predict the functional effect of

the missense mutations.²⁴

Segregation analysis

For mutation confirmation and segregation analysis, we designed specific primers for Polymerase Chain Reaction (PCR) amplification of identified candidate causal mutations in each patient. We used Primer3 (v. 0.4.0) software (<http://frodo.wi.mit.edu/primer3/>) to design PCR primers.

PCR amplicons were sequenced directly on an ABI 3130 Automated Capillary DNA Sequencer using the Big Dye Terminator v3.1 Cycle Sequencing Kit (Applied Biosystems, Foster City, CA, USA). The sequencing results were analyzed by Codon Code Aligner Software. Reference sequences of all these genes have been recorded in Tables 2 and 3.

Results

Clinical characteristics of the patients

One affected individual from each of the 13 families was subjected to WES and mutation screening for 245 known retinal diseases genes. Twelve out of the 13 families (92.3%) had consanguineous marriages. Eight of the probands had an early-onset diagnosis of RP.

All proband individuals underwent more detailed ophthalmological evaluations. From the slit lamp analysis, we identified posterior subcapsular cataract or posterior subcapsular opacification in 4 out of 13 (30.8%) probands. Fundus examination showed RP in all probands. Of 12 probands, 9 had vision of hand motion. All three probands who underwent an optical coherence tomography (OCT) test demonstrated macular atrophy or cystoid macular edema. Nasolacrimal duct obstruction, respiratory difficulties and infertility were found in 1 out of the 13 families studied. An individual affected with Stargardt disease was found among our investigated families.

Identifying causal mutations

After exome sequencing and focusing on rare homozygous mutations within 245 known retinal diseases genes, candidate causal mutations were identified in 10 of the 13 patients studied. These included two frameshift insertion/deletions, three stop codon mutations, one splicing site mutation and four missense mutations. These mutations were located in nine different known RP genes (Tables 2 and 3).

For these three remaining families, no potentially pathogenic homozygous or compound homozygous variants were found within 245 known retinal diseases genes. For those samples, we checked the variants identified within 624 genes mainly expressed in the eye, and found no homozygous variants.

All of these 10 homozygous variants were confirmed by Sanger sequencing and showed co-segregation in related families. Two known stop codon mutations were found in two of the 13 families investigated. These included *RDH12* p.Arg62* and *PRCD* p.Arg22*. None of these 10 mutations have been seen among 300 in-house Iranian exome sequencing data. All four missense mutations were predicted to be dysfunctional by dbNSFP.

Discussion

RP is known to be one of the most prevalent causes of inherited visual dysfunction in humans. Up to now, mutations in over 200

genes have been found to be responsible for retinal diseases.²⁵

In this study, we investigated frequently mutated arRP genes to identify disease-causing mutations among 13 Iranian families with non-syndromic arRP (Table 1). Overall, we identified 10 different mutations among nine known disease-causing arRP genes, with various functions such as encoding rod and cone photoreceptor Rim protein (*ABCA4*), regeneration of the cone visual pigments (*RDH12*), encoding a key enzyme involved in the visual phototransduction cascade (*PDE6B*), and regulating the stability and length of the microtubule-based axoneme of photoreceptors (*RPI*). *CRB1* involves in photoreceptor morphogenesis in the retina and *PANK2* plays a role in the regulation of coenzyme A biosynthesis. *C2orf71* and *PRCD* have different roles in normal vision (Tables 2 and 3).

In this study, we found a novel frameshift deletion variant in the *ABCA4* gene in one of the families investigated. The phenotypic features of our family included Stargardt disease and bilateral RP, each in an affected sibling. Previously reported studies have shown that various types of *ABCA4* mutations have contributed in nearly two-thirds of autosomal recessive cone-rod dystrophy and some forms of Stargardt disease. It accounts for about 2% – 5% of arRP.^{26–29}

A novel splicing site variant in exon 8 of *PDE6B* gene was found in a family with non-syndromic arRP in our study. Fundus examination of affected individuals revealed bilateral RP. This splicing site was found to be a disease causing variant based on the dbNSFP database. *PDE6B* mutations have been reported in 2% – 5% of patients with arRP.²⁹

RDH12 heterozygous mutations mainly result in a relatively mild and a late onset autosomal dominant RP.³⁰ In accordance with our findings, Chacon-Camacho, et al. reported an *RDH12* mutation causing arRP.³⁰ Age at onset of disease in our investigated individuals was around 13 years and our fundoscopic examination showed bilateral RP. Although a known stop codon mutation c.184C>T has been reported previously in patients with recessive Leber congenital amaurosis, our result confirmed that this mutation can also lead to non-syndromic arRP. It may implicate the wide variability of phenotype among RP cases harboring this mutation. In accordance with our findings, Janecke, et al. (2004) reported mutations in *RDH12* in 3 out of 89 non-Austrian patients with retinal dystrophy. They found a compound heterozygous mutation (c.146C>T and c.184C>T) in 1 out of 3 patients harboring mutations in *RDH12*.³¹

PRCD gene mutations contribute in nearly 1% of RP cases, mostly the late-onset form.^{29,32,33} Nevet, et al. screened 24 patients with RP from an Israeli Muslim Arab village and identified a pathogenic homozygous nonsense mutation (c.64C>T, p.R22X) in *PRCD*, which might suggest a founder effect.³⁴ Interestingly, our study revealed this known stop codon mutation in a Persian family with the late-onset form of non-syndromic arRP.

CRB1 mutations, have been known to be responsible for 6% – 7% of arRP cases among Spanish populations.³⁵ However, in our study *CRB1* mutations were found in 2 out of 13 families with RP. These gene mutations have been found in a variety of retinal dystrophy with autosomal recessive mode of inheritance such as LCA, RP with preserved paraarteriolar retinal pigment epithelium, RP with Coats-like exudative vasculopathy, and early onset RP without preserved paraarteriolar retinal pigment epithelium.³⁶ Our study revealed two novel variants in this gene, including a missense mutation (p.Cys904Tyr) in exon 11, and a

frameshift insertion (c.1252dup) in exon 8, among two families with early-onset non-syndromic arRP. The p.Cys904Tyr mutation is predicted by dbNSFP to be disease causing.

Mutations in *PANK2* have mainly been associated with an autosomal recessive form of neurodegeneration disorder characterized by mental retardation, motor symptoms, RP and brain iron accumulation as well as pallidal degeneration (HARP syndrome; hypoprebetalipoproteinemia, acanthocytes, and Retinitis Pigmentosa).³⁷ *PANK2* encodes a protein which is a key enzyme involved in regulation of the biosynthesis of CoA, metabolism of neurotransmitters and glutathione, energy metabolism, fatty acid synthesis and degradation.³⁸ In our study, c.419T>C (p.Phe140Ser) mutation was seen in one patient with late-onset, non-syndromic arRP. This novel variant is predicted to be disease causing by dbNSFP.

C2orf71 gene, with a high expression in photoreceptors, plays an important role in the development of normal vision. Mutations in this gene are responsible for around 1% of arRP (RP54).^{29,39} Our study revealed a novel disease causing stop codon variant in exon 1 of *C2orf71* causing late-onset non-syndromic arRP in 1 out of 13 families investigated.

In this study, a novel missense variant in exon 3 of *RPI* gene was found in a family with non-syndromic arRP. This missense was found to be a disease-causing variant based on the dbNSFP database.

IFT140 is one of the genes involved in intraflagellar transport,⁴⁰ which is a highly conserved process with a critical role in ciliary formation, signaling and maintenance.^{41,42} Mutations in this gene lead to the syndromic or systemic autosomal recessive diseases with retinopathy, mainly categorized as short-rib thoracic dysplasia-9 with or without polydactyly (SRTD9) [MIM#266920]. It encompasses short rib-polydactyly syndrome (SRPS), Mainzer-Saldino syndrome (MZSDS),⁴³ Jeune syndrome or asphyxiating thoracic dystrophy (ATD), and Ellis-van Creveld syndrome (EVC). Mainzer-Saldino syndrome is mainly characterized by early-onset retinal dystrophy, phalangeal cone-shaped epiphyses, and renal disease,⁴³ and Jeune asphyxiating thoracic dysplasia is a severe skeletal ciliopathy disorder with shortened ribs and a barrel chest restricting lung growth.⁴³ Retinal dystrophy has been identified as the universal phenotype with recessive mutations in *IFT140* recognized as the first sign in an affected individual.⁴³ The protein which is encoded by *IFT140* gene contains 1462 amino acids with three domains and 14 repeats including 5 WD and 9 TPR (tetratricopeptide repeat region). The vast majority (nine out of 10) of mutations causing SRTD9 were positioned among the WD repeats, particularly WD4 repeat (see <http://www.uniprot.org/>). Perrault, et al. (2012) found that six out of seven homozygous and compound-heterozygous *IFT140* mutations causing skeletal ciliopathies, affected WD repeats.⁴⁰ Furthermore, disease-causing mutations in the *Ifi140* gene in *Cauli* as a novel mouse model for ciliopathy had altered WD repeats.⁴⁴

Our novel predicted pathogenic missense variant in *IFT140* (c.3827G>A, p.Gly1276Glu) co-segregates with late-onset arRP in 1 of the 13 families investigated. This variant is positioned between TPR8 and TPR9 repeats. Generally, the tetratricopeptide repeat region (TPR), as a structural motif present in a wide variety of proteins,⁴⁵ plays a role in protein-protein interactions and the gathering of multiprotein complexes.⁴⁶ TPR acquires a helix-turn-helix arrangement, with a specific packing angle between helix A and helix B making a right-handed superhelical configuration.⁴⁶ By altering the packing angle, our novel variant

Table 1. Clinical information for 13 Iranian families with arRP

Family ID	Sex	Age (years)	Age of onset (years)	Symptoms	Macula/Retina	Optic disc	Lens	Visual acuity	Family history	Additional features	Inheritance
9200030 I-39280	F	34	10	Near-Blindness	Normal/RP	Normal	PSC	HM	+	---	AR
9200031 I-39300	M	42	13-14	Nyctalopia	Macular atrophy/ RP	Normal	Clear	NA	+	---	AR
9200032 I-39320	F	21	7	Nyctalopia, Tunnel vision, Near- Blindness	Normal/End stage RP	Pale	Clear	HM	+	---	AR
9200033 I-39340	M	42	13	Near-Blindness	Normal/RP	Normal	Clear	LP	+	strabismus	AR
9200034 I-39360	M	35	28	Near-Blindness	Macular atrophy /Cone rod dystrophy(OD),RP (OS)	Normal	PSC	CF	+	---	AR
9200035 I-39380	M	42	38	Near-Blindness	Normal/RP	Normal	Clear	HM	+	---	AR
9200036 I-39400	M	31	29-30	Near-Blindness	CME/RP	Normal	PSC	HM	+	nasolacrimal duct obstruction, infantile asthma, infertility	AR
9300040 I-40200	M	29	9	Near-Blindness	Normal/RP	Normal	Clear	CF	+	---	AR
9300042 I-40240	F	31	2	Near-Blindness	Normal/RP	Normal	Clear	HM	-	---	Sporadic
9300043 I-40260	M	18	2	Near-Blindness	Normal/RP	Normal	Clear	HM	-	---	Sporadic
9300044 I-40280	M	28	< 1	Near-Blindness	Normal/RP	Normal	Clear	HM	+	nystagmus	AR
9300045 I-40300	M	51	49	Near-Blindness	Normal/RP (advanced)	Pale	PCO	HM	+	---	AR
9300046 I-40320	M	31	23-24	Near-Blindness	Normal/RP	Normal	Clear	HM	+	---	AR

F: female; M: male; NA: not available; CME: cystoid macular edema; PCO: cataract; PSC: posterior capsular opacification; PSC: posterior capsular opacification; CF: count fingers; HM: hand motion; LP: light perception, OD: right eye; OS: left eye.

Table 2. Novel variants identified by whole exome sequencing among Iranian patients affected to arRP

Family ID	Gene	Exon#	Nucleotide change	Protein effect	Classification	MutationTaster
9200030	ABCA4 OMIM# 601691 RefSeq NM_000350	20	c.2927del	p.Leu976Argfs*55	Frameshift deletion	- - -
9200031	PDE6B OMIM# 180072 RefSeq NM_000283	8	c.1060-1G>T	- - -	Splice site	Disease causing
9200035	RP1 OMIM# 603937 RefSeq NM_006269	3	c.679T>G	p.Phe227Val	Missense	Disease causing
9200036	IFT140 OMIM# 614620 RefSeq NM_014714	28	c.3827G>A	p.Gly1276Glu	Missense	Disease causing
9300042	CRB1 OMIM# 604210 RefSeq NM_001257965	11	c.2711G>A	p.Cys904Tyr	Missense	Disease causing
9300043	CRB1 OMIM# 604210 RefSeq NM_001257965	8	c.1252dup	p.Ser418Phefs*3	Frameshift insertion	- - -
9300045	PANK2 OMIM# 606157 RefSeq NM_024960	4	c.419T>C	p.Phe140Ser	Missense	Disease causing
9300046	C2orf71 OMIM# 613425 RefSeq NM_001029883	1	c.712A>T	p.Lys238*	Stop codon	Disease causing

Table 3. Known mutations detected by whole exome sequencing among Iranian patients affected to arRP

Family ID	Gene	Exon#	Nucleotide change	Protein effect	Classification
9200033	RDH12 OMIM# 608830 RefSeq NM_152443	4	c.184C>T	p.Arg62*	Stop codon
9200034	PRCD OMIM# 610598 RefSeq NM_001077620	1	c.64C>T	p.Arg22*	Stop codon

may interfere with the function of this gene. So far, Perrault, et al.⁴⁰ and Schmidts, et al.⁴² have reported disease-causing mutations (p.Ala1306Glyfs*56 and p.Cys1360Arg, respectively) located between TPR8 and TPR9 repeat regions.

Two affected individuals in this family reported nasolacrimal duct obstruction and infertility. One affected individual had a history of infantile asthma. Funduscopic examination showed bilateral RP and cystoid macular edema (CME). To the best of our knowledge, this phenotype has not previously been reported to be associated with *IFT140* mutations and may reflect the genetic and clinical heterogeneity in ciliopathy disorders.⁴²

Using WES, we are able to identify this heterogeneous spectrum of disease-causing arRP gene mutations in a country with a high rate of consanguineous marriages. Recessive mutations in genes causing retinal dystrophy that are found in both consanguineous parents might be easily inherited to offspring in the homozygous form.⁴⁷⁻⁵¹ Although disease phenotypes overlap and lack of knowledge on the phenotype-genotype correlations makes identification of genes causing RP more challenging, high throughput DNA sequencing brings advances in detection of RP gene mutations.⁵²⁻⁵⁶ We identified disease attributable mutations in 76.9%

of our non-syndromic arRP patients. This approach has recently been used by other researchers to identify known and novel mutations causing RP.^{57,58}

Fu, et al. recruited 31 well-characterized arRP families, extracting DNA samples from one affected member. They used their custom capture panel, comprising 163 retinal disease genes and achieved a diagnostic rate of approximately 40%. Notably, around 63% of their pathogenic mutations were novel.⁵⁹

Moreover, to define the genetic causes underlying 20 Chinese families affected with autosomal recessive Inherited Retinal Dystrophies (IRD), Liu, et al. used NGS. Their targeted sequence capture of IRD-relevant genes applied two in-house-designed microarrays and followed by NGS. Finally, they determined homozygous and biallelic variants in 11 of the 20 families (55%) as very likely disease-causing mutations. Their results supported genetic evaluations using targeted NGS to improve genetics and clinical diagnosis.⁶⁰

In fact, using NGS to identify RP disease-causing genes, particularly among patients with autosomal dominant form of RP, led to a detection rate ranging from 40% to 70%.⁶¹⁻⁶³ Overall, these findings support NGS as a robust,⁶⁴ economic, and accurate^{63,65}

method which can be applied as a promising tool for identification of gene mutations causing RP.

In conclusion, developing an accurate molecular diagnostic method is essential for disease characterization and clinical prognosis in patients with RP. To the best of our knowledge, this is the first study applying WES-based, comprehensive molecular diagnosis to Iranian families with non-syndromic arRP with a 76.9% detection rate. These data from a country with a high consanguineous marriage rate may provide supporting evidence for the efficacy of WES in the precise identification of the molecular mutations in patients with arRP. An efficient method for molecular diagnosis can improve clinical diagnosis, potentially affecting treatment options, current systems of family counseling and management throughout the country.

Acknowledgment

We are grateful to the patients and their families for their participation in our study. We also thank Ms. Arzhangi and Ms. Jalalvand for their help in this study. We also wish to thank the clinicians who contributed to patient evaluation. This work was supported by research grants from University of Social Welfare and Rehabilitation Sciences with research grant number 801/zh/s/p/83 dated 18 January 2013.

Declaration of interest: The authors report no conflicts of interest. The authors alone are responsible for the content and writing of the paper.

References

- Haim M. Epidemiology of retinitis pigmentosa in Denmark. *Acta Ophthalmol Scand Suppl.* 2002; (233): 1 – 34.
- Daiger SP, Bowne SJ, Sullivan LS. Perspective on genes and mutations causing retinitis pigmentosa. *Arch Ophthalmol.* 2007; 125(2): 151 – 158.
- Bowne SJ, Sullivan LS, Mortimer SE, Hedstrom L, Zhu J, Spellicy CJ, et al. Spectrum and frequency of mutations in IMPDH1 associated with autosomal dominant retinitis pigmentosa and leber congenital amaurosis. *Invest Ophthalmol Vis Sci.* 2006; 47(1): 34 – 42.
- Schwartz SB, Aleman TS, Cideciyan AV, Swaroop A, Jacobson SG, Stone EM. De novo mutation in the RP1 gene (Arg677ter) associated with retinitis pigmentosa. *Invest Ophthalmol Vis Sci.* 2003; 44(8): 3593 – 3597.
- Heckenlively JR, ed. Retinitis Pigmentosa. Philadelphia, PA: JB Lippincott. 1988; 151 – 154.
- Lathrop GM, Lalouel JM, Julier C, Ott J. Strategies for multilocus linkage analysis in humans. *Proc Natl Acad Sci USA.* 1984; 81(11): 3443 – 3446.
- Sheffield VC, Nishimura DY, Stone EM. Novel approaches to linkage mapping. *Curr Opin Genet Dev.* 1995; 5(3): 335 – 341.
- Gold B, Merriam JE, Zernant J, Hancox LS, Taiber AJ, Gehrs K, et al. Variation in factor B (BF) and complement component 2 (C2) genes is associated with age-related macular degeneration. *Nat Genet.* 2006; 38(4): 458 – 462.
- Edwards AO, Ritter R, 3rd, Abel KJ, Manning A, Panhuysen C, Farrer LA. Complement factor H polymorphism and age-related macular degeneration. *Science.* 2005; 308(5720): 421 – 424.
- Haines JL, Hauser MA, Schmidt S, Scott WK, Olson LM, Gallins P, et al. Complement factor H variant increases the risk of age-related macular degeneration. *Science.* 2005; 308(5720): 419 – 421.
- Jakobsdottir J, Conley YP, Weeks DE, Mah TS, Ferrell RE, Gorin MB. Susceptibility genes for age-related maculopathy on chromosome 10q26. *Am J Hum Genet.* 2005; 77(3): 389 – 407.
- Mandal MN, Heckenlively JR, Burch T, Chen L, Vasireddy V, Koenekoop RK, et al. Sequencing arrays for screening multiple genes associated with early-onset human retinal degenerations on a high-throughput platform. *Invest Ophthalmol Vis Sci.* 2005; 46(9): 3355 – 3362.
- Service RF. Gene sequencing. The race for the \$1000 genome. *Science.* 2006; 311(5767): 1544 – 1546.
- Hartong DT, Berson EL, Dryja TP. Retinitis pigmentosa. *Lancet.* 2006; 368(9549): 1795 – 1809.
- Chizzolini M, Galan A, Milan E, Sebastiani A, Costagliola C, Parmeggiani F. Good epidemiologic practice in retinitis pigmentosa: from phenotyping to biobanking. *Curr Genomics.* 2011; 12(4): 260 – 266.
- Jin ZB, Huang XF, Lv JN, Xiang L, Li DQ, Chen J, et al. SLC7A14 linked to autosomal recessive retinitis pigmentosa. *Nat Commun.* 2014; 5: 3517 – 3525.
- Coppieters F, De Wilde B, Lefever S, De Meester E, De Rocker N, Van Cauwenbergh C, et al. Massively parallel sequencing for early molecular diagnosis in Leber congenital amaurosis. *Genet Med.* 2012; 14(6): 576 – 585.
- Huang XF, Xiang P, Chen J, Xing DJ, Huang N, Min Q, et al. Targeted exome sequencing identified novel USH2A mutations in Usher syndrome families. *PLoS One.* 2013; 8(5): e63832.
- Huang XF, Wu J, Lv JN, Zhang X, Jin ZB. Identification of false-negative mutations missed by next-generation sequencing in retinitis pigmentosa patients: a complementary approach to clinical genetic diagnostic testing. *Genet Med.* 2015; 17(4): 307 – 311
- Saadat M, Ansari-Lari M, Farhud DD. Consanguineous marriage in Iran. *Ann Hum Biol.* 2004; 31(2): 263 – 269.
- Li H, Durbin R. Fast and accurate short read alignment with Burrows-Wheeler transform. *Bioinformatics (Oxford, UK).* 2009; 25(14): 1754 – 1760.
- McKenna A, Hanna M, Banks E, Sivachenko A, Cibulskis K, Kernytsky A, et al. The Genome Analysis Toolkit: a MapReduce framework for analyzing next-generation DNA sequencing data. *Genome Res.* 2010; 20(9): 1297 – 1303.
- Abecasis GR, Altshuler D, Auton A, Brooks LD, Durbin RM, Gibbs RA, et al. A map of human genome variation from population-scale sequencing. *Nature.* 2010; 467(7319): 1061 – 1073.
- Liu X, Jian X, Boerwinkle E. dbNSFP v2.0: A Database of Human Non-synonymous SNVs and Their Functional Predictions and Annotations. *Hum Mutat.* 2013; 34(9): E2393 – E2402.
- Ferrari S, Di Iorio E, Barbaro V, Ponzin D, Sorrentino FS, Parmeggiani F. Retinitis pigmentosa: genes and disease mechanisms. *Curr Genomics.* 2011; 12(4): 238 – 249.
- Rudolph G, Kalpadakis P, Haritoglou C, Rivera A, Weber BH. Mutations in the ABCA4 gene in a family with Stargardt's disease and retinitis pigmentosa (STGD1/RP19). *Klin Monbl Augenheilkd.* 2002; 219(8): 590 – 596.
- Shastri BS. Evaluation of the common variants of the ABCA4 gene in families with Stargardt disease and autosomal recessive retinitis pigmentosa. *Int J Mol Med.* 2008; 21(6): 715 – 720.
- Cremer FP, Maugeri A, Klevering BJ, Hoefsloot LH, Hoyng CB. [From gene to disease: from the ABCA4 gene to Stargardt disease, cone-rod dystrophy and retinitis pigmentosa]. *Ned Tijdschr Geneesk.* 2002; 146(34): 1581 – 1584.
- Fahim AT, Daiger SP, Weleber RG. Retinitis Pigmentosa Overview 2000 [Updated 2013 Mar 21]. In: GeneReviews™ [Internet] (Pagon RA, Adam MP, Bird TD, et al., eds.). Seattle, WA: University of Washington, Seattle. 1993 – 2013. Available from: URL: <http://www.ncbi.nlm.nih.gov/books/NBK1417/>. (Accessed Date: October 3, 2013).
- Fingert JH, Oh K, Chung M, Scheetz TE, Andorf JL, Johnson RM, et al. Association of a novel mutation in the retinol dehydrogenase 12 (RDH12) gene with autosomal dominant retinitis pigmentosa. *Arch Ophthalmol.* 2008; 126(9): 1301 – 1307.
- Janecke AR, Thompson DA, Utermann G, Becker C, Hübner CA, Schmid E, et al. Mutations in RDH12 encoding a photoreceptor cell retinol dehydrogenase cause childhood-onset severe retinal dystrophy. *Nat Genet.* 2004; 36(8): 850 – 854.
- Zangerl B, Goldstein O, Philp AR, Lindauer SJ, Pearce-Kelling SE, Mullins RF, et al. Identical mutation in a novel retinal gene causes progressive rod-cone degeneration in dogs and retinitis pigmentosa in humans. *Genomics.* 2006; 88(5): 551 – 563.
- Pach J, Kohl S, Gekeler F, Zobor D. Identification of a novel mutation in the PRCD gene causing autosomal recessive retinitis pigmentosa in a Turkish family. *Mol Vis.* 2013; 19: 1350 – 1355.
- Nevet MJ, Shalev SA, Zlotogora J, Mazzawi N, Ben-Yosef T. Identification of a prevalent founder mutation in an Israeli Muslim Arab village confirms the role of PRCD in the aetiology of retinitis pigmentosa in humans. *J Med Genet.* 2010; 47(8): 533 – 537.

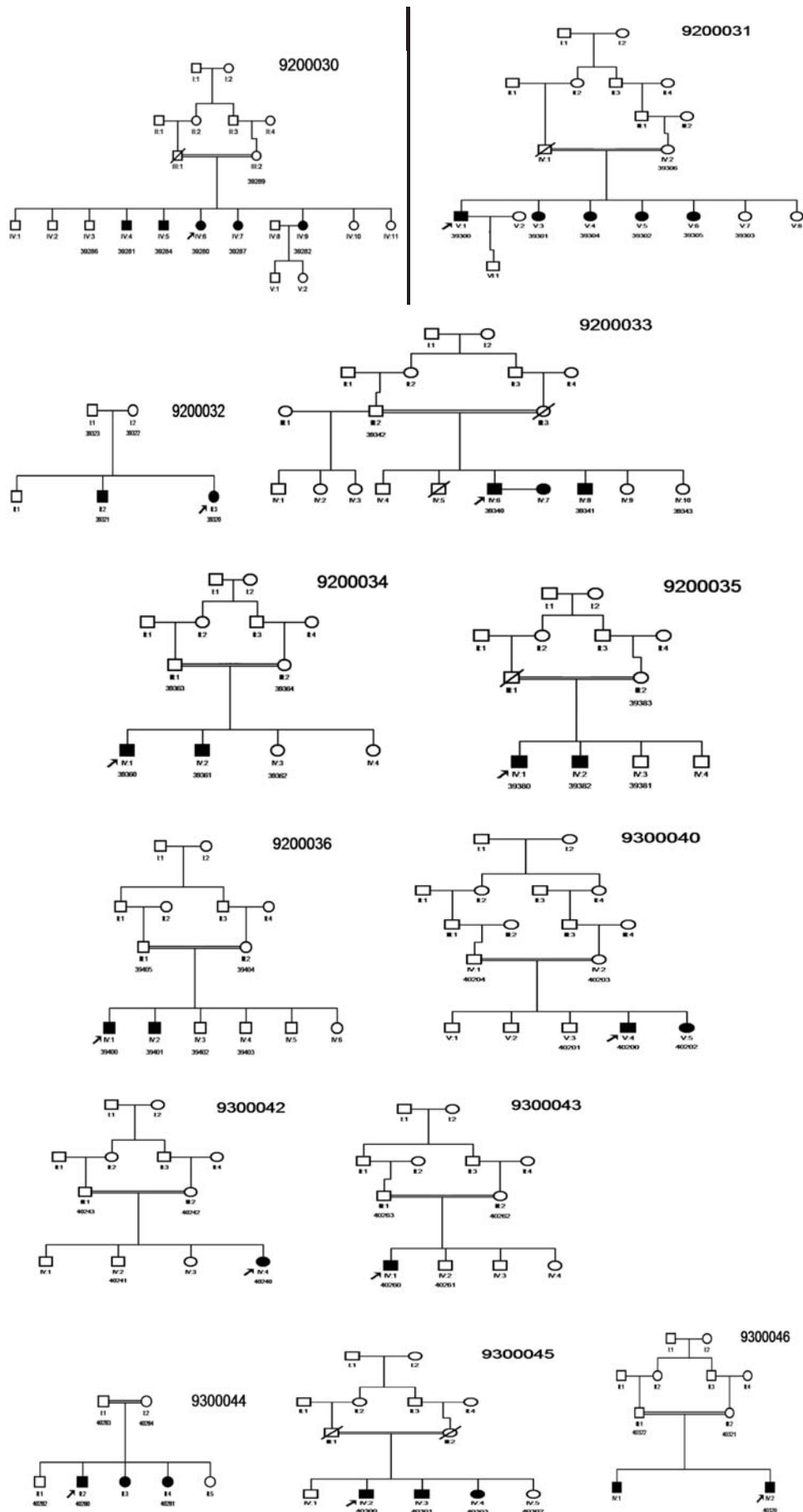
35. Vallespin E, Cantalapiedra D, Riveiro-Alvarez R, Wilke R, Aguirre-Lamban J, Avila-Fernandez A, et al. Mutation screening of 299 Spanish families with retinal dystrophies by Leber congenital amaurosis genotyping microarray. *Invest Ophthalmol Vis Sci.* 2007; 48(12): 5653 – 5661.
36. den Hollander AI, Heckenlively JR, van den Born LI, de Kok YJ, van der Velde-Visser SD, Kellner U, et al. Leber congenital amaurosis and retinitis pigmentosa with Coats-like exudative vasculopathy are associated with mutations in the crumbs homologue 1 (CRB1) gene. *Am J Hum Genet.* 2001; 69(1): 198 – 203.
37. Houlden H, Lincoln S, Farrer M, Cleland PG, Hardy J, Orrell RW. Compound heterozygous PANK2 mutations confirm HARP and Hallervorden-Spatz syndromes are allelic. *Neurology.* 2003; 61(10): 1423 – 1426.
38. Gregory A, Polster BJ, Hayflick SJ. Clinical and genetic delineation of neurodegeneration with brain iron accumulation. *J Med Genet.* 2009; 46(2): 73 – 80.
39. Gonzalez-del Pozo M, Mendez-Vidal C, Bravo-Gil N, Vela-Boza A, Dopazo J, Borrego S, et al. Exome sequencing reveals novel and recurrent mutations with clinical significance in inherited retinal dystrophies. *PLoS One.* 2014; 9(12): e116176.
40. Perrault I, Saunier S, Hanein S, Filhol E, Bizet AA, Collins F, et al. Mainzer-Saldino syndrome is a ciliopathy caused by IFT140 mutations. *Am J Hum Genet.* 2012; 90(5): 864 – 870.
41. Ishikawa H, Marshall WF. Ciliogenesis: building the cell's antenna. *Nat Rev Mol Cell Biol.* 2011; 12(4): 222 – 234.
42. Schmidts M, Frank V, Eisenberger T, Al Turki S, Bizet AA, Antony D, et al. Combined NGS approaches identify mutations in the intraflagellar transport gene IFT140 in skeletal ciliopathies with early progressive kidney disease. *Hum Mutat.* 2013; 34(5): 714 – 724.
43. Khan AO, Bolz HJ, Bergmann C. Early-onset severe retinal dystrophy as the initial presentation of IFT140-related skeletal ciliopathy. *J AAPOS.* 2014; 18(2): 203 – 205.
44. Miller KA, Ah-Cann CJ, Welfare MF, Tan TY, Pope K, Caruana G, et al. Cauli: a mouse strain with an Ift140 mutation that results in a skeletal ciliopathy modelling Jeune syndrome. *PLoS Genet.* 2013; 9(8): e1003746.
45. Das AK, Cohen PW, Barford D. The structure of the tetratricopeptide repeats of protein phosphatase 5: implications for TPR – mediated protein-protein interactions. *EMBO J.* 1998; 17(5): 1192 – 1199.
46. D'Andrea LD, Regan L. TPR proteins: the versatile helix. *Trends Biochem Sci.* 2003; 28(12): 655 – 662.
47. Razavi H, Kuper H, Rezvan F, Amelie K, Mahboobi-Pur H, Oladi MR, et al. Prevalence and causes of severe visual impairment and blindness among children in the lorestan province of Iran, using the key informant method. *Ophthalmic Epidemiol.* 2010; 17(2): 95 – 102.
48. Tabbara K, Badr I. Changing pattern of childhood blindness in Saudi Arabia. *Br J Ophthalmol.* 1985; 69(4): 312 – 315.
49. Baghdassarian S, Tabbara K. Childhood blindness in Lebanon. *Am J Ophthalmol.* 1975; 79: 827–830.
50. Elder MJ, De Cock R. Childhood blindness in the West Bank and Gaza Strip: prevalence, aetiology and hereditary factors. *Eye (Lond).* 1993; 7(Pt 4): 580 – 583.
51. Nishiguchi KM, Rivolta C. Genes associated with retinitis pigmentosa and allied diseases are frequently mutated in the general population. *PLoS One.* 2012; 7(7): e41902.
52. Ng SB, Buckingham KJ, Lee C, Bigham AW, Tabor HK, Dent KM, et al. Exome sequencing identifies the cause of a mendelian disorder. *Nat Genet.* 2010; 42(1): 30 – 35.
53. Khateb S, Zelinger L, Ben-Yosef T, Merin S, Crystal-Shalit O, Gross M, et al. Exome sequencing identifies a founder frameshift mutation in an alternative exon of USH1C as the cause of autosomal recessive retinitis pigmentosa with late-onset hearing loss. *PLoS One.* 2012; 7(12): e51566.
54. Tucker BA, Scheetz TE, Mullins RF, DeLuca AP, Hoffmann JM, Johnston RM, et al. Exome sequencing and analysis of induced pluripotent stem cells identify the cilia-related gene male germ cell-associated kinase (MAK) as a cause of retinitis pigmentosa. *Proc Natl Acad Sci USA.* 2011; 108(34): E569 – E576.
55. Wang Y, Guo L, Cai SP, Dai M, Yang Q, Yu W, et al. Exome sequencing identifies compound heterozygous mutations in CYP4V2 in a pedigree with retinitis pigmentosa. *PLoS One.* 2012; 7(5): e33673.
56. Zuchner S, Dallman J, Wen R, Beecham G, Naj A, Farooq A, et al. Whole-exome sequencing links a variant in DHDDS to retinitis pigmentosa. *Am J Hum Genet.* 2011; 88(2): 201 – 206.
57. Xu Y, Guan L, Shen T, Zhang J, Xiao X, Jiang H, et al. Mutations of 60 known causative genes in 157 families with retinitis pigmentosa based on exome sequencing. *Hum Genet.* 2014; 133(10): 1255 – 1271.
58. Jinda W, Taylor TD, Suzuki Y, Thongnoppakhun W, Limwongse C, Lertrit P, et al. Whole exome sequencing in Thai patients with retinitis pigmentosa reveals novel mutations in six genes. *Invest Ophthalmol Vis Sci.* 2014; 55(4): 2259 – 2268.
59. Fu Q, Wang F, Wang H, Xu F, Zaneveld JE, Ren H, et al. Next-generation sequencing-based molecular diagnosis of a Chinese patient cohort with autosomal recessive retinitis pigmentosa. *Invest Ophthalmol Vis Sci.* 2013; 54(6): 4158 – 4166.
60. Liu X, Xiao J, Huang H, Guan L, Zhao K, Xu Q, et al. Application of targeted next-generation sequencing in patients with autosomal recessive inherited retinal dystrophies: improvement of genetic and clinical diagnosis. *Transl Med (Sunnyvale).* 2014; 4: 128 – 134.
61. Daiger SP, Bowne SJ, Sullivan LS, Blanton SH, Weinstock GM, Kolboldt DC, et al. Application of next-generation sequencing to identify genes and mutations causing autosomal dominant retinitis pigmentosa (adRP). *Adv Exp Med Biol.* 2014; 801: 123 – 129.
62. Zhao L, Wang F, Wang H, Li Y, Alexander S, Wang K, et al. Next-generation sequencing-based molecular diagnosis of 82 retinitis pigmentosa probands from Northern Ireland. *Hum Genet.* 2015; 134(2): 217 – 230.
63. Aparisi MJ, Aller E, Fuster-García C, García-García G, Rodrigo R, Vázquez-Manrique RP, et al. Targeted next generation sequencing for molecular diagnosis of Usher syndrome. *Orphanet J Rare Dis.* 2014; 9(1): 168 – 183.
64. Wu J, Chen L, Sin Tam O, Huang X, Pang C, Jin Z. Whole exome sequencing reveals genetic predisposition in a large family with retinitis pigmentosa. *BioMed Res Int.* 2014; Article ID 302487, 6 pages, 2014. doi:10.1155/2014/302487.
65. Jin X, Qu LH, Meng XH, Xu HW, Yin ZQ. Detecting genetic variations in hereditary retinal dystrophies with next-generation sequencing technology. *Mol Vis.* 2014; 20: 553 – 560.

Supplementary Table 1. List of 224 known genes causing retinal diseases from RETnet web site (<https://sph.uth.edu/retnet/sum-dis.htm#A-genes>)

<i>ABCA4</i>	<i>CA4</i>	<i>DFNB31</i>	<i>HTRA1</i>	<i>MVK</i>	<i>PEX1</i>	<i>ROM1</i>	<i>TLL5</i>
<i>ABCC6</i>	<i>CABP4</i>	<i>DHDDS</i>	<i>IDH3B</i>	<i>MYO7A</i>	<i>PEX2</i>	<i>RP1</i>	<i>TPA</i>
<i>ABHD12</i>	<i>CACNA1F</i>	<i>DHX38</i>	<i>IFT140</i>	<i>NDP</i>	<i>PEX7</i>	<i>RP1L1</i>	<i>TUB</i>
<i>ACBD5</i>	<i>CACNA2D4</i>	<i>DMD</i>	<i>IFT27</i>	<i>NEK2</i>	<i>PGK1</i>	<i>RP2</i>	<i>TULP1</i>
<i>ADAM9</i>	<i>CAPN5</i>	<i>DTHD1</i>	<i>IMPDH1</i>	<i>NMNAT1</i>	<i>PHYH</i>	<i>RP9</i>	<i>UNC119</i>
<i>ADAMTS18</i>	<i>CC2D2A</i>	<i>EFEMP1</i>	<i>IMPG1</i>	<i>NPHP1</i>	<i>PITPNM3</i>	<i>RPE65</i>	<i>USH1C</i>
<i>AHI1</i>	<i>CDH23</i>	<i>ELOVL4</i>	<i>IMPG2</i>	<i>NPHP3</i>	<i>PLA2G5</i>	<i>RPGR</i>	<i>USH1G</i>
<i>AIPL1</i>	<i>CDH3</i>	<i>EMC1</i>	<i>INPP5E</i>	<i>NPHP4</i>	<i>PRCD</i>	<i>RPGRIP1</i>	<i>USH2A</i>
<i>ALMS1</i>	<i>CDHR1</i>	<i>ERCC6</i>	<i>INVS</i>	<i>NR2E3</i>	<i>PROM1</i>	<i>RPGRIP1L</i>	<i>VCAN</i>
<i>ARL2BP</i>	<i>CEP164</i>	<i>EYS</i>	<i>IQCB1</i>	<i>NR2F1</i>	<i>PRPF3</i>	<i>RS1</i>	<i>WDPCP</i>
<i>ARL6</i>	<i>CEP290</i>	<i>FAM161A</i>	<i>ITM2B</i>	<i>NRL</i>	<i>PRPF31</i>	<i>SAG</i>	<i>WDR19</i>
<i>ARMS2</i>	<i>CERKL</i>	<i>FBLN5</i>	<i>JAG1</i>	<i>NYX</i>	<i>PRPF4</i>	<i>SDCCAG8</i>	<i>WFS1</i>
<i>ATXN7</i>	<i>CFB</i>	<i>FLVCR1</i>	<i>KCNJ13</i>	<i>OAT</i>	<i>PRPF6</i>	<i>SEMA4A</i>	<i>ZNF423</i>
<i>BBIP1</i>	<i>CFH</i>	<i>FSCN2</i>	<i>KCNV2</i>	<i>OFD1</i>	<i>PRPF8</i>	<i>SLC24A1</i>	<i>ZNF513</i>
<i>BBS1</i>	<i>CHM</i>	<i>FZD4</i>	<i>KIAA1549</i>	<i>OPA1</i>	<i>PRPH2</i>	<i>SLC7A14</i>	
<i>BBS10</i>	<i>CIB2</i>	<i>GDF6</i>	<i>KIF11</i>	<i>OPA3</i>	<i>RAB28</i>	<i>SNRNP200</i>	
<i>BBS12</i>	<i>CLN3</i>	<i>GNAT1</i>	<i>KIZ</i>	<i>OPN1LW</i>	<i>RAX2</i>	<i>SPATA7</i>	
<i>BBS2</i>	<i>CLRN1</i>	<i>GNAT2</i>	<i>KLHL7</i>	<i>OPN1MW</i>	<i>RB1</i>	<i>TEAD1</i>	
<i>BBS4</i>	<i>CNGA1</i>	<i>GNPTG</i>	<i>LCA5</i>	<i>OPN1SW</i>	<i>RBP3</i>	<i>TIMM8A</i>	
<i>BBS5</i>	<i>CNGA3</i>	<i>GPR125</i>	<i>LRAT</i>	<i>OTX2</i>	<i>RBP4</i>	<i>TIMP3</i>	
<i>BBS7</i>	<i>CNGB1</i>	<i>GPR179</i>	<i>LRIT3</i>	<i>PANK2</i>	<i>RD3</i>	<i>TLR3</i>	
<i>BBS9</i>	<i>CNGB3</i>	<i>GPR98</i>	<i>LRP5</i>	<i>PAX2</i>	<i>RDH11</i>	<i>TLR4</i>	
<i>BEST1</i>	<i>CNNM4</i>	<i>GRK1</i>	<i>LZTFL1</i>	<i>PCDH15</i>	<i>RDH12</i>	<i>TMEM126A</i>	
<i>C12orf65</i>	<i>COL11A1</i>	<i>GRM6</i>	<i>MAK</i>	<i>PCYT1A</i>	<i>RDH5</i>	<i>TMEM237</i>	
<i>C1QTNF5</i>	<i>COL2A1</i>	<i>GUCA1A</i>	<i>MERTK</i>	<i>PDE6A</i>	<i>RGR</i>	<i>TOPORS</i>	
<i>C2</i>	<i>COL9A1</i>	<i>GUCA1B</i>	<i>MFN2</i>	<i>PDE6B</i>	<i>RGS9</i>	<i>TREX1</i>	
<i>C21orf2</i>	<i>CRB1</i>	<i>GUCY2D</i>	<i>MFRP</i>	<i>PDE6C</i>	<i>RGS9BP</i>	<i>TRIM32</i>	
<i>C2orf71</i>	<i>CRX</i>	<i>HARS</i>	<i>MKKS</i>	<i>PDE6G</i>	<i>RHO</i>	<i>TRPM1</i>	
<i>C3</i>	<i>CSPP1</i>	<i>HK1</i>	<i>MKS1</i>	<i>PDE6H</i>	<i>RIMS1</i>	<i>TSPAN12</i>	
<i>C8orf37</i>	<i>CYP4V2</i>	<i>HMCN1</i>	<i>MTTP</i>	<i>PDZD7</i>	<i>RLBP1</i>	<i>TTC8</i>	

Supplementary Table 2. Additional genes causing retinal diseases which have been added to the list of known retinal diseases genes from RetNet (Ref: <http://www.ncbi.nlm.nih.gov/gene>)

No.	Gene	Chromosome location	OMIM#	Phenotype
1	<i>BCSL1</i>	2q35	603647	Björnstad syndrome, GRACILE syndrome, Leigh syndrome, Mitochondrial complex III deficiency, nuclear type 1
2	<i>COX10</i>	17p12	602125	Leigh syndrome due to mitochondrial COX4 deficiency, Mitochondrial complex IV deficiency
3	<i>COX15</i>	10q24.2	603646	Cardioencephalomyopathy, fatal infantile, due to cytochrome c oxidase deficiency 2, Leigh syndrome due to cytochrome c oxidase deficiency
4	<i>EDNI</i>	6p24.1	131240	Auriculocondylar syndrome 3, Question mark ears, isolated, {High density lipoprotein cholesterol level QTL 7}
5	<i>FAM46A</i>	6q14	611357	---
6	<i>FOXRRED1</i>	11q24.2	613622	Leigh syndrome due to mitochondrial complex I deficiency, Mitochondrial complex I deficiency
7	<i>MDH1</i>	2p15	154200	---
8	<i>NDUFA10</i>	2q37.3	603835	?Leigh syndrome
9	<i>NDUFA12</i>	12q22	614530	Leigh syndrome due to mitochondrial complex I deficiency
10	<i>NDUFA2</i>	5q31.3	602137	Leigh syndrome due to mitochondrial complex I deficiency
11	<i>NDUFA9</i>	12p13.32	603834	Leigh syndrome due to mitochondrial complex I deficiency
12	<i>NDUFAP2</i>	5q12.1	609653	Leigh syndrome, Mitochondrial complex I deficiency
13	<i>NDUFAP6</i>	8q22.1	612392	Leigh syndrome due to mitochondrial complex I deficiency
14	<i>NDUFS3</i>	11p11.2	603846	Leigh syndrome due to mitochondrial complex I deficiency, Mitochondrial complex I deficiency
15	<i>NDUFS4</i>	5q11.2	602694	Leigh syndrome, Mitochondrial complex I deficiency
16	<i>NDUFS7</i>	19p13.3	601825	Leigh syndrome
17	<i>NDUFS8</i>	11q13.2	602141	Leigh syndrome due to mitochondrial complex I deficiency
18	<i>PMM2</i>	16p13.2	601785	Congenital disorder of glycosylation, type Ia
19	<i>PRKCG</i>	19q13.42	176980	Spinocerebellar ataxia 14
20	<i>SDHA</i>	5p15.33	600857	Leigh syndrome, Mitochondrial respiratory chain complex II deficiency, Paragangliomas 5, Cardiomyopathy, dilated, 1GG
21	<i>SURF1</i>	9q34.2	185620	Leigh syndrome, due to COX deficiency



Supplementary Figure 1. Pedigrees of 13 Iranian families with non-syndromic arRP. Filled square/circle: Male/female affected member; Blank square/circle: Male/female normal member; Arrow: Affected proband. Slash pointed out died and a double horizontal line indicated consanguinity.