

Case Report

Interventional Therapy for Infective Pseudoaneurysm is a Hope for a Patient in an Undeveloped Area

Ji-Chun Zhao MD PHD¹

Abstract

Patient, a 59-year-old male coming from an undeveloped area of Sichuan Province, China, was admitted because of chest pain for one month. Compute tomography angiography showed descending aorta pseudoaneurysm at the level of the 6th thoracic vertebra (T6). History of bone tuberculosis and tuberculosis DNA test had confirmed diagnosis of tuberculosis. Interventional surgery was performed 3 days after admission. A covered stent (Medtronic TF 3030C200EE) was deployed slowly and accurately. Digital subtraction angiography showed that the pseudoaneurysm was isolated successfully and completely. The chest pain syndrome was relieved considerably. On the day after surgery, the patient was discharged. Fourteen months later, a recent CT revealed that the stent was in the right place and fluent and no infective clue was detected. The patient did not have any discomfort. Interventional therapy for infective pseudoaneurysm still has long promising prognosis. At the same time, anti-infection therapy is also essential.

Keyword: Infective pseudoaneurysm, interventional therapy, undeveloped area

Cite this article as: Zhao JC. Interventional Therapy for Infective Pseudoaneurysm is a Hope for a Patient in an Undeveloped Area. *Arch Iran Med.* 2015; **18(6):** 389 – 390.

Introduction

Infective pseudoaneurysm is not rare, and tuberculosis, fungi and bacteria are the main causes.¹⁻³ Worldwide, it is controversial to treat it via intervention because doctors tend to worry about stent infection, which may affect fluency and even lead to occlusion, resulting in poor prognosis. However, we here report a case about interventional therapy of infective pseudoaneurysm.

Case Report

The patient, a 59-year-old male from an undeveloped area of Sichuan province, China, was admitted with diagnosis of descending aorta pseudoaneurysm. The patient had documented tuberculosis (TB), specifically spinal tuberculosis, for about one year. He was receiving anti-TB therapy regularly in the recent 2 years. The result of compute tomography angiography (CTA) revealed that pseudoaneurysm was located on the descending aorta, at the level of T6, with a size of 2.9 × 2.0 × 2.9 cm. Hematoma around it was clear (Figure 1). After 3 days of preparation to confirm that TB was not in window time, interventional surgery was performed under local anesthesia and full hemodynamic monitoring. The result of intraoperative digital subtraction angiography (DSA) confirmed preoperative CTA. A covered stent (Medtronic TF 3030C200EE) was deployed slowly and accurately, (Figure 2) followed by angiography. DSA showed that the pseudoaneurysm was isolated successfully and completely. On the day after surgery, chest pain was relieved considerably and the patient was discharged. Fourteen months later, a recent CT showed that the stent was in the right place without thrombosis or occlusion. Furthermore, no infective clue was detected. The patient did not

complain of chest pain or any discomfort anymore. The patient was still underwent anti-TB therapy.

Discussion

Treatment of pseudoaneurysm mainly involves conventional surgery and endovascular intervention. However, conventional surgery is gradually replaced by endovascular treatment, because of fewer complications, less trauma and shorter stay in hospital. This may entail a good economic effect for undeveloped areas, like western part of China. Due to poor economic condition and shortage of health consciousness in that area, the incidence of various infections, especially tuberculosis, is considerably higher than other areas. Naturally, the incidence of infective pseudoaneurysm is also higher. Supposed that interventional therapy could be adopted in most cases in west, patients could pay less for their medical costs, which ensures that more patients could receive in-time and effective therapy. Simultaneously, recent reports and this case show that interventional therapy for infective pseudoaneurysm is also effective and safe^{4,5} and has a promising prognosis.

Reference

1. Yadav MK, Bhatia A, Kumar S, Khandelwal N. Internal mammary artery pseudoaneurysm: A rare fatal complication of tubercular empyema. *Lung India.* 2013; **30:** 341 – 343.
2. Seo DJ, Kim JB. Tuberculous aortitis complicated with pseudoaneurysm formation in the descending thoracic aorta: a case report. *Korean J Thorac Cardiovasc Surg.* 2012; **45:** 408 – 411.
3. Wei W, Hui C, Sheng-Yu W, Xin D. Uncommon Cause of Left Ventricular Pseudoaneurysm: Case Report and Review of Literature. *Thorac Cardiovasc Surg.* 2013; **62:** 375 – 377.
4. Nakayama Y, Yamaki F, Matsumura Y. Endovascular aneurysm repair of saccular descending thoracic pseudoaneurysm possibly associated with tuberculosis. *Gen Thorac Cardiovasc Surg.* 2012; **60:** 501 – 503.
5. Villegas MO, Mereles AP, Tamashiro GA, Dini AE, Mollón AP, De Cándido LV et al. Endovascular treatment of an aortoiliac tuberculous pseudoaneurysm. *Cardiovasc Intervent Radiol.* 2013; **36:** 540 – 544.

Author's affiliation: ¹Department of Vascular Surgery, West China Hospital, Sichuan University, 37 Guo Xue Road, Chengdu 610041, Sichuan Province, China.
Corresponding author and reprints: Jichun Zhao MD PhD, Tel: +86 028 85422870. Fax: +86028 85422870, E-mail: hxzhao9@163.com
 Accepted for publication: 20 May 2015

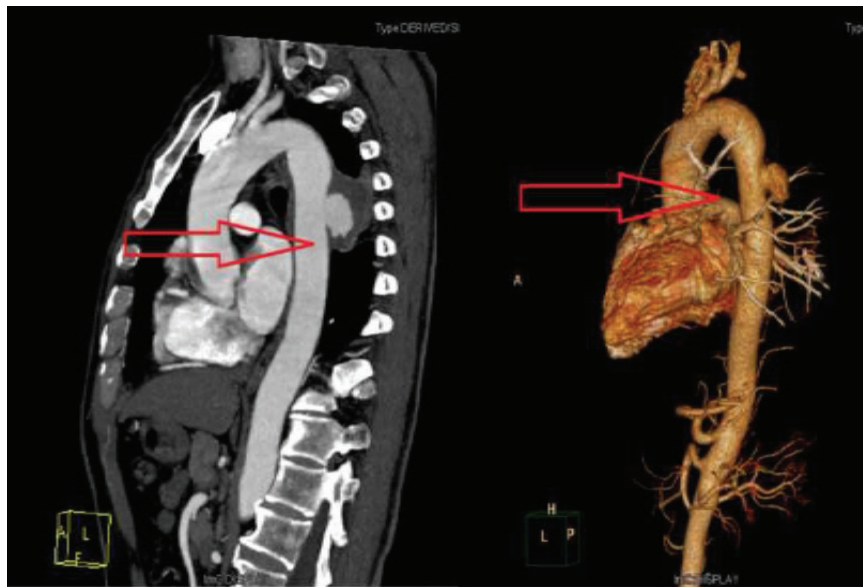


Figure 1. Aorta pseudoaneurysm and hematoma appear clearly on compute tomography angiography (CTA). Red arrow in this figure indicates the pseudoaneurysm and hematoma.

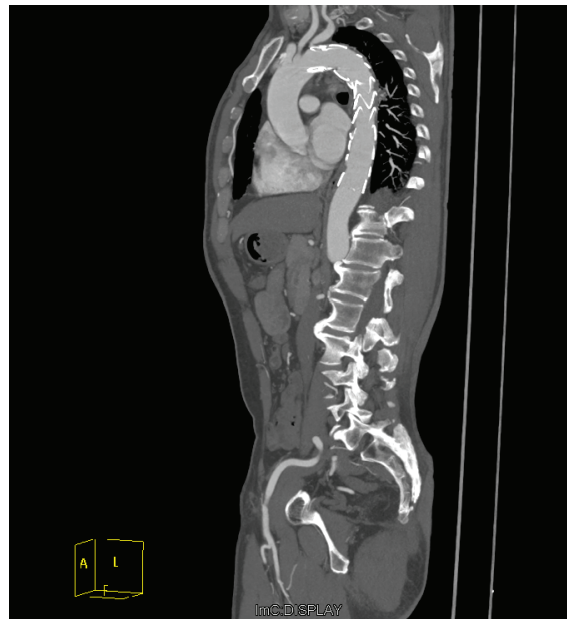

Figure 2. Covered stent (Medtronic TF 3030C200EE) isolates pseudoaneurysm completely. No endoleak occurred.