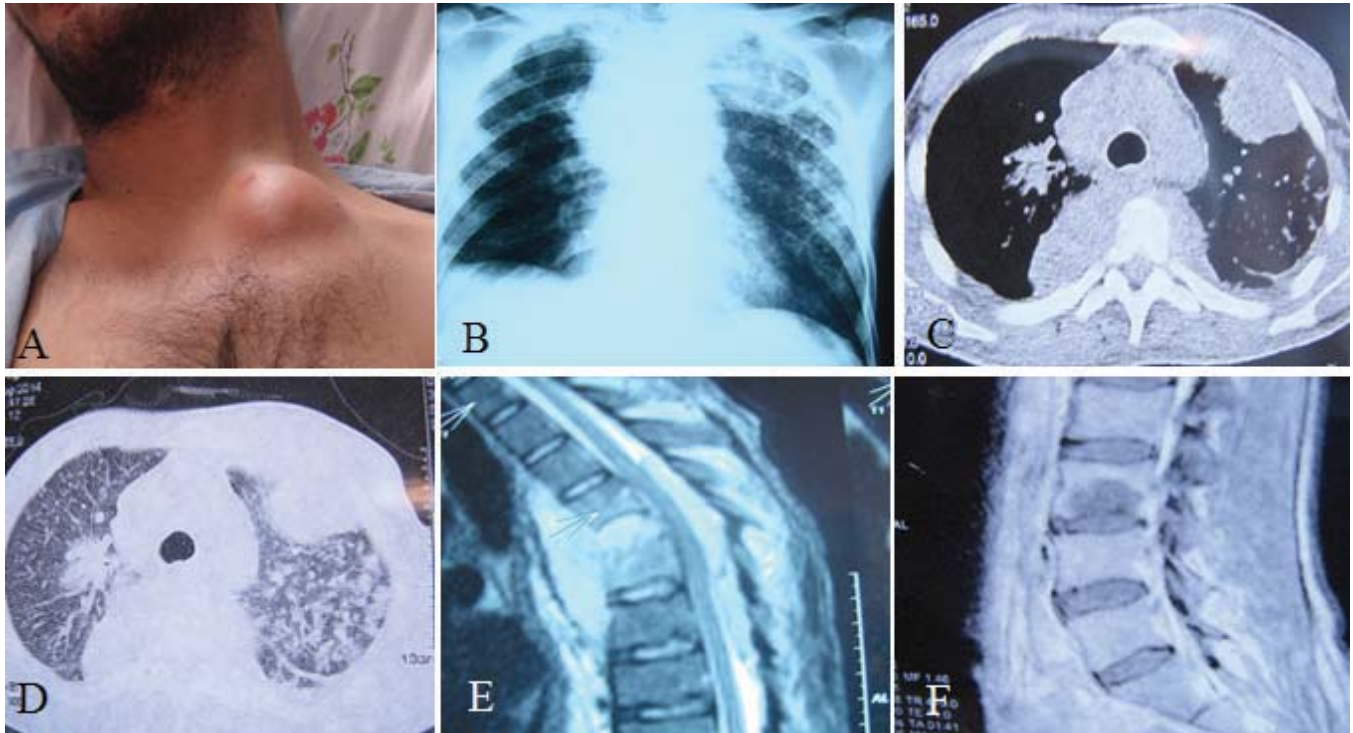


## Photoclinic



**Figure 1.** A) Chest wall abscess; B) Poster anterior view CXR; C) Chest CT-scan (mediastinal view); D) Chest CT-scan (parenchymal view); E) T2-weighted MRI of thoracic spine; F) T1-weighted MRI of lumbar spine.

Cite this article as: Yousefi F, Nashibi R, Behmanesh F, Feizi J. Photoclinic. *Arch Iran Med.* 2015; **18**(5): 329 – 330.

A 29-year-old Iranian man (Khuzestan Province) was admitted to the emergency clinic with fever, urinary retention, and bilateral lower-extremity weakness, especially at the right side. He had been prisoner for 17 months before admission. The patient had poor appetite and suffered from approximately 30 kilogram weight loss during 3 months prior to admission. Physical examination showed a mass lesion about  $8 \times 4$  centimeters at the base of the left supraclavicular region (Figure 1 A). In neurologic as-

Farid Yousefi MD<sup>1,2</sup>, Roohangiz Nashibi MD<sup>1,2</sup>, Farzaneh Behmanesh MD<sup>2</sup>, Jalil Feizi MD<sup>2</sup>

**Author's affiliations:** <sup>1</sup>Health Research Institute, Infectious and Tropical Diseases Research Center, Ahvaz Jundishapur University of Medical Sciences, Ahvaz, Iran, <sup>2</sup>Department of Infectious and Tropical Diseases, Razi Teaching Hospital, Faculty of Medicine, Ahvaz Jundishapur University of Medical Sciences, Ahvaz, Iran.

**Corresponding author and reprints:** Roohangiz Nashibi MD, Health Research Institute, Infectious and Tropical Diseases Research Center, Ahvaz Jundishapur University of Medical Sciences, Ahvaz, Iran, Department of Infectious and Tropical Diseases, Razi Teaching Hospital, Faculty of Medicine, Ahvaz Jundishapur University of Medical Sciences, Ahvaz, Iran. Tel: +98-61-3333-5935, Fax: +98-61-3333-6513. E-mail: Roohangizenashibi@yahoo.com.

Accepted for publication: 24 March 2015

essment, muscular power was decreased (2/5), with no sensory involvement. Laboratory results were consistent with moderate anemia (hemoglobin = 7.7) and high erythrocyte sedimentation rate (ESR = 108 mm/hour). Tuberculin test and three samples of sputum smear for acid fast staining were negative. Chest X-ray showed a mass lesion in the upper lobe of the left lung (Figure 1B). Chest computed tomography scan also showed a mass lesion in the same region of left lung, along with bilateral alveolar infiltrations with tree-in-bud pattern (Figure 1 C and D). Thoracic and lumbar vertebral destruction as well as thoracic paraspinous abscess with pressure effect on cord or nerve endings have been shown on his lumbosacral magnetic resonance imaging (MRI) (Figure 1, E and F).

**What is your diagnosis?  
See the next page for diagnosis**

Despite the dramatic decline in the incidence of tuberculosis during the last decades, the disease remains a significant public health problem especially in developing countries. Chest wall tuberculosis is a very rare manifestation of this disease.<sup>1</sup> Clinically, it can present as a pyogenic abscess, occurring in both immunocompetent and immunocompromised patients. Rarely, tuberculous paraspinal abscess is seen as a late complication of Pott's disease.<sup>2</sup> Such abscesses in combination are rare and very uncommon worldwide.

Symptoms began eight weeks before admission in our patient; however, a definite diagnosis was not made. On the 4<sup>th</sup> day of admission, the chest wall lesion was aspirated and about 20 mL straw-colored fluid was obtained and sent for laboratory analysis. On the 8<sup>th</sup> day of admission, the patient underwent laminectomy (T3 – T7), and decompression was done for him. On the 12<sup>th</sup> day of admission, reverse-transcriptase polymerase chain reaction

testing on the chest wall and paraspinal abscess materials were positive for *Mycobacterium tuberculosis* (TB), confirming the diagnosis of TB. Anti-TB drugs were initiated, and his clinical symptoms improved.

The diagnosis of extrapulmonary TB has been a worldwide challenge. Clinicians should be familiar with the epidemiologic background as well as the clinical and laboratory features of extrapulmonary tuberculosis, is facilitated earlier diagnosis.

## References

1. Zidane A, Bakzaza O, Afandi O, Baiz Y, Chafik A. Chest wall tuberculosis: Report of 3 cases. *Revue De Pneumologie Clinique*. 2015. doi: 10.1016/j.pneumo.2014.12.006. [Epub ahead of print]
2. Alg VS, Demetriades AK, Naik S, Gunasekera L. Isolated subacute tuberculous spinal epidural abscess of the cervical spine: a brief report of a special case. *Acta Neurochirurgica*. 2009; **151**(6): 695 – 696.