

Case Report

Uterine Primitive Neuroectodermal Tumor

Soheila Aminimoghaddam MD¹, Soroush Seifirad MD², Golbahar Abbasi Dezfouli MD¹, Neda Abbasi MD¹, Ali Zare Mehrjardi MD³, Seyyed Mohsen Razavi MD⁴, Fatemeh Mahmoudzadeh⁵

Abstract

Primitive neuroectodermal tumors are fairly rare in uterus. A case of uterine body primitive neuroectodermal tumor in a 32-year-old Iranian woman is presented. The patient was admitted with abdominal pain and fever and underwent emergency exploratory surgery with total abdominal hysterectomy, bilateral salpingo-oophorectomy, and pelvic lymph node dissection. Posterior wall of the uterus was necrotic and ruptured and a huge tumor disrupted the uterine body. The tumor was strongly positive for CD99, NSE, and chromogranin; No reaction was seen for CD10, CD45 and myogenin. To the best of our knowledge, this is the first report of an uterine body primitive neuroectodermal tumor and the second report of uterine primitive neuroectodermal tumor from Iran.

Keywords: Primitive neuroectodermal tumor, uterus

Cite this article as: Aminimoghaddam S, Seifirad S, Abbasi Dezfouli G, Abbasi N, Zare Mehrjardi A, Razavi SM, Mahmoudzadeh F. Uterine Primitive Neuroectodermal Tumor. *Arch Iran Med.* 2015; **18**(4): 260 – 262.

Introduction

In 1973, Hart and Earl described a group of small round cell tumors with variable degrees of ependymal, glial, and neural differentiation which are considered to originate from fetal neuroectodermal cells.¹ Ewing's sarcoma and primitive neuroectodermal tumor (PNET) stand for a single group of bone and soft-tissue tumors in which PNET with evidence of neural differentiation lies at one end of the spectrum and undifferentiated Ewing's sarcoma lies at the other.^{2,3} Both have similar phenotype and share an identical chromosomal translocation. PNET rarely involves the female genital tract⁴; however a few cases have been reported to involve the ovary, uterine corpus, uterine cervix, and vulva.^{3,5-7} Here, we report a case of PNET in the uterine body.

Case Report

In September 2011, a 32-year old Iranian woman, gravid 3, para 2, live 1, death 1, ectopic pregnancy 1 (G3P2L1D1EP1) presented with abdominal pain and fever since 2 days before admission to our emergency room. She suffered from abnormal vaginal bleeding since 4 years before admission; a fractional dilation and curettage (D and C) which was performed two weeks before admission was reported as PNET involving endometrium.

Family history was negative for malignancy; there was a history of cesarean section (C/S), laparoscopy (due to ectopic pregnancy) and D and C. Drug history was negative. The Papanicolaou smear

Authors' affiliations: ¹Department of Gynecology Oncology, Firoozgar Hospital, Iran University of Medical Sciences, Tehran, Iran. ²Endocrinology and Metabolism Research Center (EMRC), Endocrinology and Metabolism Research Institute (EMRI), Tehran University of Medical Sciences, Shariati Hospital, Tehran, Iran. ³Department of Pathology, Firoozgar Hospital, Iran University of Medical Sciences, Tehran, Iran. ⁴Department of Gynecology Oncology, Firoozgar Hospital, Iran University of Medical Sciences, Tehran, Iran. ⁵Medical Student, Mazandaran University of Medical Sciences, Sari, Iran.

Corresponding author and reprints: Soroush Seifirad MD, Endocrinology and Metabolism Research Center (EMRC), Tehran University of Medical Sciences, Shariati Hospital, Tehran, Iran. Cell phone: +98-935-579-9979, Fax: +98-218-822-0052, E-mail: sseifirad@gmail.com
Accepted for publication: 7 January 2015

was negative for malignancy. Ultrasound examination reported an enlarged uterus (12.5 × 11 × 8 cm) and solid mass 9 × 6.5 cm in the anterior and lateral walls of the uterus. Two 54 × 37 mm and 29 × 25 mm cysts with septa were reported in the left and right ovaries, respectively.

Magnetic resonance imaging (MRI) showed a bulky intramural, partially enhancing mass on the right side of fundus of uterus. (Figure 1). An enhancing bony lesion in the right aspect of sacrum was also reported which suggested probable bony metastasis; however, bone scan reported no evidence of bony metastasis and exploratory laparotomy did not reveal any evidence for such a diagnosis. Tumor markers including CA 125, AFP, and CEA were in the normal range. The patient subsequently underwent emergency exploratory surgery with total abdominal hysterectomy, bilateral salpingo-oophorectomy, and pelvic lymph node dissection. The posterior wall of the uterus was necrotic and ruptured and a huge tumor disrupted the uterine body.

Microscopically, there was a small round cell tumor growing as solid nests throughout the myometrium and replacing the endometrium with large areas of necrosis. There was no cellular pleomorphism or evidence of rosette formation. Immunohistochemically, the tumor cells were positive for CD99, NSE and chromogranin; no reaction was seen for CD10, CD45, and myogenin. Thus, small round cell tumors like endometrial stromal sarcoma and rhabdomyosarcoma were ruled out^{8,9} (Figures 2–4).

The patient underwent chemotherapy with Holoxan (1.5 gr/m²) and Mesna (400 mg TDS) Cisplatin (80 mg/m²) for 4 days followed by radiotherapy. Two other chemotherapy cycles with the same diet were performed after radiotherapy. In February 2013, the patient was re-admitted due to ascites and tumor recurrence was confirmed by laparoscopy. The patient was treated with Paclitaxol (180 mg/m²) and Carboplatin AUC7 (600 mg) for 6 cycles. In November 2013, she came back with ascites and tumor recurrence and peritoneal seeding, diagnosed by ascites tap; because of poor prognosis, the patient was given palliative treatment. She is alive now, but her prognosis is quite poor.

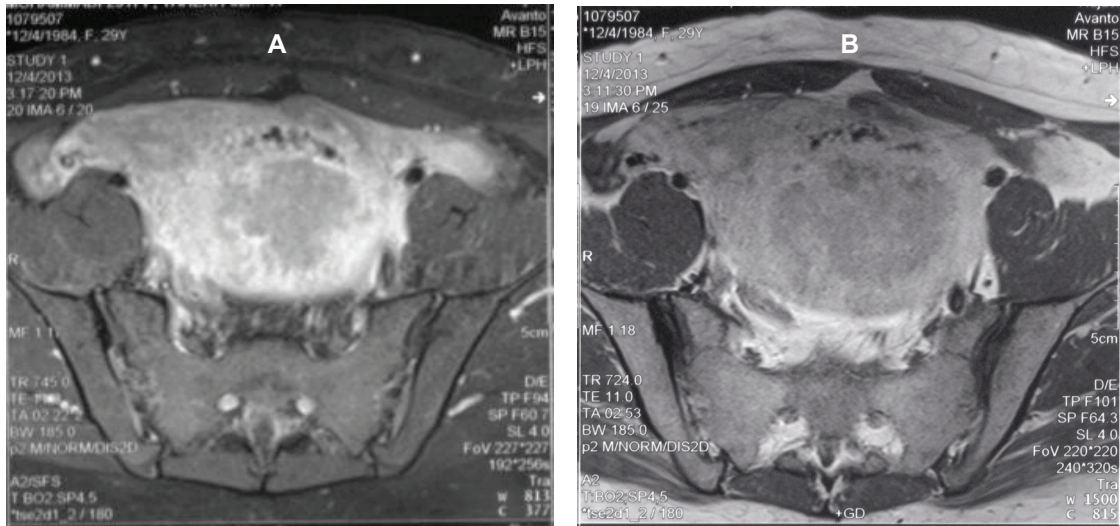


Figure 1. A) Magnetic resonance imaging (MRI) showed a bulky intramural, **B)** partially enhancing mass on the right side of fundus of uterus.

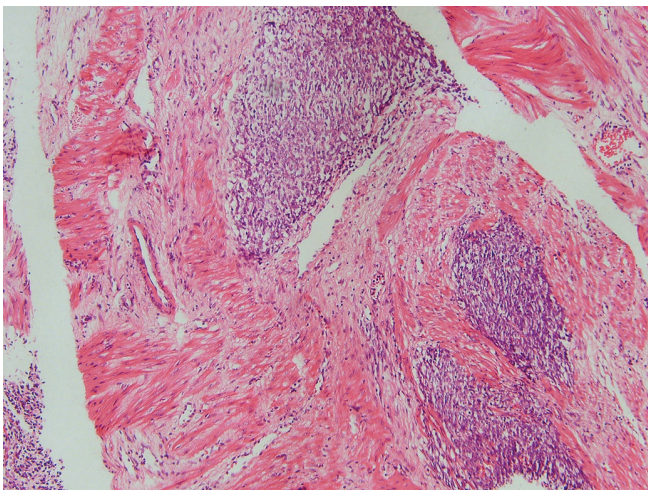


Figure 2. Several nests of tumor invading myometrium (Hematoxylin and Eosin, $\times 100$)

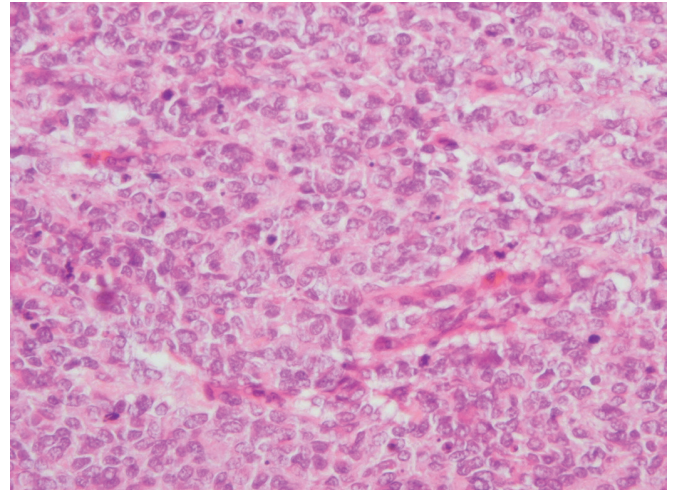


Figure 3. Tumoral cells are small to medium size, with plump nuclei, fine chromatin and small amounts of cytoplasm. Note frequent mitotic figures (Hematoxylin and Eosin, $\times 400$)

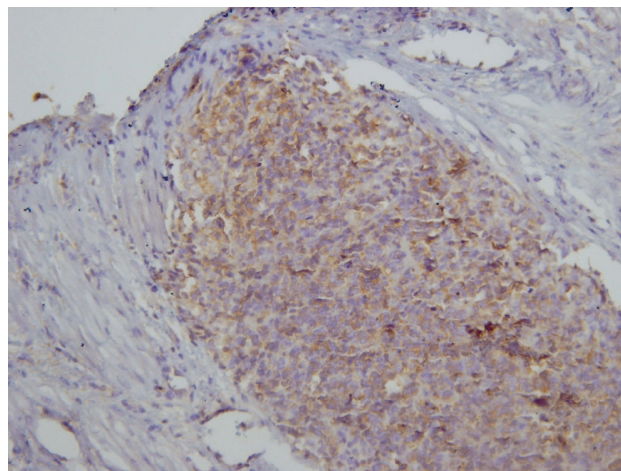


Figure 4. Immunohistochemical (IHC) staining for CD99. Tumor cells are diffusely positive ($\times 200$)

Discussion

In 1918, South described this tumor but the term PNET was coined by Hart and Earle in 1973 to show a number of small round cell tumors which may be derived from neuroectodermal cell showing different signs of neural, glial and ependymal differentiation.¹ PNET of uterus has been rarely reported. Hendrickson and Scheithauer first reported this tumor in 1986.¹⁰ It has been shown that PNET has high malignant feature which progresses rapidly and metastasizes widely.^{1,3,11} The differential diagnosis of PNET in the uterus usually includes other uterine tumors including small cell carcinoma, sarcoma, and lymphoma.^{4,11} Immunohistochemical staining and histological findings might help to distinguish this rare tumor from other more common malignancies.^{3,8} PNET has a mesodermal origin and is associated with tumors of known Mullerian origin.¹²

Uterine PNET has been typically reported in 2 groups: adolescent girls and postmenopausal women; however our patient was a 32-year-old woman. In line with our case presentation, the most common reported findings in PNET are abnormal vaginal bleeding and uterine enlargement.^{4,11}

PNET diagnosis is difficult and several differential diagnoses should be considered. Uterine PNET mostly shows various types of neuroectodermal elements like fibrillary background, ganglion cells astrocyte like cells, rosette like cells, rosetts, ependymal and medulloepithelial differentiation.¹³ Unfortunately, many PNET cases have been described at advanced stages.^{6,10,11,13}

Immunohistochemical staining can help with the diagnosis of PNET and determining its prognosis. CD99 is the most practical immunohistochemical marker for diagnosis of PNET.¹⁴ CD99 is a monoclonal antibody of the surface protein MIC2 whose gene is located on pseudoautosomal region of X and Y chromosomes.^{8,9} CD99 prognostic properties vary in different tumors. For example, CD99 presentation predicts good prognosis in diffuse large B-cell lymphoma (DLBCL) with the germinal center B-cell subtype and non-small cell lung cancer (NSCLC), while in DLBCL with non-GCB, CD99 is a marker of poor prognosis.^{15,16}

Unfortunately, to our knowledge no study has evaluated CD99 in uterine PNET; however, it has been shown that atypical Ewing Sarcoma (including CD99, FLI1, HNK1, and CAV1 negative tumors) is associated with less favorable clinical outcome.¹⁷ Our patient's tumor was strongly positive for CD99 (Figure 2). As a limitation of our case presentation, t(11/22) translocation as a precise marker for PNET was not evaluated in our case.

Without sufficient treatment, more than 90% of patients with Ewing's sarcoma die due to secondary hematogeneous metastases. However, with satisfactory cytotoxic treatment, the five-year survival rate can increase up to 60% in localized disease.¹⁸ Rather than cytotoxic treatment, in the case of PNET, surgery should be considered as the first step. Total hysterectomy with bilateral salpingo-oophorectomy with or without chemotherapy and/or radiotherapy is the usual course of treatment provided.¹⁹ To the best of our knowledge, this is the first report of uterine body PNET from Iran. Only one case of cervical PNET from our country has been reported before.¹⁴

Consent

Written informed consent was obtained from the patient.

Conflict of interests

We declare that we have no conflict of interest.

References

- Hart MN, Earle KM. Primitive neuroectodermal tumors of the brain in children. *Cancer*. 1973; **32**: 890 – 897.
- Bhardwaj M, Batrani M, Chawla I, Malik R. Uterine primitive neuroectodermal tumor with adenocarcinoma: a case report. *J Med Case Rep*. 2010; **4**: 195.
- Park JY, Lee S, Kang HJ, Kim HS, Park SY. Primary ewing's sarcoma-primitive neuroectodermal tumor of the uterus: a case report and literature review. *Gynecol Oncol* 2007; **106**: 427 – 432.
- Kleinman GM, Young RH, Scully RE. Primary neuroectodermal tumors of the ovary. A report of 25 cases. *Am J Surg Pathol*. 1993; **17**: 764 – 778.
- Arora N, Kalra A, Kausar H, Ghosh TK, Majumdar A. Primitive neuroectodermal tumour of uterine cervix - a diagnostic and therapeutic dilemma. *J Obstet Gynaecol*. 2012; **32**: 711 – 713.
- Akbayir O, Gungorduk K, Rafioglu G, Gulkilik A, Yavuz E, Tekirdag AI, et al. Primary primitive neuroectodermal tumor of the uterus: A case report. *Arch Gynecol Obstet*. 2008; **277**: 345 – 348.
- Shah JP, Jelsema J, Bryant CS, Ali-Fehmi R, Malone JM Jr. Carboplatin and paclitaxel adjuvant chemotherapy in primitive neuroectodermal tumor of the uterine corpus. *Am J Obstet Gynecol*. 2009; **200**: e6 – e9.
- Fellinger EJ, Garin-Chesa P, Triche TJ, Huvos AG, Rettig WJ. Immunohistochemical analysis of ewing's sarcoma cell surface antigen p30/32mic2. *Am J Pathol*. 1991; **139**: 317 – 325.
- Scotlandi K, Baldini N, Cerisano V, Manara MC, Benini S, Serra M, et al. Cd99 engagement: an effective therapeutic strategy for ewing tumors. *Cancer Res*. 2000; **60**: 5134 – 5142.
- Hendrickson MR, Scheithauer BW. Primitive neuroectodermal tumor of the endometrium: report of two cases, one with electron microscopic observations. *Int J Gynecol Pathol*. 1986; **5**: 249 – 259.
- Euscher ED, Deavers MT, Lopez-Terrada D, Lazar AJ, Silva EG, Malpica A. Uterine tumors with neuroectodermal differentiation: a series of 17 cases and review of the literature. *Am J Surg Pathol*. 2008; **32**: 219 – 228.
- Ren YL, Tang XY, Li T. Ewing sarcoma-primitive neuroectodermal tumor of the uterus: a clinicopathologic, immunohistochemical and ultrastructural study of one case. *Arch Gynecol Obstet*. 2011; **283**: 1139 – 1143.
- Daya D, Lukka H, Clement PB. Primitive neuroectodermal tumors of the uterus: a report of four cases. *Hum Pathol*. 1992; **23**: 1120 – 1129.
- Farzaneh F, Rezvani H, Boroujeni PT, Rahimi F. Primitive neuroectodermal tumor of the cervix: a case report. *J Med Case Rep*. 2011; **5**: 489.
- Hong J, Park S, Park J, Jang SJ, Ahn HK, Sym SJ, et al. Cd99 expression and newly diagnosed diffuse large b-cell lymphoma treated with rituximab-chop immunochemotherapy. *Ann Hematol*. 2012; **91**: 1897 – 1906.
- Edlund K, Lindskog C, Saito A, Berglund A, Ponten F, Goransson-Kultima H, et al. Cd99 is a novel prognostic stromal marker in non-small cell lung cancer. *Int J Cancer*. 2012; **131**: 2264 – 2273.
- Llombart-Bosch A, Machado I, Navarro S, Bertoni F, Bacchini P, Albergini M, et al. Histological heterogeneity of ewing's sarcoma/pnet: An immunohistochemical analysis of 415 genetically confirmed cases with clinical support. *Virchows Arch*. 2009; **455**: 397 – 411.
- Antman K, Crowley J, Balcerzak SP, Kempf RA, Weiss RB, Clamon GH, et al. A southwest oncology group and cancer and leukemia group b phase ii study of doxorubicin, dacarbazine, ifosfamide, and mesna in adults with advanced osteosarcoma, ewing's sarcoma, and rhabdomyosarcoma. *Cancer*. 1998; **82**: 1288 – 1295.
- Tsai HJ, Su CF, Kok VC, Li MC. Uterine tumor with neuroectodermal differentiation of advanced stage managed successfully with multimodal strategy. *Eur J Obstet Gynecol Reprod Biol*. 2012; **162**: 235 – 236.