

Case Report

Simultaneous Occurrence of Two Squamous Cell Carcinomas Developing in a Nevus Sebaceous

Enver Turan MD¹, Berker Buyukgural MD², Ozgur Ilhan Celik MD³

Abstract

Nevus sebaceous (NS), also known as organoid nevus, is a congenital skin hamartoma involving pilosebaceous follicle, epidermis and adnexal structures, which usually occurs in the head and neck region. During the first stage, which is seen in infancy and childhood, the lesion remains static, but can subsequently grow during puberty to become more evident and verrucous or nodular. Depending on the location and extent, nevus sebaceous causes only a cosmetic problem during childhood; however, the development of benign and malignant neoplasms on the lesion is the most severe complication during adulthood. The association between nevus sebaceous and various benign and malignant cutaneous neoplasms is well documented. Basal cell carcinoma (BCC) is the most common malignant lesion, and syringocystadenoma papilliferum (SP) is the most common benign tumor associated with nevus sebaceous. Development of squamous cell carcinoma within NS is very rare. The literature contains only a few reports of simultaneous multiple malignant tumors developing on nevus sebaceous. We present a review of the literature and report the case of a 42-year-old female patient with two squamous-cell carcinomas (SCC) simultaneously within a single NS.

Keywords: Malignant cutaneous neoplasms, nevus sebaceous, organoid nevus, squamous cell carcinoma

Cite this article as: Turan E, Buyukgural B, Ilhan Celik O. Simultaneous Occurrence of Two Squamous Cell Carcinomas Developing in a Nevus Sebaceous. *Arch Iran Med.* 2015; **18**(4): 253 – 256.

Introduction

Nevus sebaceous (NS) affecting ectoderm- and mesoderm-derived structures occurs predominantly on the head, neck and hairy skin. Although it remains stable throughout childhood, it grows and obtains a verrucous appearance as a result of the development of pilosebaceous-apocrine units due to the effect of androgens during puberty.¹

The association of NS with many kinds of benign and malignant skin tumors is documented in detail by many cases and series within the literature. The global incidence of benign or malignant lesions on nevus sebaceous is approximately 15%.² The most commonly observed benign tumors are syringocystadenoma papilliferum, apocrine cystadenoma, apocrine carcinoma, adnexal carcinoma, tubuloglandular sweat gland carcinoma, leiomyoma, metastasizing adenocarcinoma, and sebaceous carcinoma, whereas the most commonly observed malignant tumors are basal cell carcinomas (BCCs), trichoblastomas, squamous cell carcinomas (SCCs), and basosquamous carcinomas.^{1,3-5} The incidence of BCC, the most common form of malignant tumor, is less than 2%.⁶ Other malignant tumors such as SCC and adnexal tumors are rarely observed.

This study presents the case of a 42-year-old female with SCC development in two areas on NS, and attention is drawn to malignant neoplasms developing on NS background by reviewing the existing literature.

Authors' affiliations: ¹Assistant Professor, Harran University Faculty of Medicine, Department of Dermatology, Sanliurfa, Turkey

²Yasam Hospital Department of Plastic Surgery, Istanbul, Turkey.

³Ministry of Health Batman Regional Government Hospital, Department of Pathology, Batman, Turkey.

Corresponding author and reprints: Enver Turan MD, Department of Dermatology, Harran University, Faculty of Medicine, 63200-Sanliurfa, Turkey. Tel: +9005053323929, Fax: +900488 221 30 68, E-mail: enverturan@gmail.com

Accepted for publication: 17 December 2014

Care Report

A 42-year-old female patient presented to our clinic with increasingly growing lesions with occasional bleeding, located on hairy skin, the left ear and neck. The patient indicated that verrucous areas, which did not include yellowish hair in the background, had been present since childhood and had grown after puberty. She also stated that over the previous six months, indolent and wet nodular lesions had developed on this lesion, and that these bled spontaneously or following minor trauma (Figure 1). The patient did not respond to various topical treatments and systemic antibiotic treatment. Similar lesions were not observed in close relatives of the patient who was otherwise healthy. The patient's medical history did not include previous skin cancer, immunosuppression, trauma or radiation exposure.

Dermatological examination revealed a yellowish plaque lesion with occasional verrucous appearance, located on the hairy occipital area of scalp, neck and left ear region. In addition, two ulcerated nodules (22 × 34 mm and 25 × 43 mm) were detected on the left ear tragus helix and the left occipital region, respectively (Figure 1). No pathological symptoms were detected on regional lymph node examination. Magnetic resonance imaging detected no regional metastasis in lymph nodes or surrounding tissue. No pathological symptoms were detected in laboratory analysis of the patient's samples (hemogram, biochemical, immunoglobulin levels). No metastatic symptoms were detected on abdominal ultrasonography or chest radiography.

The patient was referred to Plastic and Reconstructive Surgery; her lesions were completely excised with wide surgical margin and the defects were closed with a split-thickness skin graft. On histopathological examination of the excised material, hyperkeratosis, papillomatosis and irregular acanthosis were observed in non-ulcerated areas of the epidermis. On the dermis, a large

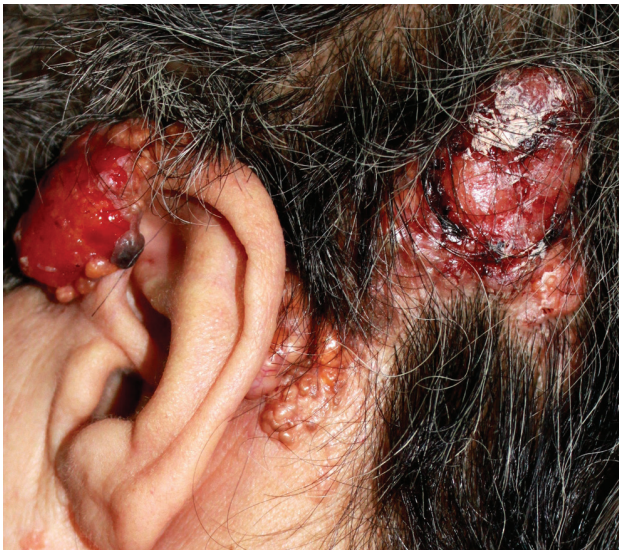

Figure 1. Ulcerous nodular lesions in two different areas in hairy skin and tragus regions, and yellowish plaque lesion in background.

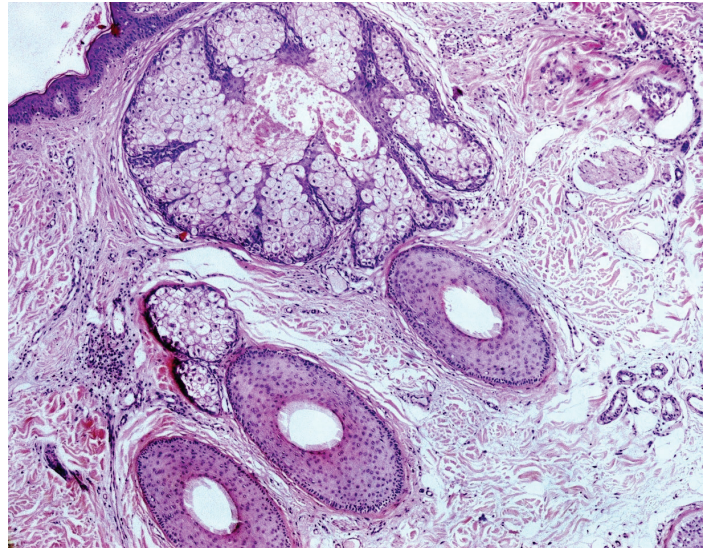


Figure 2. Hyperplasia with underlying sebaceous glands and prominent apocrine glands in dermis [hematoxylin and eosin stain (H&E); original magnification $\times 200$].

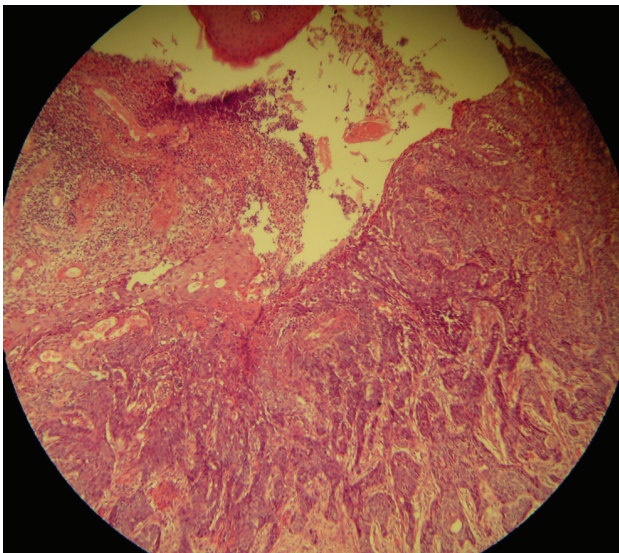


Figure 3. Histological image of squamous cell carcinoma: Neoplastic proliferation of squamous differentiated tumor cells in the epidermis (H&E; $\times 200$).

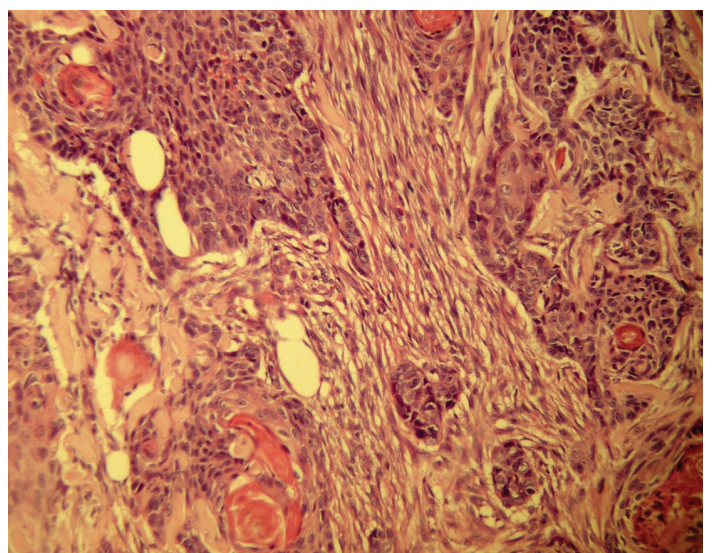


Figure 4. Proliferation of differentiated squamous cells invading deep dermis (H&E; $\times 400$).

number of irregularly distributed mature sebaceous glands, apocrine glands and occasional immature hair follicles were observed (Figure 2). On sections of ulcerated areas of the epidermis, differentiated squamous cell proliferation was observed where dyskeratotic and atypical keratinocytes were found. Moderately differentiated cells were also observed to invade the papillary and reticular dermis (Figure 3). The clinical and histopathological findings are consistent with NS settled in a large area and presence of SCC in two distinct areas on this nevus. On a control examination after one week, sutures were removed and the patient was transferred to periodic follow-up examination. No infection or surgical complication was observed. No recurrence was observed during an 18-month follow-up period.

Discussion

NS is a complex hamartomatous skin malformation affecting

0.3% of newborns.⁷ This tumor belongs to the congenital lesions group that originates from primary epithelial embryonic germ cells—also called organoid nevus. Clinically, it is a well-demarcated and verrucous papillomatous lesion of yellowish color.⁸ Histopathologically, it consists of epithelial hyperplasia, papillomatosis, ectopic apocrine glands, mature hypoplastic and superficially localized sebaceous glands.^{1,9} It is often observed on hairy skin and less commonly on the neck and body. It was first defined by Jadassohn in 1895, and a three-stage process of nevus was defined by Mehregan and Pinkus.¹⁰ Papillomatous epithelial hyperplasia is the early infantile stage, in which hair development in the lesional area is low. During the pubertal period, overdevelopment of sebaceous glands occurs and epidermal hyperplasia and apocrine glands undergo maturation. In the third stage, during the 4th to 8th decades, neoplasms of epidermal, adnexal or mesenchymal origins develop on the nevus.^{3,8,11} On the other hand, there are several case reports in literature which indicate BCC development on childhood sebaceous nevus.¹¹⁻¹³

While complaints are generally only of an esthetic nature during childhood, benign and malignant neoplasms develop in 15% of cases during adulthood.² Benign or malignant neoplasm development is the most commonly observed and potentially serious complication of NS, and was reported to have a global incidence of 14.4% in a large case series (13.6% benign; 0.8% malignant, all of which were basal cell carcinomas).²

The most commonly observed benign neoplasm on NS is syringocystadenoma papilliferum.¹⁴ Apart from this, trichoblastoma, trichilemmoma, sebaceoma, keratoacanthoma, seborrheic keratosis, syringoma, follicular poroma, nodular hydradenoma and apocrine cystadenoma may be observed.^{2,8,10,15} While BCC is the most commonly developing malignant tumor on nevus sebaceous, widely differing rates of development are reported. In recent papers, the incidence of BCCs on nevus sebaceous is lower compared to those reported in earlier papers. The rate of BCCs reported until 1985 is 6%–50%.¹⁶ However, an 18-year study by Rosen *et al.* showed that many cases were actually trichoblastoma misdiagnosed as BCC. In addition, it was reported that the incidence of BCCs on nevus sebaceous was less than 2%.¹⁷

Cases of malignant tumors other than BCCs developing on NS are very rare. Those rare malignant neoplasms comprise SCC, adnexal carcinoma, apocrine carcinoma and eccrine poroma. A study of 997 cases by Domingo *et al.* reported nine aggressive carcinomas detected on nevus sebaceous, two of which were BCC, whereas seven were adnexal carcinoma.³ In two different nevus sebaceous series consisting of 180 and 140 cases, there was one case in each series.^{8,18} In addition, verrucous hyperplasia was seen in the epidermis of one quarter of the NS cases, and it was reported that, unless it is well-documented, the condition could be mistaken for well-differentiated SCC. Wilson *et al.* concluded that some reports within the literature, of SCC developing on NS, had histopathology representing pseudoepitheliomatous hyperplasia, and might have been misdiagnosed.⁸

In the literature review, we identified 22 cases in which malignant neoplasms other than BCC developed on the nevus sebaceous. Of those, 12 were BCC and 10 were adnexal carcinoma. Three of 11 case reports were adnexal carcinoma and eight were SCC. In four cases where patients were defined with clinic and histopathological details, there was more than one malignant neoplasm on nevus sebaceous.^{1,16,19,20} A case report documented the development of many benign neoplasms (trichoadenoma, trichoblastoma, syringocystadenoma papilliferum) in addition to two malignant neoplasms (sebaceous carcinoma, BCC).²⁰ There is only one case reported in literature in which there were two different SCC lesions on nevus sebaceous.⁷

In our case, there were two different SCC developments on the same nevus sebaceous lesion; there were SCC developments on NS of hairy skin, neck and tragus, as well as on normal skin of hairy skin and tragus. Cribier *et al.* stated that in 596 cases, 79% of NS that showed tumor development were located on hairy skin.² In our case, there was SCC development on NS located on both hairy and normal skin. Our case, which was clinically diagnosed as nevus sebaceous and SCC development, was referred for plastic and reconstructive surgery; lesions were excised with wide surgical boundary and the defects were closed with a partial-thickness skin graft. The diagnosis of NS and SCC was verified via histopathological examination of excised material.

There are differing opinions about the recurrence of malignant lesions on NS. A previous study reported no recurrence in a case

of invasive SCC and BCC on NS during four years following total excision⁸ whereas there was one fatal case of recurrence 11 months after diagnosis.³ There was no recurrence in our case during 18 months of follow-up.

Longstanding opinion recommended early excision of NS seen in childhood, due to the perceived risk of malignant tumor development.^{15,21} In recent years, some authors have objected to this “prophylactic excision” because malignant tumors are rarely seen in children.²² According to these authors, malignant tumors are rare even among adults, and most BCCs are non-fatal when treated.

Nevertheless, the majority of authors defend the view that aggressive neoplasms developing on NS could cause important morbidity and, in rare cases, death, and therefore early excision is the safest course.²⁰ In the literature, since there are many studies that report malignant neoplasms developing on NS, early excision has become a popular approach—not in all, but in cases with atypical clinical properties.^{23,24}

Since literature contains limited cases of malignant neoplasms developing on NS, it is difficult to determine predicting factors or progression. Prophylactic excision of pre-puberty nevus sebaceous is a widely accepted approach. On the other hand, some studies contend that the rate of neoplasms developing on NS is low, and therefore patients could instead be followed and offered early excision in cases displaying atypical clinical properties.² Although early treatment is still debated, once surgical removal of a tumor is decided, this can be achieved via simple excision or Mohs micrographic surgery method.²⁵ In wider lesions, the excision area can be closed with a partial-thickness graft.²⁶

Declaration of Interest

The authors report no conflict of interest.

References

1. Serpas de Lopez RM, Hernandez-Perez E. Jadassohn's sebaceous nevus. *J Dermatol Surg Oncol.* 1985; **11**: 68 – 72.
2. Cribier B, Scrivener Y, Grosshans E. Tumors arising in nevus sebaceous: a study of 596 cases. *J Am Acad Dermatol.* 2000; **42**: 263 – 268.
3. Domingo J, Helwig EB. Malignant neoplasms associated with nevus sebaceous of Jadassohn. *J Am Acad Dermatol.* 1979; **1**: 545 – 556.
4. Kantrow SM, Ivan D, Williams MD, Prieto VG, Lazar AJ. Metastasizing adenocarcinoma and multiple neoplastic proliferations arising in a nevus sebaceous. *Am J Dermatopathol.* 2007; **29**: 462 – 466.
5. Kazakov DV, Calonje E, Zelger B, Luzar B, Belousova IE, Mukensnabl P, et al. Sebaceous carcinoma arising in nevus sebaceous of Jadassohn: a clinicopathological study of five cases. *Am J Dermatopathol.* 2007; **29**: 242 – 248.
6. Arakawa Y, Nakai N, Katoh N. Rare case of basal cell carcinoma arising in a nevus sebaceous on the upper arm. *J Dermatol.* 2012; **39**: 931 – 932.
7. Belhadjali H, Moussa A, Yahia S, Njim L, Zakhama A, Zili J. Simultaneous occurrence of two squamous cell carcinomas within a nevus sebaceous of Jadassohn in an 11-year-old girl. *Pediatr Dermatol.* 2009; **26**: 236 – 237.
8. Jones EW, Heyl T. Naevus sebaceous. A report of 140 cases with special regard to the development of secondary malignant tumours. *Br J Dermatol.* 1970; **82**: 99 – 117.
9. Alessi E, Sala F. Nevus sebaceous. A clinicopathologic study of its evolution. *Am J Dermatopathol.* 1986; **8**: 27 – 31.
10. Mehregan AH, Pinkus H. Life history of organoid nevi. Special reference to nevus sebaceous of Jadassohn. *Arch Dermatol.* 1965; **91**: 574 – 588.
11. Hidvegi NC, Kangesu L, Wolfe KQ. Squamous cell carcinoma complicating naevus sebaceous of Jadassohn in a child. *Br J Plast Surg.*

- 2003; **56**: 50 – 52.
12. Dunkin CS, Abouzeid M, Sarangapani K. Malignant transformation in congenital sebaceous naevi in childhood. *J R Coll Surg Edinb.* 2001; **46**: 303 – 306.
 13. Hughes JR, O'Donnell PJ, Pembroke AC. Basal cell carcinoma arising in a naevus sebaceous in a 5-year-old girl. *Clin Exp Dermatol.* 1995; **20**: 177.
 14. Manonukul J, Omeapinyan P, Vongjirad A. Mucoepidermoid (adenosquamous) carcinoma, trichoblastoma, trichilemmoma, sebaceous adenoma, tumor of follicular infundibulum and syringocystadenoma papilliferum arising within 2 persistent lesions of nevus sebaceous: report of a case. *Am J Dermatopathol.* 2009; **31**: 658 – 663.
 15. Weng CJ, Tsai YC, Chen TJ. Jadassohn's nevus sebaceous of the head and face. *Ann Plast Surg.* 1990; **25**: 100 – 102.
 16. Aguayo R, Pallarés J, Casanova JM, Baradad M, Sanmartín V, Moreno S, et al. Squamous cell carcinoma developing in Jadassohn's sebaceous nevus: case report and review of the literature. *Dermatol Surg.* 2010; **36**: 1763 – 1768.
 17. Rosen H, Schmidt B, Lam HP, Meara JG, Labow BI. Management of nevus sebaceous and the risk of Basal cell carcinoma: an 18-year review. *Pediatr Dermatol.* 2009; **26**: 676 – 681.
 18. Smolin T, Hundeiker M. Prickle-cell and basal cell carcinoma in nevus sebaceous. *Z Hautkr.* 1985; **61**: 267 – 282.
 19. Paudel U, Jha A, Pokhrel DB, Gurung D, Parajuli S, Pant A. Apocrine carcinoma developing in a naevus sebaceous of scalp. *Kathmandu Univ Med J (KUMJ).* 2012; **10**: 103 – 105.
 20. Miller CJ, Ioffreda MD, Billingsley EM. Sebaceous carcinoma, basal cell carcinoma, trichoadenoma, trichoblastoma, and syringocystadenoma papilliferum arising within a nevus sebaceous. *Dermatol Surg.* 2004; **30**: 1546 – 1549.
 21. Stavrianeas NG, Katoulis AC, Stratigeas NP, Karagianni IN, Patertou-Stavrianea M, Varelzidis AG. Development of multiple tumors in a sebaceous nevus of Jadassohn. *Dermatology.* 1997; **195**: 155 – 158.
 22. Chun K, Vazquez M, Sanchez JL. Nevus sebaceous: clinical outcome and considerations for prophylactic excision. *Int J Dermatol.* 1995; **34**: 538 – 541.
 23. Jacyk WK, Requena L, Sanchez Yus E, Judd MJ. Tubular apocrine carcinoma arising in a nevus sebaceous of Jadassohn. *Am J Dermatopathol.* 1998; **20**: 389 – 392.
 24. Rinaggio J, McGuff HS, Otto R, Hickson C. Postauricular sebaceous carcinoma arising in association with nevus sebaceous. *Head Neck.* 2002; **24**: 212 – 216.
 25. Taher M, Feibleman C, Bennett R. Squamous cell carcinoma arising in a nevus sebaceous of Jadassohn in a 9-year-old girl: treatment using Mohs micrographic surgery with literature review. *Dermatol Surg.* 2010; **36**: 1203 – 1208.
 26. Arshad AR, Azman WS, Kreetharan A. Solitary sebaceous nevus of Jadassohn complicated by squamous cell carcinoma and basal cell carcinoma. *Head Neck.* 2008; **30**: 544 – 548.