

Photoclinic

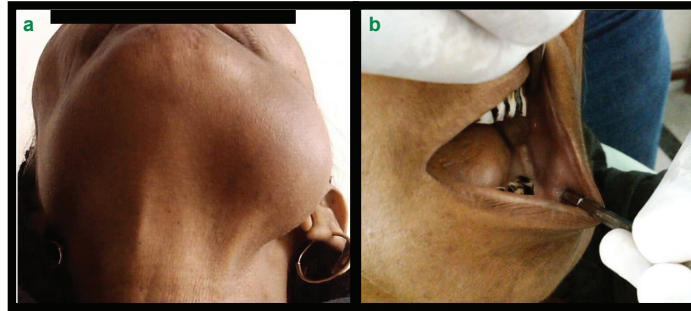


Figure 1. Gross facial asymmetry (1a), Intra-oral photograph (1b).

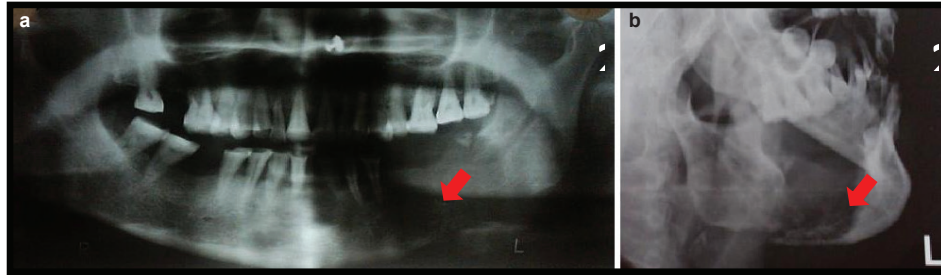


Figure 2. Orthopantomogram (2a) and left lateral oblique body (2b) radiograph revealed osteolytic lesion with indistinct borders, with pathological fracture line (arrow marked).

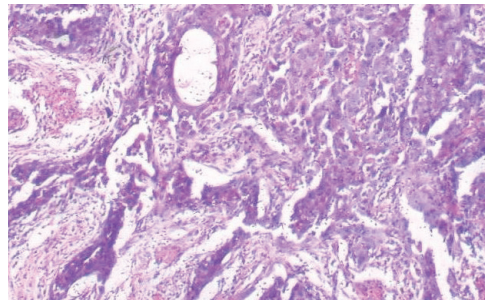


Figure 3. Malignant squamous epithelial tumor islands, infiltrating the fibrous connective tissue stroma. (H & E, 40 \times)

Cite this article as: Sah K, Chandra S, Grover N, Gupta S. Photoclinic. *Arch Iran Med.* 2014; **18**(2): 135 – 136.

A 50-year-old female patient reported with a chief complaint of dull continuous pain, numbness, loosening of teeth and swelling in lower left back region of the jaw since two months. General physical examination revealed sign of anemia with pale conjunctiva, and with noncontributory medical history. There was no history of trauma.

Extra-oral examination revealed gross facial asymmetry with a diffuse, firm and tender swelling of 6 \times 5 cm, involving the left posterior lower jaw (Figure 1a). Left submandibular and cervical

lymph nodes were palpable, tender and firm in consistency.

Intra-oral examination revealed a bony hard swelling of approximately 2.3 \times 2 cm in relation to 34 to 37 region (edentulous), with obliteration of left buccal and to some extent lingual vestibule (Figure 1b). The orthopantomograph and left lateral oblique body radiograph revealed an osteolytic lesion with indistinct borders (midline to angle of the mandible) with pathological transverse fracture (Figures 2a and 2b).

Based on the clinical and radiological findings, a differential diagnosis of odontogenic pathology and osteomyelitis was made. Microscopic examination revealed numerous malignant squamous epithelial tumor islands (keratinized-type) of different sizes infiltrating the fibrous connective tissue stroma (Figure 3). Serial sections of the specimen were taken to exclude the presence of odontogenic cystic lining epithelium or any other odontogenic tumor. To rule out metastatic tumor to the jaw, chest X-ray, whole-body CT scan and bone scintigraphy were performed, but were noncontributory.

**What is your diagnosis?
See the next page for diagnosis.**

Kunal Sah BDS MDS¹, Sunira Chandra BDS MDS², Neeraj Grover BDS MDS³, Suchitra Gupta BDS MDS³

Authors' affiliations: ¹Department of Oral Pathology and Microbiology, ²Department of Oral Medicine and Radiology, Saraswati Dental College and Hospital, Lucknow, Uttar Pradesh, India. ³Department of Oral Pathology and Microbiology, D. J. College of Dental Sciences and Research, Ghaziabad, Uttar Pradesh, India.

• **Corresponding author and reprints:** Kunal Sah BDS MDS, Department of Oral Pathology and Microbiology, Saraswati Dental College and Hospital, Faizabad Road, 233 Tiwari Ganj, Lucknow-227105, Uttar Pradesh, India. Tel: +91-9758970400, E-mail: steps_32kunal@hotmail.com, kunalsah@saraswaticolleges.com Accepted for publication: 31 December 2014

Photoclinic Diagnosis:

Primary (*de novo*) Intraosseous Carcinoma of the Mandible (type 3A), Causing Pathological Fracture

Primary intraosseous carcinoma (PIOC) was first described by Loos in 1913, and the term was suggested by the WHO in 1972.¹ Later, Waldron and Mustoe's classification of PIOC is widely accepted and frequently cited.²

- Type 1: PIOC arising from odontogenic cyst
 - Type 2
 - Type 2A: Malignant ameloblastomas
 - Type 2B: Ameloblastic carcinoma arising *de novo* from ameloblastoma or from odontogenic cyst
 - Type 3
 - Type 3A: PIOC arising *de novo*: keratinizing
 - Type 3B: PIOC arising *de novo*: nonkeratinizing
 - Type 4: Intraosseous (central) mucoepidermoid carcinoma
- PIOC arising *de novo* has been infrequently reported. It arises principally within the jaw bone, with posterior mandible being the most common site. It is usually noticed during the sixth to seventh decade, with a mean age of 50 years, having male predominance.³ The diagnostic criteria proposed for PIOC are as follows^{1,3}:
- Absence of initial connection with the overlying mucosa or skin
 - Microscopic evidence of squamous cell carcinoma without a cystic component or other odontogenic tumor cells
 - Absence of another primary tumor on chest radiographs obtained at the time of diagnosis and during a follow-up period of more than 6 months

Various types of metastatic carcinoma (thyroid, kidney, prostate, lungs, etc.) to the jawbone should be ruled out by carefully reviewing the history and comprehensive systemic evaluation of the patient. PIOC usually exhibits marked variation in radiography and is worth considering as a differential diagnosis of jaw radiolucency. Confirmation of PIOC is only through histopathology.²

The most accepted treatment for PIOC is radical surgery with adequate resection. Radiotherapy and chemotherapy are used as palliative therapy/adjuvant therapy in cases of nerve infiltration.

Metastasis to cervical lymph nodes has been described more frequently in *de novo* PIOC, therefore prophylactic neck dissection is recommended.¹

Lin, et al., reported a 2-year survival rate of 53% for the type-1 entity, whereas Elazy demonstrated a 2-year survival rate of 40% for the *de novo* lesion. These findings indicate that PIOC's originating from odontogenic cysts have a better prognosis than the *de novo* lesions.²

The present case of PIOC is reported in a 50-year-old female patient causing pathological fracture of mandible, and meets all the above mentioned diagnostic criteria of *de novo* PIOC.

Presentation at a meeting: NA

Organization: Nil

Place: Nil

Date: Nil

Conflicting Interest (If present, give more details): Nil

Acknowledgment

The present case was recorded when all the authors were the faculty member of Teerthanker Mahaveer Dental College & Research Center, Teerthanker Mahaveer University, Moradabad, Uttar Pradesh, India.

References

1. Adachi M, Inagaki T, Ehara Y, Azuma M, Kurenuma A, Motohashi M, et al. Primary intraosseous carcinoma arising from an odontogenic cyst: a case report. *Oncol Lett.* 2014; **8(3)**: 1265 – 1268.
2. Lin YJ, Chen CH, Wang WC, Chen YK, Lin LM. Primary intraosseous carcinoma of the mandible. *Dentomaxillofac Radiol.* 2005; **34(2)**: 112 – 116.
3. Gallego L, Junquera L, Villarreal P, Fresno MF. Primary *de novo* intraosseous carcinoma: report of a new case. *Med Oral Patol Oral Cir Bucal.* 2010; **15(1)**: e48 – e51.