

Case Report

Ewing's Sarcoma of Proximal Humeral Epiphysis

Heydar Ali Esmaili MD¹, Mohammad Taghi Niknejad MD^{•2}, Shiva Mohajeri MD¹**Abstract**

Ewing's sarcoma is one of the most common primary bone tumors of childhood. The tumor is almost always metaphyseal or diaphyseal, within long bones. In children, lesions of the epiphysis are often benign, with the most common diagnosis being chondroblastoma. Rarely, 1%–2% of Ewing sarcomas may involve epiphysis. We present a case of Ewing's sarcoma of the proximal humeral epiphysis in a 13-year-old boy. This case adds to previously reported cases of epiphyseal Ewing sarcoma and suggests that the diagnosis should be considered for pediatric epiphyseal lesions.

Keywords: Epiphysis, Ewing's sarcoma, primary malignant bone tumor

Cite this article as: Esmaili HA, Niknejad MT, Mohajeri S. Ewing's Sarcoma of Proximal Humeral Epiphysis. Arch Iran Med. 2015; **18**(2): 133 – 134.

Introduction

Epiphyseal bone lesions are often benign in skeletally immature patients. A study on a large series of 2758 tumor cases 1996 confirmed chondroblastoma as the most frequent epiphyseal bone tumor, especially in the second decade of life. There were no cases of primary malignant bone tumor of the epiphysis in that study.¹

Ewing sarcoma is the second most common primary bone tumor of childhood after osteosarcoma, and typically occurs in children and adolescents between 10 and 20 years of age, and has a slight male predilection.^{2–3}

Ewing's sarcoma is a small-blue-round-cell tumor and closely related to the soft tissue tumors pPNET, Askin tumor and neuroepithelioma, which collectively are referred to as Ewing's sarcoma family of tumors (ESFT).²

Ewing's sarcoma is more commonly seen in the appendicular skeleton and typically involves the femur, tibia, humerus, or fibula. As for location within long bones, the tumor is almost always metaphyseal or diaphyseal (mid-diaphysis: 33%, metadiaphysis: 44%, metaphysis: 15%). Rarely, 1%–2% of Ewing sarcomas may involve epiphysis.^{3–4} This article presents a case of primary Ewing's sarcoma of the proximal humeral epiphysis in a 13-year-old boy.

Case Report

A 13-year-old boy, a gymnast, initially noted right shoulder pain during exercise 6 weeks prior to presentation. After 4 weeks of resting and on returning to the sport, that the pain recurred and progressed over several days. He reported pain on activity, and occasional night pains which were somewhat alleviated by analgesics such as ibuprofen and acetaminophen/codeine. His range of motion was limited. He was then referred to the authors' hospital for more evaluation.

Authors' affiliation: ¹Department of Pathology, Tabriz University of Medical Sciences, Tabriz, Iran. ²Department of Radiology, Tabriz University of Medical Sciences, Tabriz, Iran.

Corresponding author and reprints: Mohammad Taghi Niknejad MD, Department of Radiology, Tabriz University of Medical Sciences, Azadi Ave., Golgasht Ave., Tabriz, Iran. Tel: +98-411-334-5591, Email: dr_niknejadrad@yahoo.com
Accepted for publication: 18 June 2014

Radiograph of the shoulder revealed a well-defined and lytic lesion within the right proximal humeral epiphysis (Figure 1). On magnetic resonance imaging (MRI), a chondroid tumor of the epiphysis was found with surrounding soft tissue and metaphyseal edema (Figure 2).

Based on the patient's age, the findings of imaging, and the lesion's anatomical location, a primary diagnosis of chondroblastoma was made and the patient was taken to the operating room for a confirmatory biopsy of the lesion.

Microscopic examination showed a cellular malignant tumor with foci of necrosis and infiltration of subarticular marrow spaces. Tumoral cells had uniformly round nuclei, indistinct nucleoli in some of them and high nucleo-cytoplasmic ratio. Scattered mitosis and foci with rosette formation could be seen. Histologic features were those of a malignant small-round-blue-cell neoplasm (Figure 3). Immunohistochemical staining was positive for Vimentin, CD99 and Synaptophysin, but negative for Ck, S100 protein, Desmin and CD45 (Figure 4). The histopathologic findings were consistent with Ewing's sarcoma.

Discussion

Ewing's sarcoma accounts for approximately 3% of all malignant childhood tumors and males are slightly more prone to it. Presentation is non-specific with local pain being by far the most common symptom. The pain gets progressively worse and does not remit. Swelling and a mass, especially when the tumor is located in an extremity, may be seen.^{6–7} Ewing's sarcoma can involve any bone, with approximately 50% of cases involving long bones and approximately 30% occurring in pelvis.⁸ As for location within long bones, the tumor is almost always metaphyseal or diaphyseal.^{3–4}

In 1984, the Intergroup Ewing's Sarcoma Study, identified 206 patients with Ewing's sarcoma of bone in study on 7299 cases; of these, only one patient (0.5%) presented with a lesion in the epiphysis.⁹ In 2003, a case of epiphyseal Ewing's sarcoma of the proximal tibial epiphysis was reported.¹⁰ Another report was published regarding primitive neuroectodermal tumor of the epiphysis in a 5-year-old patient with a lytic lesion in the distal femoral epiphysis that was confirmed by immune-histochemical findings.¹¹ Most recently a similar case of Ewing's sarcoma/primitive neuroecto-

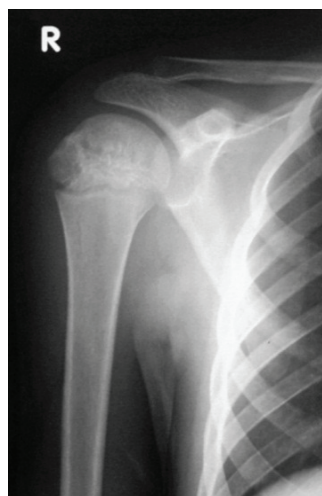

Figure 1. Anteroposterior radiograph of the right shoulder showing a well-defined lytic epiphyseal lesion.

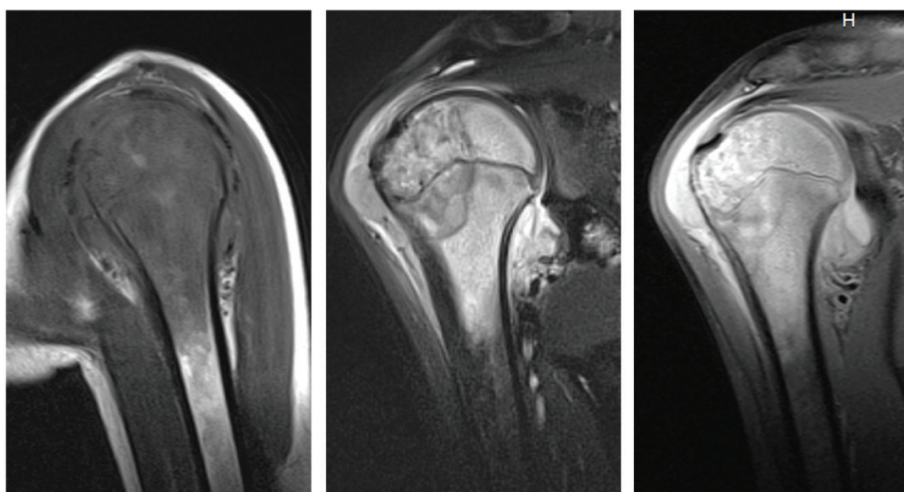


Figure 2. Sagittal T1, Coronal T2, and PD, MRI of the right shoulder with an epiphyseal tumor and surrounding soft tissue and metaphyseal edema.

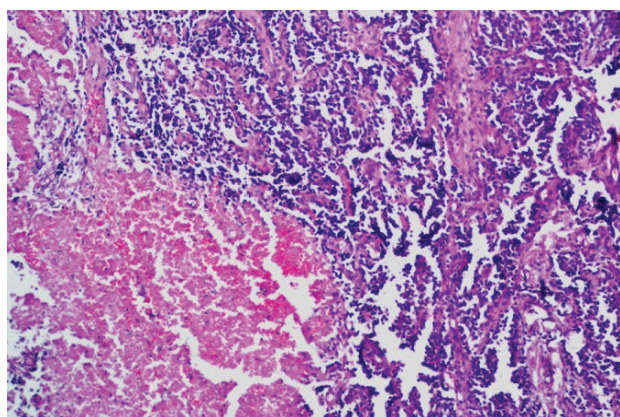


Figure 3. Photomicrograph of a proximal humerus epiphyseal tumor (H & E, 40x).

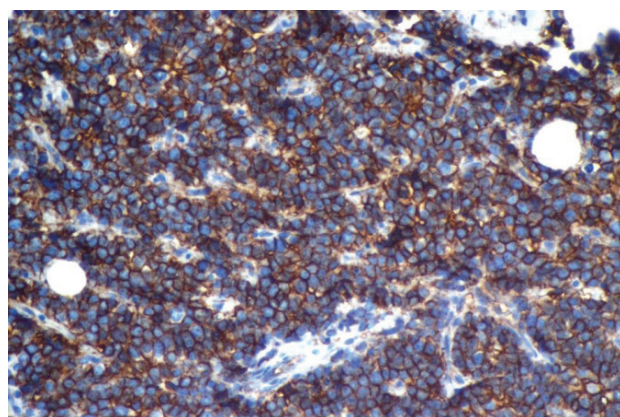


Figure 4. Immuno-histochemical staining with positive CD99 membrane pattern (H & E, 40x).

dermal tumor of the proximal humeral epiphysis was reported in a 12-year-old patient which was confirmed by molecular testing.¹²

Although metadiaphyseal locations for Ewing's sarcoma are most common, epiphyseal disease is also possible. This case adds to the limited but mounting evidence that Ewing's sarcoma should be considered in the differential diagnosis of pediatric epiphyseal tumors.

References

- Hovy L. Epiphyseal tumors. *Z Orthop Ihre Grenzgeb.* 1996; **134**(5): 413 – 417.
- Burchill SA. Ewing's sarcoma: diagnostic, prognostic, and therapeutic implications of molecular abnormalities. *J. Clin. Pathol.* 2003; **56**(2): 96 – 102.
- Maygarden SJ, Askin FB, Siegal GP, Gilula LA, Schoppe J, Foulkes M, et al. Ewing sarcoma of bone in infants and toddlers. A clinicopathologic report from the Intergroup Ewing's Study. *Cancer.* 1993; **71**(6): 2109 – 2118.
- Moser RP, Davis MJ, Gilkey FW, Kransdorf MJ, Rosado de Christenson ML, Kumar R, et al. Primary Ewing sarcoma of rib. *Radiographics.* 1990; **10**(5): 899 – 914.
- Maheshwari AV, Cheng EY. Ewing sarcoma family of tumors. *J Am Acad Orthop Surg.* 2010; **18**(2): 94 – 107.
- Green DM. *Diagnosis and Management of Malignant Solid Tumors in Infants and Children.* Boston, MA: Martinus Nijhoff Pub.; 1985. doi:10.1007/978-1-4613-2623-6
- Wilkins RM, Pritchard DJ, Burgert EO Jr., Unni KK. Ewing's sarcoma of bone: experience with 140 patients. *Cancer.* 1986; **58**(11): 2551 – 2555.
- Peersman B, Vanhoenacker FM, Heyman S, Van Herendael B, Stam M, Brys P, et al. Ewing's sarcoma: imaging features. *JBR-BTR.* 2007; **90**(5): 368 – 376.
- Reinus WR, Gilula LA. IESS Committee: radiology of Ewing's sarcoma: intergroup Ewing's sarcoma study. *Radiographics.* 1984; **4**: 929 – 944
- Moscolo DL, Campaner G, Aponte-Tinao LA, Ayerza MA, Santini-Araujo E. Epiphyseal primary location for osteosarcoma and Ewing's sarcoma in patients with open physis. *J Pediatr Orthop.* 2003; **23**(4): 542 – 545.
- Kowalczyk B, Lejman T, Drabik G, Załęska-Czepko E. Primary epiphyseal localization of primitive neuroectodermal tumor in a child. *Eur J Radiol.* 2011; **78**: e77 – e80.
- Morris P, Dickman PS, Seidel MJ. Ewing's sarcoma/primitive neuroectodermal tumor of the proximal humeral epiphysis. *Orthopedics.* 2013; **36**(1): e113 – e116.