

## Case Report

# Wolf-Hirschhorn Syndrome: A Case with Normal Karyotype, Demonstrated by Array CGH (aCGH).

Alihossein Saberi PhD<sup>1,2</sup>, Gholamreza Shariati MD<sup>1,2</sup>, Mohammad Hamid PhD<sup>2,3</sup>, Hamid Galehdari PhD<sup>2,4</sup>, Nehzat Abdorasouli MSc<sup>2</sup>

## Abstract

Wolf-Hirschhorn syndrome (WHS) is a disorder that affects many parts of the body. The major features of this condition include specific craniofacial malformations, delayed growth and development, intellectual disability and seizures. Here, we report a case of WHS: a 27-month-old girl with a microdeletion at distal part of short arm of chromosome 4. She had striking clinical features of WHS and had an apparently normal karyotype. Array comparative genomic hybridization performed on the DNA extracted from peripheral blood revealed loss of 1.7Mb at 4q16.3-q15.3. Taken together, this data suggests that a patient with strong clinical suspicion of chromosome abnormality and normal conventional karyotype analysis should be further evaluated by molecular cytogenetic techniques such as array comparative genomic hybridization (aCGH) or fluorescence in situ hybridization (FISH).

**Keywords:** Array CGH, wolf-Hirschhorn syndrome, 4p16.3 deletion

**Cite this article as:** Saberi A, Shariati G, Hamid M, Galehdari H, Abdorasouli N. Wolf-Hirschhorn syndrome: A case with normal karyotype, demonstrated by array CGH (aCGH). *Arch Iran Med.* 2014; **17**(9): 642 – 644.

## Introduction

Wolf-Hirschhorn syndrome (WHS) is one of multiple malformation syndromes which affects 1 in 50000 live birth with a 2 : 1 female-to-male ratio.<sup>1</sup> It is associated with partial deletion of distal portion of the p arm of chromosome 4 and is considered as a contiguous gene syndrome.<sup>2</sup> In many cases, WHS is not inherited. They result from a random (*de novo*) event during the formation of reproductive cell (egg or sperm) or in early embryonic development.<sup>3</sup> A small percentage of all individuals with WHS develop the disorder as a result of an unusual chromosome abnormality such as a ring chromosome 4. In the remaining cases of WHS, the affected individuals inherit a copy of chromosome 4 with a deleted segment. In these cases, one of the individual's parents carries a balanced translocation between chromosome 4 and the other chromosome. The length of deletion regions is associated with the specific clinical phenotype.<sup>4</sup> Loss of critical regions, including WHSCR1, WHSCR2, LETM1 and MSX1 genes, is indeed associated with typical signs and symptoms of this disorder.<sup>5</sup> The key features of the WHS are as follows: mild to severe mental retardation, hypotonia, growth delay, seizures, and specific craniofacial manifestations.<sup>3</sup> Some of these cases do not show clinical presentations consistent with WHS, whereas others have features which overlap with some of the WHS phenotype. In this paper, we present a case of deletion of genomic segment on the distal part of short arm of chromosome 4

with loss of multiple overlapping genes. Chromosomal studies were verified by array comparative genome hybridization (aCGH).

## Case Report

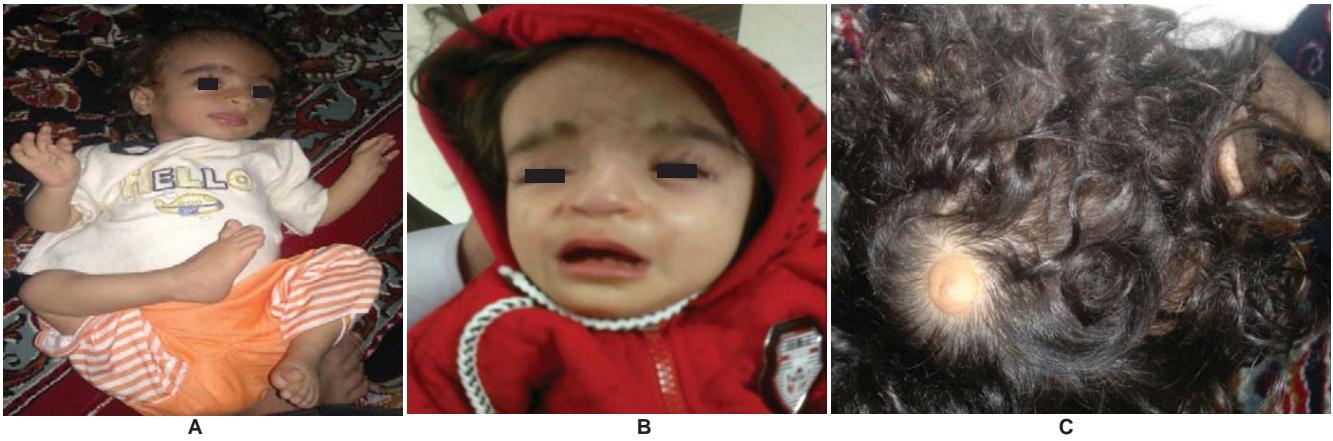The proband was a 27-month-old girl presenting with dysmorphic features, developmental delay, atrial septal defect (ASD), pulmonary stenosis (PS) and mental retardation. She was the second child born to non-consanguineous healthy parents. The father was 31 years old and the mother was 26 years old at the time of the delivery. At the age of 11 months, she was admitted to hospital due to failure to thrive (FTT) and was found to have cyanotic changes secondary to ASD with left-to-right shunt and PS.

The clinical examination revealed marked growth retardation, microcephaly, prominent glabella, short philtrum, high forehead, big skin tag on the vertex, hypotonia, strabismus, wide nasal bridge, and down-turned corners of mouth (Figure 1). She was referred for genetic assessment at the age of 27 months. We performed chromosome analysis using the patient's peripheral blood lymphocytes by conventional GTG-banding. She revealed 46,XX normal karyotype. Then, her blood sample was taken and DNA extraction and purification were carried out by standard protocol. 1500 ng of DNA was used for array-CGH analysis. Array-CGH was performed using cytochip ISCA 4x44\_2309\_V1oligo array (BlueGnome, Cambridge, UK) to evaluate genomic gain and losses at location approximately 75kb across the entire human genome. It was then analyzed using BlueFuse Multi software. We defined chromosomal gain as above 0.4 normalized  $\log_2$ -ratio and chromosomal loss as below -0.4 normalized  $\log_2$  ratio. In our case, the result of array-CGH showed loss of 1.7Mb at 4p16.3 (Figure 2) which was not detectable in conventional karyotype. This region overlaps 120 HGNC genes including WHSC1, WHSC2, LETM1 and MSX1 genes.

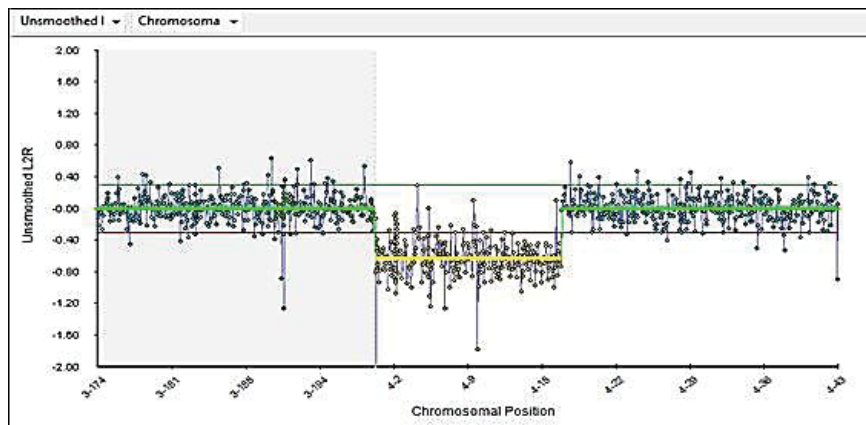
**Authors' affiliations:** <sup>1</sup>Department of Medical Genetics, Faculty of Medicine, Ahvaz Jundishapur university of Medical Sciences, Ahvaz, Iran, <sup>2</sup>Narges Genetic Lab, Ahvaz, Iran, <sup>3</sup>Department of molecular Medicine, Biotechnology section, Research Center, Pasteur institute of Iran, Tehran, Iran, <sup>4</sup>Department of Genetics, Faculty of Sciences, Shahid Chamran university, Ahvaz, Iran.

**Corresponding author and reprints:** Alihossein Saberi MD, Department of Medical Genetics, Faculty of Medicine, Ahvaz Jundishapur university of Medical Sciences, Ahvaz, Iran, 2Narges Genetic Lab, No. 18, East Mihan, Kianpars, Ahvaz, Iran. E-mail: ahsaberi70@hotmail.com.

Accepted for publication: 27 May 2014



**Figure 1.** A) photograph of patient at 27 months of age; B) facial features of the patient; C) a tag on the head



**Figure 2.** Array CGH result. Loss below -0.4 normalized log<sub>2</sub> ratio, gain above 0.4 normalized log<sub>2</sub> ratio. Thus, the chromosome 4p showed 1.7 Mb deletion.

## Discussion

The variability of WHS presentation has been attributed to the size of deletions with a minimum critical region of 165kb.<sup>6</sup> Zollino, et al.<sup>4</sup> defined a patient with deletion of 5 – 8Mb as “classic WHS”, which presents with severe psychomotor delay and commonly has major malformations. Our case with 1.7 Mb deletion is consistent with several features reported in the literatures as diagnostic markers for WHS, which include microcephaly, mental retardation, growth retardation, hypotonia, congenital heart defects and prominent glabella. Moreover, other features such as beaked nose, hypertelorism, nystagmus, and coloboma, have been reported to occur at low frequency.<sup>7</sup> The variation in the size of the deleted segment and the effect of gene interaction might explain the absence of other reported phenotypes of WHS in this patient. The phenotypic severity in this case is consistent with the length of deletion spanning WHSCR1, WHSCR2, LETM1, MSX1 and FGFR1 genes. The deleted region spans all the genes involved in the development of the main features of WHS and other multiple genes that act as master regulators of different developmental pathways. Haploinsufficiency of MSX1 gene probably disrupts the regulation of several associated genes, particularly those involved in the development of the mouth and facial dysmorphism.<sup>8,9</sup> Hence, in our case, facial dysmorphism could be related

to the deletion of MSX1 gene. Moreover, the plausible candidate gene for a part of craniofacial phenotype of WHS has been traced to the FGFR1 gene in our case.<sup>10</sup>

The conventional microscopic cytogenetic study is sometimes unable to detect either microdeletion or microduplication, whereas array-CGH has demonstrated a highly diagnostic yield in patients with multiple congenital anomalies and mental retardation syndromes, including WHS.<sup>11,12</sup> In many cases, metaphase fluorescence in situ hybridization has been recently used to check for chromosomal anomalies.<sup>13</sup> However, the array CGH study is more informative in determining the length of either deletion or duplication associated with the clinical phenotype. Therefore, it is currently considered as a useful tool for detection of aneuploidies, well characterized microdeletion/microduplication syndromes and subtelomeric or other unbalanced chromosomal rearrangements.

## References

1. Shanon NL, Maltby EL, Rigby AS, Quarrell WJ. An epidemiology study of Wolf-Hirschhorn: life expectancy and cause of mortality. *Journal of Medical Genetics*. 2001; **38**(10): 674 – 679.
2. Battaglia A, Fillipi T, Carey JC. Update on the clinical features and natural history of Wolf-Hirschhorn(4p-)syndrome. Experience with 87 patients and recommendations for routine health supervision, *American Journal of Medical Genetics*. 2008; **148**(4): 264 – 251.

3. Wieczorek D, Krause M, Majewski F, Albrecht B, Meinecke P, Riess O, et al. Unexpected high frequency of de novo unbalanced translocation with wolf-Hirschhorn syndrome (WHS). *Journal of Medical Genetics*. 2000; **37(10)**: 798 – 804.
4. Zollino M, Lecce R, Fischetto R, Murdolo M, Faravelli F, Selicorni A, et al. Mapping the Wolf-Hirschhorn syndrome phenotype outside the currently accepted WHS critical region and defining new critical region, WHSCR-2. *American journal of Human Genetics*. 2003; **72(3)**: 590 – 597.
5. Battaglia A, Carey JC, South ST, Wright TJ. Wolf-Hirschhorn syndrome in *gene review*, Pagon RA, Bird TD, Dolan CR, Stephens K, eds. University of Washington, Seattle, Wash, USA, 2010.
6. Wright TJ, Rike DO, Denison K, Abmayr S, Cotter PD, Hirschhorn K, et al. A transcript map of the newly defined 165kb Wolf-Hirschhorn syndrome critical region. *Hum Mol Genet*. 1997; **6**: 366 – 370
7. Sheth F, Aknide OR, Datar C, Adeteye OV, Sheth J. Genotype-phenotype characterization of Wolf-hirschhorn syndrome confirmed by FISH: Case report. *Case Report in Genetics*. 2012; 2012: Article ID 878796.
8. Silva ER, Reis-Filho CR, Napimoga MH, Alves JB. Polymorphism in the MSX1 gene associated with hypotonia in the Brazilian family. *Journal of Oral Science*. 2009; **51(3)**: 341 – 345.
9. Johnston NJ, Franklin DL. Dental findings of a child with Wolf-Hirschhorn syndrome. *International Journal of Pediatric Dentistry*. 2006; **16(2)**: 139 – 142.
10. Hammond P, Hannes F, Suttie M, Devriendt K, Vermeesch JR. Faravelliet al Fine-grained facial phenotype-genotype analysis in Wolf-Hirschhorn syndrome. *European Journal of Human Genetics*. 2012; **20(1)**: 33 – 40.
11. de Ravel TJ, Devriendt K, fryns JP, Vermeesch JR. What's new in karyotyping? The move towards array comparative genome hybridization (CGH). *Eur J pediatr*. 2007; **166**: 637 – 643.
12. South ST, Withby H, Battaglia A, Carey JC, Brothman AR. Comprehensive analysis of Wolf-Hirschhorn syndrome using array CGH indicates a high prevalence of translocation. *Eur J Hum Genet*. 2008; **16**: 45 – 52.
13. Park HK, Kim HJ, Han SH, Kim YJ, Kim SH. Screening of subtelomeric rearrangements in 100 Korean pediatric patients with unexplained mental retardation and anomalies using subtelomeric FISH (Fluorescence in situ hybridization). *J Korean Med. Sci*. 2008; **23**: 573 – 578.