

Photoclinic

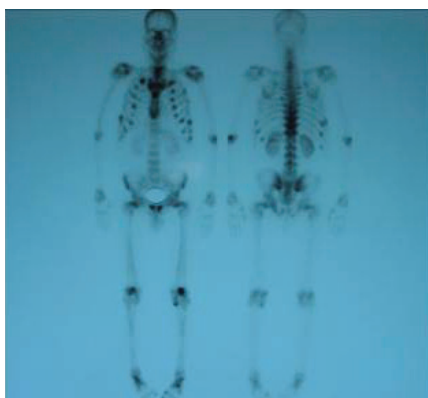

Figure 1. Bone scan of a 54-year-old man

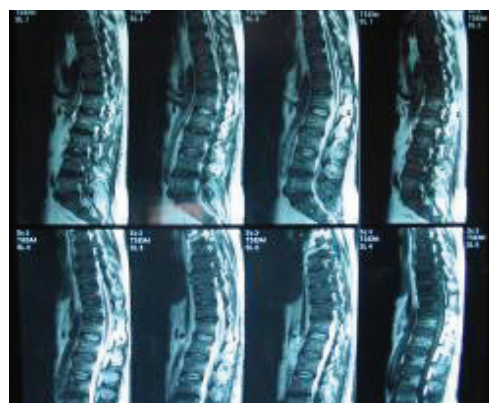

Figure 2. Thoracolumbosacral MRI of the patient

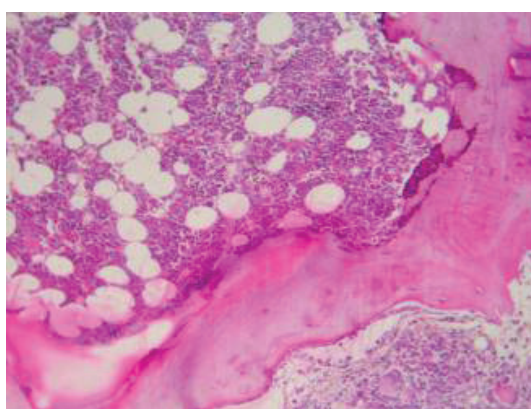


Figure 3. Bone biopsy picture (H&E ×100)

A 54-year-old male smoker presented with complaints of generalized bone and muscle pain. His pain was aggravated over time to the extent that he became unable to walk and developed paraparesis. Upon physical examination, a tumor was not located, however, generalized bony tenderness with decreased muscle strength, predominantly in the lower extremities was noted. On lung examination, bilateral scattered wheezing was heard.

The patient underwent a bone scan which revealed multiple metabolically active bony lesions in the ribs (mainly in the costochondral junctions), sternum, low-

er cervical and thoracic spine that was suspicious for multiple bony metastases versus metabolic bone disease (Figure 1). Thoracolumbosacral magnetic resonance imaging (MRI) results revealed hypersignal intensity on T1 and T2 images that favored replacement of red marrow with fat (Figure 2).

Imaging studies which included: spiral chest, abdominopelvic, and paranasal CT-scans were unremarkable.

Both bone and bone marrow biopsies to detect the primary tumor location were normal (Figure 3). Serum phosphate level was 1.8 mg/dL, urine phosphate was 103mg/dL, and parathyroid hormone was within the normal range.

The patient had an undetectable serum 1,25-dihydroxyvitamin D and severe osteomalacia per a dual energy X-ray absorptiometry (DEXA) bone densitometry.

**What is your diagnosis?
See the page 254 for diagnosis**

Mehdi Dehghani MD¹, Mohammad Hossein Dabagmanesh MD²,
Golam Hossein Omrani MD²

Authors' affiliations: ¹Department of Hematology and Oncology, Hematology Research Center, Shiraz University of Medical Sciences, Shiraz, Iran. ²Endocrine and Metabolism Research Center, Shiraz University of Medical Sciences, Shiraz, Iran.

Corresponding author and reprints: Mehdi Dehghani MD, Department of Hematology and Oncology, Hematology Research Center, Shiraz University of Medical Sciences, Shiraz, Iran. Fax:+98-711-647-4301, E-mail: mehdi_dehghani6@yahoo.com

Oncogenic osteomalacia (OOM) is an interesting subject that has preoccupied physicians for decades. The traditional name for this disorder, OOM, implies a paraneoplastic phenomenon, secondary to a tumor. Such characterization is inaccurate, however, in that the involved “neoplasm” is often (but not always) of limited clinical significance, apart from its causal role in musculoskeletal disease. Tumors responsible for OOM are usually benign rather than malignant; whereas generalized debilitating osteomalacia and rickets are important clinical problems for the patient.¹

In OOM, a tumor produces an unknown substance that inhibits phosphate reabsorption in the proximal tubules. This causes urinary phosphate wasting and, as a consequence, hypophosphatemic osteomalacia.²

Osteomalacia is associated with many clinical (bone pain and weakness), radiographic (compression fracture), and biochemical abnormalities (increased alkaline phosphatase).³

Unfortunately, none of these are pathognomonic for the disorder, and histological examination of a bone biopsy specimen is often necessary to confirm the diagnosis. Noninvasive methods of diagnosis would be preferable to decrease patient morbidity and increase cost-effectiveness.³

Tumor-induced hypophosphatemic osteomalacia is a syndrome characterized by urinary phosphate wasting related to the presence of a slowly-growing tumor of mesenchymal origin. The characteristic laboratory findings are normal serum calcium, marked hypophosphatemia, increased serum alkaline phosphatase, markedly reduced renal tubular reabsorption of phosphorus and inappropriately low levels of 1,25-dihydroxyvitamin D [1,25-(OH)₂D].⁴

Because of the difficulty in locating the primary tumor, total body magnetic resonance imaging MRI, octreotide scintigraphy, and PET/CT are helpful diagnostic tools.^{1,5,6}

Localization of the tumor site is an important consideration in treating patients with OOM. The

clinical course is dramatically affected by tumor removal and, if possible, is the treatment of choice.^{7,8}

If the primary site can not be located or complete tumor excision is not possible, treatment with high doses of vitamin D or its potent derivatives and phosphate supplements are recommended in patients with hypophosphatemic osteomalacia. Treatment with calcitriol (up to 3 mcg/day) and phosphate (2 – 4 g/day) will improve both osteomalacia and muscle weakness. Metabolic balance studies have shown the additional effect of calcium supplements during the first 4 – 6 months of healing.⁹

References

1. Carpenter TO. Oncogenic osteomalacia—a complex dance of factors. *N Engl J Med.* 2003; **348**: 1705 – 1708.
2. Jonsson KB, Mannstadt M, Miyauchi A, Yang IM, Stein G, Ljunggren O, et al. Extracts from tumors causing oncogenic osteomalacia inhibit phosphate uptake in opossum kidney cells. *J Endocrinol.* 2001; **169**: 613 – 620.
3. Bingham CT, Fitzpatrick LA. Noninvasive testing in the diagnosis of osteomalacia. *Am J Med.* 1995; **99**: 107 – 108.
4. Tartaglia F, Minisola S, Sgueglia M, Blasi S, Brunelli D, Degli Effetti E, et al. Tumor-induced hypophosphatemic osteomalacia associated with tertiary hyperparathyroidism: a case report. *G Chir.* 2006; **27**: 9 – 13.
5. Nelson AE, Mason RS, Robinson BG, Hogan JJ, Martin EA, Ahlström H, et al. Diagnosis of a patient with oncogenic osteomalacia using a phosphate uptake bioassay of serum and magnetic resonance imaging. *Eur J Endocrinol.* 2001; **145**: 469 – 476.
6. Khadgawat R, Singh Y, Kansara S, Tandon N, Bal C, Seith A, et al. PET/CT localisation of a scapular haemangiopericytoma with tumour-induced osteomalacia. *Singapore Med J.* 2009; **50**: e55 – e57.
7. Kumar K, Halkar TK. Tumor-induced osteomalacia (TIO) (also known as oncogenic osteomalacia). *Appl Radiol.* 2008; **37**: 9 – 24.
8. Agus ZS. Oncogenic hypophosphatemic osteomalacia. *Kidney Int.* 1983; **24**: 113 – 123.
9. Clunie GP, Fox PE, Stamp TC. Four cases of acquired hypophosphatemic (‘oncogenic’) osteomalacia. Problems of diagnosis, treatment and long-term management. *Rheumatology (Oxford).* 2000; **39**: 1415 – 1421.