

Septic Arthritis of Sternoclavicular Joint: A Case Report of a Rare Finding in Injecting Drug Users

Reza Ghasemi Barghi MD¹, Seyed Mostafa Mirakbari MD²

Abstract:

The sternoclavicular joint is an unusual site for bacterial infection. In this case, we describe a 25-year-old man who presented to the emergency department with fever, chills, limited range of motion in the right upper limb along with complaints of severe pain and tenderness in the right upper chest wall and shoulder. He was admitted to the hospital for further evaluation. This patient admitted to a history of injecting heroin use during the previous three months. The diagnosis of septic arthritis of the right sternoclavicular joint was confirmed by blood culture and MRI of the sternoclavicular joint. This case is, to the best of our knowledge, the 25th recorded staphylococcal septic sternoclavicular arthritis. He received appropriate intravenous antibiotic therapy and subsequently was discharged two weeks later with complete clinical and laboratory recovery.

Keywords: Injecting drug use - septic arthritis - sternoclavicular joint (SCJ)

Introduction

Septic arthritis of the sternoclavicular joint (SCJ) is a rare disease.¹⁻³ The risk factors for this disease include immuno-compromising diseases, injection drug use, fracture of the clavicle bone, subclavian vein catheterization, rheumatoid arthritis, primary and secondary malignant lesions, diabetes and hemodialysis.²⁻⁵

Given the rarity and insidious onset of this disease, its diagnosis may be delayed or even missed until complications occur.^{1,2,6-8} Because of the serious and life-threatening complications of this disease,⁶⁻⁷ early recognition and diagnosis followed by immediate treatment is of utmost importance. This report describes an injecting drug user who developed septic sternoclavicular arthritis, thus becoming the 25th patient with culture-proven staphylococcal arthritis of the SCJ.⁹

Case Report

A 25-year-old man referred to the emergency department with complaints of a seven day history of

severe pain in the right upper limb, right shoulder and upper right chest. He indicated that the symptoms had increased in intensity over the previous week, such that on the last day he was not able to move his right upper limb. During this period he experienced fever and chills. He described the chills as a chill sensation, not as shaking. He had visited a general physician the week prior who prescribed intra-muscular benzathin penicillin and oral cephalexin. The patient refused to take oral cephalexin. He was a driver and had begun injection drug use three months before this illness. Also, he smoked ten cigarettes daily.

On examination, the patient had a toxic appearance with the following vital signs: T=39.5°C, RR=18/min, PR=84/min, BP=130/80 mmHg. Examination of head and neck, eyes, ears, nose, and pharynx were normal. Chest examination was unremarkable except for severe tenderness on the right SCJ. Cutaneous tracks and scars were evident at the right elbow, reflecting chronic intravenous drug use. No carotid thrills and bruits were detected. Jugular venous pulse was not visible. Laboratory tests showed the following results: WBC 13800/mm³ (PMN 80%), ESR 46 mm/hr, Hgb 12.1g/dL, CRP 3⁺. FBS, urinalysis, BUN/Cr, Wright and Coomb's Wright tests were all within normal limits. The chest X-ray was normal. Three blood cultures were obtained and treatment with ceftazidim, vancomycin and gentamicin was immediately started. Blood culture results were positive for methicillin-sensitive

Authors' affiliations:¹Department of Infectious Disease, Bu Ali Hospital, ²Department of Internal Medicine, Bu Ali Hospital, Qazvin University of Medical Sciences, Qazvin, Iran.

Corresponding author and reprints: Seyed Mostafa Mirakbari MD, Department of Internal Medicine, Bu Ali Hospital, Qazvin University of Medical Sciences, Qazvin, Iran.

E-mail: dmirakbari@yahoo.com

Accepted for publication: 12 March 2009

Staphylococcus aureus (MSSA) that was sensitive to ciprofloxacin, vancomycin, gentamycin, co-trimoxazole, ceftriaxone and resistant to penicillin and clindamycin. Therefore we modified the patient's antibiotic therapy regimen by discontinuing ceftazidim and gentamicin, and adding ceftriaxone to the treatment protocol to form the combination therapy of ceftriaxone and vancomycin.

Echocardiography was performed, but did not reveal any valvular vegetations or pericardial effusions. An MRI of the SCJ demonstrated articular space distension with effusion without evidence of bone involvement (Figure 1). Doppler sonography of the carotid arteries and jugular veins were normal. His general condition improved significantly after 48 hours and the fever subsided after four days. After one week of antibiotic therapy, the patient's blood culture was negative for MSSA. The laboratory results normalized 12 days after treatment (WBC 8600/mm³ and ESR 25). Antibiotic therapy was continued for two weeks. The patient was discharged with clinical and laboratory improvement and continued treatment with oral cefixime.

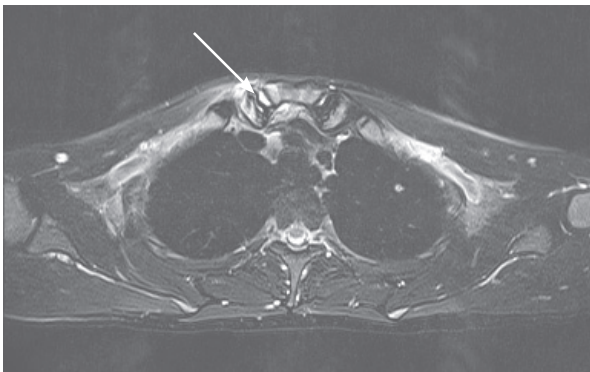


Figure 1. MRI of the SCJ in a 25-year-old man, demonstrating joint space widening and intra-articular effusion

Discussion

Septic arthritis of the SCJ is rare. It comprises approximately 0.5 – 1% of all joint infections^{1,4}; however, for unclear reasons, 17% of the infections are in intravenous drug users.⁴ Bacteria may enter the SCJ from the adjacent valves of the subclavian vein after injection of contaminated drugs into the upper extremity, or the joint may become infected after attempted drug injection between the heads of the sternocleidomastoid muscle.^{4,8}

Septic arthritis of the SCJ most commonly affects the younger age group¹⁰ but can affect individu-

als with no known risk factors.⁴ From a systematic review of the literature on septic arthritis, Wohlgethon et al.⁶ found that, in a high percentage of cases (20%), infection of the SCJ leads to an abscess.⁶ The time elapsed before diagnosis is established can be from a few days up to two months.² It may appear several weeks after subclavian venous catheterization.⁸ In our case the clinical findings of fever, chest pain, shoulder pain and severe pain in the SCJ are consistent with other reports. In the case of delayed diagnosis and treatment, complications may develop which include mediastinitis, retrosternal abscess, phlegmon formation in the chest wall, osteomyelitis, septic shock, and superior vena cava syndrome.^{2,4} Diagnosis is established through clinical findings, bone and joint radiography, bone and joint CT/MRI, and blood culture.^{4,8,11} Bone scan and MRI are more sensitive for the earlier diagnosis of SCJ involvement than plain radiography and CT. Other diseases to be differentiated from SCJ arthritis include: rheumatoid arthritis, osteoarthritis, Tietze syndrome, rheumatic fever, gout and tumor lesions and less common etiologies such as brucellosis, prevotella and *Mycobacterium tuberculosis*.^{2,7} Empirical antibiotic treatment covering methicillin-resistant *Staphylococcus aureus* is required for all patients. Surgical follow-up is necessary in the case of phlegmon formation in the chest wall and retrosternal abscess.²

Even though SCJ septic arthritis is an uncommon disease, it should be considered in any injecting drug user and immunocompromised patient that present with shoulder and chest discomfort. Given the serious and life-threatening consequences of this disease, early detection and diagnosis is recommended. Patients will respond better to early treatment.

References

1. Mikroulis DA, Verettas DA, Xarchas KC, Lawal LA, Kazakos KJ, Bougioukas GJ. Sternoclavicular joint arthritis and mediastinitis. A case report and review of literature. *Arch Orthop Trauma Surg.* 2008; **128**: 185 – 187.
2. Mohyuddin A. Sternoclavicular joint septic arthritis manifesting as a neck abscess: a case report. *Ear Nose Throat J.* 2003; **82**: 618 – 621.
3. Ho G Jr. Bacterial arthritis. *Curr Opin Rheumatol.* 1991; **3**: 603 – 609.
4. Ross JJ, Shamsuddin H. Sternoclavicular septic ar-

- thrititis: review of 180 cases. *Medicine (Baltimore)*. 2004; **83**: 139 – 148.
5. Covelli M, Lapadula G, Pipitone N, Numo R, Pipitone V. Isolated sternoclavicular joint arthritis in heroin addicts and/or HIV positive patients: three cases. *Clin Rheumatol*. 1993; **12**: 422 – 425.
 6. Wohlgethon JR, Newberg AH, Reed JI. The risk of abscess from sternoclavicular septic arthritis. *J Rheumatology*. 1988; **15**: 1302 – 1306.
 7. Ely GM. Septic arthritis of the sternoclavicular joint and osteomyelitis of the proximal clavicle caused by *Prevotella melaninogenica*. A case with several features delaying diagnosis. *J Clin Rheumatol*. 1999; **5**: 354 – 359.
 8. Aglas F, Gretler J, Rainer F, Krejs GJ. Sternoclavicular septic arthritis: a rare but serious complication of subclavian venous catheterization. *Clin Rheumatol*. 1994; **13**: 507 – 512.
 9. Cone LA, Lopez C, O'Connell SJ, Nazemi R, Sneider RE, Denker H. Staphylococcal septic synovitis of the sternoclavicular joint with retrosternal extension. *J Clin Rheumatol*. 2006; **12**: 187 – 189.
 10. Akkasilpa S, Osiri M, Ukritchon S, Junsirimongkol B, Deesomchok U. Clinical features of septic arthritis of sternoclavicular joint. *J Med Assoc Thai*. 2001; **84**: 63 – 68.
 11. Pradhan C, Watson NF, Jagasia N, Chari R, Patterson JE. Bilateral sternoclavicular joint septic arthritis secondary to indwelling central venous catheter: a case report. *J Med Case Reports*. 2008; **29**; **2**: 131.

Online Submission

Submit your manuscripts online on the Archives of Iranian Medicine website:

www.aimjournal.ir

Please register only once for all your manuscripts