

Case Report

Multiple Endocrine Neoplasia Type 2A in an Iranian Family: Clinical and Genetic Studies

Ali Asghar Ghazi MD¹, Mahmoud Bagheri MD², Ali Tabibi MD³, Farzaneh Sarvghadi MD¹, Hengameh Abdi MD^{•1}, Mehdi Hedayati PhD¹, Marina Pourafkari MD⁴, Farrokh Tirgari MD⁵, Run Yu MD PhD⁶

Abstract

Multiple endocrine neoplasia (MEN) type 2A, a dominant inherited syndrome caused by germline activating mutations in the RET proto-oncogene, is characterized by association of medullary thyroid carcinoma, pheochromocytoma and primary hyperparathyroidism. There is limited data on this disease in the Middle East region. In this paper, we present clinical and genetic studies of an Iranian patient and her family members. The patient was a 49-year old Iranian woman who presented with hypertension due to bilateral pheochromocytoma. She had history of a medullary carcinoma of thyroid which had been operated 28 years ago. Analysis of the RET gene in the family revealed a C⁶³⁴R mutation in codon 11 and 3 polymorphisms, G⁶⁹¹S, S⁸³⁶S and S⁹⁰⁴S in codons 11, 14 and 15, respectively, that might have been important in modifying the clinical picture. Due to paucity of information on MEN type 2 in the area, this study can be helpful in portraying the clinical and cytogenetic characteristics of the disease in the region.

Keywords: genetic polymorphism, MEN2A, RET mutation

Cite this article as: Ghazi AA, Bagheri M, Tabibi A, Sarvghadi F, Abdi H, Hedayati M, et al. Multiple endocrine neoplasia type 2A in an Iranian family: Clinical and genetic studies. *Arch Iran Med.* 2014; **17**(5): 378 – 382.

Introduction

Multiple endocrine neoplasia type 2A (MEN 2A) is an unusual dominantly inherited disorder which presents with medullary thyroid cancer (MTC), bilateral pheochromocytoma (PHEO) and primary hyperparathyroidism (PHPT).^{1,2} In more than 95% of cases, the disease is due to a single point mutation in RET (re-arranged during transfection) gene. RET gene contains 21 exons, is located in chromosome 10q11.2 and encodes a tyrosine kinase receptor that induces abnormal growth and differentiation of cells derived from neural crest, including C cells of the thyroid and cells of the adrenal medulla.^{3,4}

There is little information on the clinical and cytogenetic characteristics of MEN2A syndrome in Middle Eastern countries. In this paper, we present for the first time the clinical, laboratory and genetic characteristics of an Iranian family, in which the index case had MEN 2A secondary to Cys⁶³⁴Arg mutation and presented with medullary thyroid carcinoma, bilateral pheochromocytoma and primary hyperparathyroidism. Cytogenetic study of the index case, her mother, her son and the siblings also revealed 3 polymorphisms; Gly⁶⁹¹Ser, Ser⁸³⁶Ser and Ser⁹⁰⁴Ser.

Authors' affiliations: ¹Endocrine Research Center, Research Institute for Endocrine Sciences, Shahid Beheshti University of Medical Sciences, Tehran, Iran, ²Kasra General Hospital, Tehran, Iran, ³Urology Research Center, Shahid Beheshti University of Medical Sciences, Tehran, Iran, ⁴Department of Radiology, Taleghani General Hospital, Shahid Beheshti University of Medical Sciences, Tehran, Iran, ⁵Department of Pathology, Imam Khomeini General Hospital, Tehran University of Medical Sciences, Tehran, Iran, ⁶Carcinoid and Neuroendocrine Tumor Center, Cedar-Sinai Medical Center, UCLA, USA.

•Corresponding author and reprints: Hengameh Abdi MD, Endocrine Research Center, Research Institute for Endocrine Sciences, Shahid Beheshti University of Medical Sciences, No. 24, Parvaneh St., Yemen St., Chamran Exp, Tehran, Iran. P. O. Box: 19395-4763. Tel: +98-21-22432500, Fax: +98-21-22416264, Cell: +98-911-1322650, E-mail: hengamehabdi@gmail.com. Accepted for publication: 27 February 2014

Case Report

A 49-year old woman was referred to us for evaluation of palpitation, profuse sweating and attacks of severe headache. Her past medical history was significant for a total thyroidectomy when she was 21 years old that was histopathologically proved to be a 5 × 2 cm medullary thyroid carcinoma and attacks of severe hypertension up to 210/140 mmHg during the last 1.5 years. Laboratory evaluations for hypertension disclosed high urine catecholamine metabolites, normal calcitonin, high serum PTH, negative MIBG scan of adrenals and bilateral adrenal tumors. She ignored further evaluation and used only amlodipine and metoprolol to control the symptoms. She was a professional mountaineer and had climbed successfully the Kilimanjaro Peak in Africa and Mont Blanc in Europe during this period despite palpitations and blood pressure of around 180/115 mmHg.

On examination, her heart rate was 105 per minute and her blood pressure was 190/95 mmHg. The rest of physical examination was unremarkable. The laboratory data on admission is shown in Table 1. A computed tomography (CT) scan of the abdomen revealed bilateral suprarenal masses approximately 5 × 3 cm in size with soft tissue consistency (Figure 1). Bilateral pheochromocytoma was suspected based on the patient's history, laboratory data and radiologic findings. After controlling hypertension with phenoxybenzamine and propranolol, the patient underwent bilateral transperitoneal laparoscopic adrenalectomy through lateral approach, first for the right side and then for the left side in one session. The completely excised tumors measured 6 × 4.5 × 2.5 cm each. Cut sections revealed 2 lobulated brownish tumors, surrounded by adrenal tissue. Microscopic examination revealed pheochromocytoma. Immunohistochemistry (IHC) evaluation showed positivity for chromogranin, synaptophysin and S 100. KI 67 was estimated as 1%. IHC was negative for CKAE1 and

Table 1. Laboratory data of the patient before surgery; abnormal values are in bold.

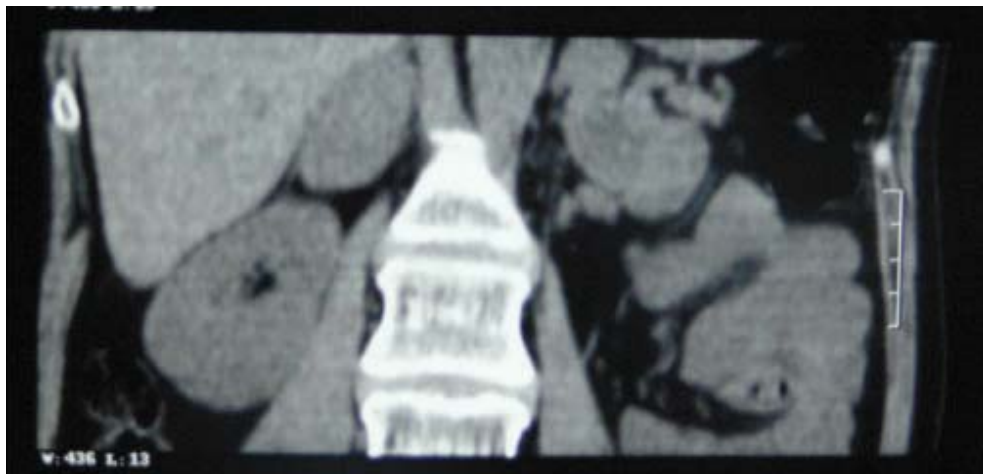	Oct 2010	Jan 2011	July 2012	Reference range
Urine metanephrine ($\mu\text{g}/24\text{h}$)	2950	2870	2300	< 350
Urine normetanephrine ($\mu\text{g}/24\text{h}$)	2470	5600	3000	< 600
Urine VMA (mg/24h)	---	13.3	---	< 13.6
Serum calcitonin (pg/ml)	---	4.0	7.7	< 14
Serum CEA (ng/ml)	---	---	1.6	< 3.6
Serum calcium (mg/dl)	10.2	10.4	10.4	8.6–10.3
Serum phosphorus (mg/dl)	3.5	3.0	4.1	2.5–4.5
Serum iPTH (pg/ml)	74.0	190	115	7.0–82
Serum 25(OH)D (ng/ml)	---	< 4	21.0	30–100

VMA: Vanillylmandelic acid; CEA: Carcinoembryonic antigen; iPTH: Intact parathormone

Table 2. Laboratory data of the patient after surgery: abnormal values are in bold.

	One week	One year	Reference range
Urine metanephrine ($\mu\text{g}/24\text{h}$)	48	37	< 350
Urine normetanephrine ($\mu\text{g}/24\text{h}$)	498	324	< 600
Serum calcitonin (pg/ml)	---	3.2	< 14
Serum CEA (ng/ml)	---	1.7	< 3.6
Serum calcium (mg/dl)	8.9	10.6	8.6–10.3
Serum phosphorus (mg/dl)	3.8	---	2.5–4.5
Serum iPTH (pg/ml)	123	117	7.0–82
Serum 25(OH)D (ng/ml)	---	23.0	30–100

CEA: Carcinoembryonic antigen; iPTH: Intact parathormone

**Figure 1.** Adrenal CT imaging of the patient

AE111.

Sequencing of the RET proto-oncogene was completed at the Research Institute for Endocrine Sciences affiliated with Shahid Beheshti University of Medical Sciences, Tehran, Iran. The study showed Cys⁶³⁴Arg mutation and 3 polymorphisms; Gly⁶⁹¹Ser, Ser⁸³⁶Ser and Ser⁹⁰⁴Ser (Figure 2).

The post-operative course was uneventful and the patient's hypertension and palpitation disappeared after surgery. One week after surgery, urine catecholamine metabolites and serum calcium were within normal limits but serum PTH was still high. One year after surgery, the patient was examined again. She was normotensive (120/80 mmHg) and did not suffer from palpitation or headache. The patient's post-operative laboratory data is shown in Table 2. The patient's family, her mother, her son, two brothers and two sisters were clinically evaluated and also underwent cytogenetic study. There were no clinical findings in favor of MEN 2A in the family. The family's pedigree and results of biochemical evaluation of the family members are shown in Figure 3 and Table 3, respectively.

Discussion

In this paper, we present for the first time the clinical, laboratory and cytogenetic characteristics of an Iranian patient with MEN 2A harboring C⁶³⁴R mutation and 3 polymorphisms. The data of her first degree relatives are also presented.

The syndrome of multiple endocrine neoplasia is a rare autosomal dominant disorder with a prevalence of 2.5/100,000 population. It was introduced to medical literature in 1961 and subsequently shown to comprise 3 forms: MEN 2A, MEN 2B and familial MTC (FMTC). MEN 2A is the most prevalent form and presents with MTC in 95% of cases, bilateral pheochromocytoma in 50% of the cases and primary hyperparathyroidism in 25% of cases.^{5,6}

In 1993, a linkage was shown between the syndrome and gain of function mutations in RET gene, which encodes for a ligand dependent membrane receptor with tyrosine kinase activity regulating cell growth and differentiation.^{7,8} Naturally, the receptor is activated by a complex generated from glial derived neurotropic

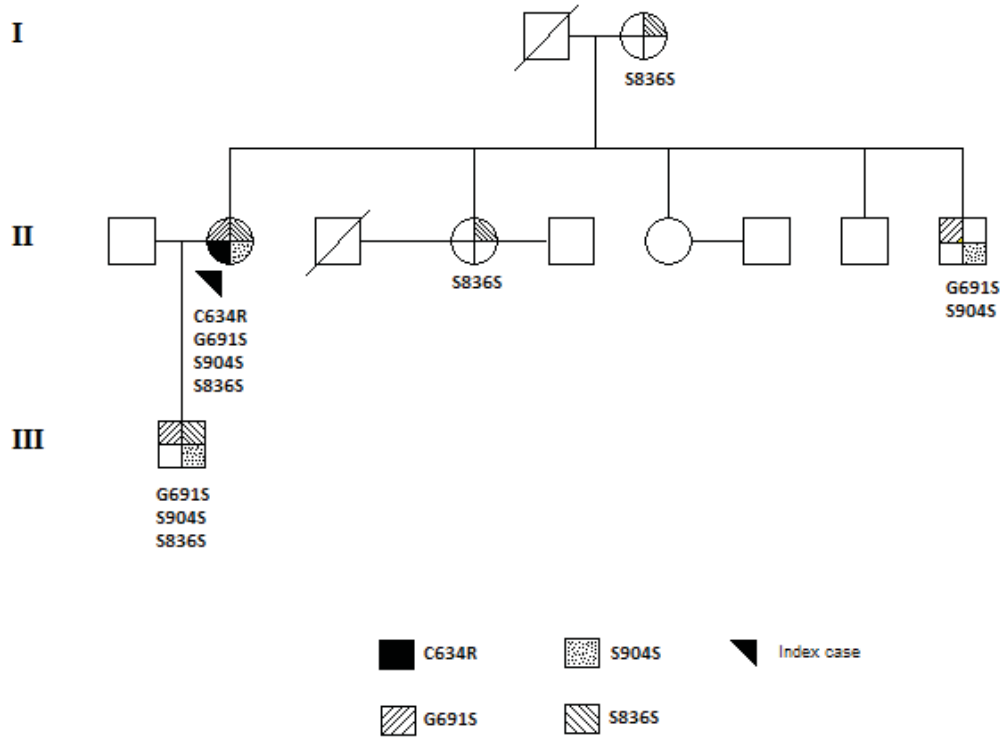


Figure 3. Family pedigree

factor (GDNF) ligands and a co-receptor that leads to autophosphorylation and intracellular signaling. With mutant genes, there happens a state of repetitive stimulation with increased intracellular phosphorylation that eventually leads to hyperplasia and tumor formation. It was subsequently shown that each type of MEN2 syndrome is the result of a specific mutation in the RET gene and it was also shown that mutations have different effects on cellular function and behavior. As a rule, mutations that cause more profound derangements in the receptor function lead to development of tumors that are more malignant and appear at an earlier age. The findings gave rise to the concept that there is a strong correlation between phenotype (clinical presentation) and genotype (gene characteristics) of the disease. The discoveries led to application of more accurate cytogenetic technics for diagnosis of affected family members in subclinical stages and paved the way for implementation of prophylactic measures such as thyroidectomy for elimination of the disease in carriers of defective genes.^{1,9}

A mutation at codon 634, located in exon 11, is seen in 85% of patients with MEN 2A and substitution of Arginine for Cysteine, C⁶³⁴R, is the most common one.^{1,3,10} Most patients with MEN 2A who present with PHEO or PHPT also harbor C⁶³⁴R mutation. Our patient is likely to have inherited the mutation from her deceased father.

As mentioned earlier, different mutations lead to tumors with different behaviors. According to the guideline of the American Thyroid Association (ATA), these mutations can be divided into 4 categories (A to D) based on the aggressiveness of the corresponding tumors and age at which tumors become clinically evident. According to this classification, mutations in category A lead to tumors that appear in later life and have more benign behavior while mutations in category D appear early in life and have poorer prognosis. Based on these data, codon 634 is in category C.

MTC develops in almost all patients with C⁶³⁴R mutation and is usually the first manifestation. In contrast to sporadic MTC which appears in the fifth decade of life, those who harbor C⁶³⁴R mutation have been reported to have the tumor even before the age of 5 years.¹¹ The RET screening program has improved the prognosis of MTC dramatically. While the 5-year survival of clinically detected MTC is about 50%, those diagnosed through RET sequencing have a cure rate of around 94%. A major factor in this improvement is detection of tumors at an early stage.¹² It was thus recommended that all patients with MTC should be evaluated for RET mutations and those harboring C⁶³⁴R mutation should undergo prophylactic thyroidectomy before the age of 5 years.⁶ The clinical course of the disease in our patient is somehow unusual. While most patients with clinically detectable tumors have cervical lymph node metastasis and elevation of calcitonin post-surgically, she had normal calcitonin levels 20 years after surgery.

Pheochromocytoma develops in approximately 50% of patients with MEN 2A. A recent study from Japan showed that penetrance of PHEO is 25% by 30 years of age, 52% by 50 years of age and 88% by 77 years of age in carriers of mutations in codon 634.¹³ The tumor is always intra-adrenal, may appear bilaterally and have benign nature in the majority of cases. It can appear before, during or after development of MTC in patients with mutation in codon 634. Biochemical screening for pheochromocytoma is advised to begin at 8 years of age in carriers of mutation in codon 634.^{6,14}

Primary hyperparathyroidism is seen in 15% – 25% of patients. In most cases, the diagnosis of the disease is synchronous with that of MTC. It is clinically asymptomatic in 80% of cases and is usually diagnosed with mild elevation of serum calcium and mild to moderate elevation of serum PTH. There can be a spectrum of histopathologic abnormalities, ranging from single adenoma, dou-

ble adenoma or hyperplasia in four glands.¹⁵ Our patient had no symptoms attributable to PHPT and based on the calcium level, we preferred to follow the patient annually.

The pathogenic significance of polymorphisms is not well known. There are studies both in favor of and against the contributing role of polymorphisms or variants of unknown significance in tumor genesis.^{2,16} In the 2 synonymous polymorphisms of our patient, S⁹⁰⁴S and S⁸³⁶S, since there is no change in the amino acid sequence, it seems that there should be no change in the functional ability of the corresponding protein. This assumption cannot be the case in the G⁶⁹¹S variant where the polar serine substitutes for the neutral glycine; a change that might have detrimental effects on functional characteristics of the receptor. However, Fugazzola et al demonstrated that this variant had no effect on functional activity of the tyrosine receptor.¹⁷

In this paper, we have demonstrated the clinical, biochemical and laboratory manifestations of an Iranian family with complete features of MEN 2A. The case is somehow unusual for benign behavior of a clinically evident MTC for about 30 years and occurrence of 3 polymorphisms that might have had contributing effects on the tumor characteristics. Further studies are needed to evaluate the findings in a sufficient number of patients in order to portray a more accurate picture of the disease in the region.

Acknowledgments

The authors would like to express their appreciation and gratitude to family members for their cooperation and Ms. Marjan Zarif Yeganeh for her excellent laboratory assistance.

Declaration of Conflicting Interests

None of the authors had any personal or financial conflicts of interest.

References

1. Raue F, Frank-Raue K. Genotype-phenotype correlation in multiple endocrine neoplasia type 2. *Clinics (Sao Paulo)*. 2012; **67 (suppl 1)**: 69 – 75.
2. Machens A, Dralle H. Multiple endocrine neoplasia type 2: achievements and current challenges. *Clinics (Sao Paulo)*. 2012; **67 (suppl 1)**: 113 – 118.
3. Eng C, Clayton D, Schuffenecker I, et al. The relationship between specific RET proto-oncogene mutations and disease phenotype in multiple endocrine neoplasia type 2. International RET mutation consortium analysis. *JAMA*. 1996; **276**: 1575 – 1579.
4. Moline J, Eng C. Multiple endocrine neoplasia type 2: an overview. *Genet Med*. 2011; **13**: 755 – 764.
5. Sipple J. The association of pheochromocytoma with carcinomas of the thyroid gland. *Am J Med* 1961; **31**: 163 – 166.
6. Kloos RT, Eng C, Evans DB, et al. Medullary thyroid cancer: management guidelines of the American Thyroid Association. *Thyroid*. 2009; **19**: 565 – 612.
7. Mulligan LM, Kwok JB, Healey CS, et al. Germ-line mutations of the RET proto-oncogene in multiple endocrine neoplasia type 2A. *Nature*. 1993; **363**: 458 – 460.
8. Donis-Keller H, Dou S, Chi D, et al. Mutations in the RET proto-oncogene are associated with MEN 2A and FMTC. *Hum Mol Genet*. 1993; **2**: 851 – 856.
9. Hubner RA, Houlston RS. Molecular advances in medullary thyroid cancer diagnostics. *Clin Chim Acta*. 2006; **370**: 2 – 8.
10. Egawa S, Futami H, Takasaki K, et al. Genotype-phenotype correlation of patients with multiple endocrine neoplasia type 2 in Japan. *Jpn J Clin Oncol*. 1998; **28**: 590 – 596.
11. Salehian B, Samoa R. RET gene abnormalities and thyroid disease: who should be screened and when. *J Clin Res Pediatr Endocrinol*. 2013; **5 (suppl 1)**: 70 – 78.
12. Imai T, Uchino S, Okamoto T, et al. High penetrance of pheochromocytoma in multiple endocrine neoplasia 2 caused by germ line RET codon 634 mutation in Japanese patients. *Eur J Endocrinol*. 2013; **168**: 683 – 687.
13. Machens A, Brauckhoff M, Holzhausen HJ, Thanh PN, Lehnert H, Dralle H. Codon-specific development of pheochromocytoma in multiple endocrine neoplasia type 2. *J Clin Endocrinol Metab*. 2005; **90**: 3999 – 4003.
14. Raue F, Kraimps JL, Dralle H, et al. Primary hyperparathyroidism in multiple endocrine neoplasia type 2A. *J Intern Med*. 1995; **238**: 369 – 373.
15. Elisei R, Cosci B, Romei C, et al. RET exon 11 (G691S) polymorphism is significantly more frequent in sporadic medullary thyroid carcinoma than in the general population. *J Clin Endocrinol Metab*. 2004; **89**: 3579 – 3584.
16. Fugazzola L, Muzza M, Mian C, et al. RET genotypes in sporadic medullary thyroid cancer: studies in a large Italian series. *Clin Endocrinol (Oxf)*. 2008; **69**: 418 – 425.
17. Machens A, Frank-Raue K, Lorenz K, Rondot S, Raue F, Dralle H. Clinical relevance of RET variants G691S, L769L, S836S and S904S to sporadic medullary thyroid cancer. *Clin Endocrinol (Oxf)*. 2012; **76**: 691 – 697.