

Case Report

Posterior Mediastinal Cyst

Manouchehr Aghajanzadeh MD¹, Sina Khajeh Jahromi MD^{•2}, Rasool Hassanzadeh MD², Hannan Ebrahimi MD²**Abstract**

Hydatid disease is still an important health problem in the world. Mediastinal localization of hydatidosis is very rare. We report the case of a 19-year-old man who presented with right chest wall pain and cough. Chest X-Ray and computed tomography showed a mediastinal cystic mass. A right posterolateral thoracotomy was performed and the cystic mass was identified. Daughter cysts were seen within the cyst when the lesion was accidentally opened during the procedure. Cyst mass was radically resected. No complication or recurrence was seen in the follow-up period.

Keywords: Hydatid cyst, mediastinum, thoracotomy

Cite this article as: Aghajanzadeh M, Khajeh Jahromi S, Hassanzadeh R, Ebrahimi H. Posterior mediastinal cyst. *Arch Iran Med.* 2014; **17**(1): 95 – 96.

Case Report

A 19-year-old man was admitted to our department with right side chest wall pain, chronic cough and dyspnea. The postero-anterior chest X-Ray revealed posterior mediastinal mass. The patient was in good general condition. All clinical examinations and laboratory tests were normal. Thoracic computed tomography revealed a cystic mass in the posterior mediastinum. The mass measured 11.5 cm × 8.5 cm with water attenuation and unenhanced wall, (Figure 1). Serological tests for hydatid disease (anti-hydatid antibodies by ELISA, indirect hemagglutination and immuno-electrophoresis) were negative. A right postero-lateral thoracotomy was performed through the sixth intercostal space. During exploration, a cystic mass was discovered in an extrapleural location in the middle portion of the thoracic cavity attached to the spinal cord. As cystic lesion was found in the pleural cavity, we covered the cyst with sponge saline wet. When the lesion was accidentally opened during the procedure, daughter cysts were seen. The cyst was irrigated with hypertonic saline solution. Germinative laminated membrane and daughter cysts were removed (Figures 2, 3). Gross and histopathologic examinations of the excised operative material also confirmed the diagnosis of hydatid cyst. The patient was given 800 mg daily of albendazole for 3 months postoperatively. Post-operative ultrasound scan showed no hydatid cyst in liver. The patient's postoperative course was uneventful and he was discharged six days later. On follow-up, regular chest X-Ray showed no evidence of recurrence.

Discussion

Hydatid cyst still remains an important problem in developing countries.¹⁻³ It can be located in various tissues⁴⁻⁵ and mediastinal hydatid cyst is not exception. Mediastinal hydatid cysts are very rare and constitute less than 0.1 % of all localizations and less

than 1 % in thorax.^{2,4} Mediastinal hydatid cysts occur more frequently in the posterior mediastinum and calcifications are more frequently seen in these cysts.^{2,4}

In our patient, the cyst was isolated and primitive. The mechanism which leads to spread of the parasite is not clearly known. However, the parasite localizes in the region after passing the hepatic and pulmonary filter, probably via an arterial branch of the thoracic aorta or via lymphatics.⁶ Most patients are asymptomatic⁷ and may present with non-specific symptoms such as chest pain, cough and dyspnea. Also pulmonary parenchymal involvement can cause hemoptysis.⁸ Generally, the lesion is usually discovered incidentally on a routine chest X-Ray.^{2,7}

Chest X-Ray and thoracic computed tomography scan (CT scan) can facilitate diagnosis of a cystic mass. Mediastinal calcified cyst and multivesicular cyst can attract the physician's attention to hydatid disease in endemic regions. CT scans are able to provide excellent information about anatomical features of the cyst. However, there are no pathognomonic signs of hydatid cystic disease. This kind of cyst usually appears as a round cyst.^{2,4,7} When the patient presents with neurological signs or spinal involvement is probable, magnetic resonance imaging (MRI) can be of more assistance than a CT scan.⁵ As hydatid disease primarily involves the liver, systematic abdominal ultrasound should be performed in all cases.² In our case liver ultrasonography showed normal results.

Although serological tests are useful, they can be negative when the cyst is intact and uncomplicated. Although CT guided fine needle aspiration is still a dangerous technique (increasing the risk of dissemination and anaphylactic shock), it can be useful for diagnosis of hydatid cysts.⁹

Bronchogenic cyst, enteric cyst, cystic lymphangioma and neurogenic tumors are differential diagnosis of mediastinal hydatid cysts.^{2,7} In our case, the diagnosis of neurogenic tumor was suggested first. There are different complications related to mediastinal hydatid cyst such as rupture into the mediastinum, pleural cavity and right ventricle, compression of vital structures and infection.²

Surgery can eradicate the hydatid cyst, prevent intrathoracic rupture and excise the residual cavity.^{2,7} The procedure is usually best performed using a postero-lateral or antero-lateral thoracotomy. Taking maximal precautions during the procedure can only re-

Authors' affiliations: ¹Department of thoracic surgery, Guilan University of Medical Sciences, Razi hospital, Rasht, Iran, ²Student Research Committee, Medical Faculty, Guilan University of Medical Sciences, Rasht, Iran.

Corresponding author and reprints: Sina Khajeh Jahromi MD, Student Research Committee Office, Research Deputy Building of Guilan University of Medical Sciences, Shahid Beheshti Blvd, Rasht, Iran. Tel: +98-912-5088373, Fax: +98-131-3228842, E-mail: sina.khajehjahromi@gmail.com.

Accepted for publication: 19 November 2013

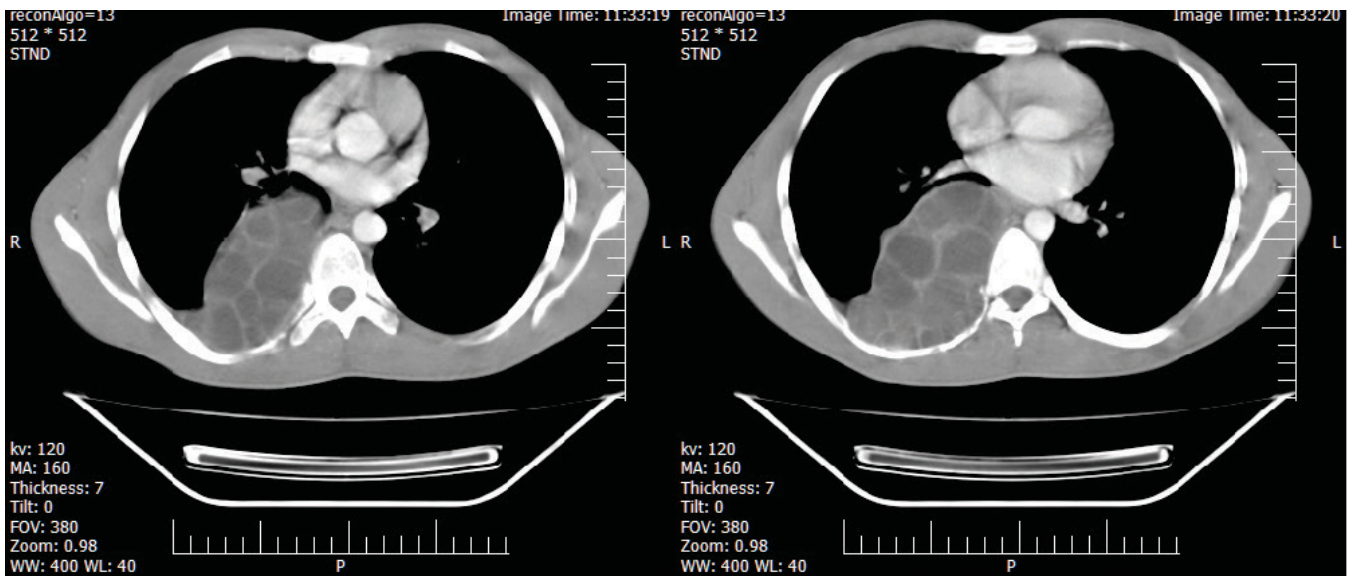


Figure 1. CT scan of chest with IV contrast shows a cystic and solid mass of posterior mediastinum

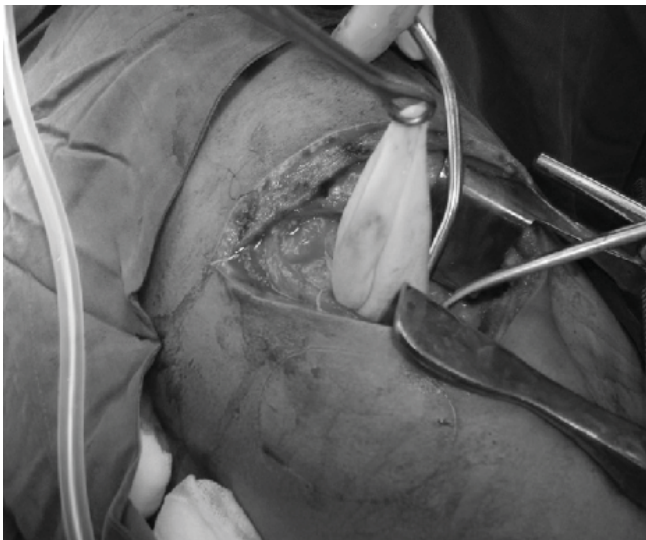

Figure 2. Operative view (resection of the laminating membrane of hydatid cyst of the posterior mediastinum)



Figure 3. daughter cysts and laminating membrane postoperative

duce the risk of perforation and dissemination.^{2,7} In our case, the cyst was ruptured during exploration. When there is a risk of dissemination, oral albendazole or mebendazole for 3–6 months can be prescribed (with assessment of hepatic function before initiating treatment).²

Hydatid cyst can occur in any part of the body and mediastinal regions are not exceptions. It is important to consider this as a differential diagnosis in the endemic region.

References

1. Aghajanzadeh M, Safarpour F, Amani H, Alavi A. One-stage procedure for lung and liver Hydatid cysts. *Asian Cardiovasc Thorac Ann.* 2008; **16**: 392–395.
2. Kabiri el H, al Aziz S, el Maslout A, Benosman A. Hydatid cyst: an unusual disease of the mediastinum. *Acta Chir Belg.* 2001; **101**: 283–286.
3. Aghajanzadeh M, Molaie R, Aghajanzadeh H, Marandi K. Hydatid cyst as a cause of Pancoast's syndrome. *Arch Iran Med.* 1999; **2**: Online Access.
4. Kabiri el H, Zidane A, Atoini F, Arsalane A, Bellamari H. Primary hydatid cyst of the posterior mediastinum. *Asian Cardiovasc Thorac Ann.* 2007; **15**: e60–e62.
5. Gurelik M, Goksel HM, Nadir A. Posterior mediastinal paravertebral hydatid cyst causing severe paraparesis. *Br J Neurosurg.* 2002; **16**: 605–606.
6. Dogan R, Yuksel M, Cetin G, Suzer K, Alp M, Kaya S, et al. Surgical treatment of hydatid cysts of the lung: report on 1055 patients. *Thorax.* 1989; **44**: 192–199.
7. Eroglu A, Kurkcuglu C, Karaoglanoglu N, Tekinbas C, Kaynar H, Onbas O. Primary hydatid cysts of the mediastinum. *Eur J Cardiothorac Surg.* 2002; **22**: 599–601.
8. Purohit M. Primary hydatid cysts of the mediastinum. *Eur J Cardiothorac Surg.* 2003; **23**: 257–258.
9. Das DK, Bhambhani S, Pant CS. Ultrasound guided fine-needle aspiration cytology: diagnosis of hydatid disease of the abdomen and thorax. *Diagn Cytopathol.* 1995; **12**: 173–176.