

Case Report

Plasmablastic Lymphoma versus Anaplastic Myeloma in a Human Immunodeficiency Virus Negative Male: A Diagnostic Quandary

Bhawna Bhutoria Jain MBBS MD¹, Anjana Majumdar BDS MDS², Kanika Mandi Chowdhary MBBS MD³

Abstract

We report a 45-year-old male presenting with an intraoral mass originating from the right maxillary alveolar ridge. Radiologic investigations revealed osteolytic lesions in the right maxilla, skull, and lumbar vertebrae. This finding led to further investigations like electrophoresis of serum proteins for M band, quantitative estimation of immunoglobulins, urine electrophoresis for monoclonal light chain, and bone marrow biopsy. All these findings were inconclusive. Incision biopsy revealed the features of plasmacytoma. Since the other reports were incongruent with the histopathology report, for establishing a diagnosis of plasmacytoma, Immunohistochemistry of the specimen was done which revealed it to be a case of plasmablastic plasma cell neoplasm favoring plasmablastic lymphoma. The diagnostic confusion which arose in this setting is discussed in details.

Keywords: Anaplastic myeloma, extramedullary plasmacytoma, plasmablastic lymphoma

Cite the article as: Jain BB, Majumdar A, Chowdhary KM. Plasmablastic Lymphoma versus Anaplastic Myeloma in a Human Immunodeficiency Virus Negative Male: A Diagnostic Quandary. *Arch Iran Med.* 2013; **16(10)**: 608 – 610.

Introduction

Plasmablastic lymphoma (PBL) is a recently identified entity that is considered to be a type of diffuse large cell B-cell lineage neoplasm with plasmablastic differentiation. It has a distinctive immunophenotype. It usually occurs in the oral cavity of patients who are seropositive for human immunodeficiency virus (HIV).¹ Its close resemblance to plasmablastic plasma cell myeloma leads to frequent misdiagnosis. Due to scarcity of reported cases of PBL, many aspects regarding the management still remain unresolved.

Anaplastic myeloma has been postulated to represent a distinct, aggressive variant of multiple myeloma, which may present at the onset or may result from transformation of a well-differentiated myeloma cell to poorly-differentiated one.² It may present with manifestations due to the extramedullary localization and has been reported occurring in the absence of an initial diagnosis of multiple myeloma.³ Multiple myeloma can develop in approximately 30% of solitary extramedullary plasmacytoma (EMP).³

Case Report

A 45-year-old Indian male presented with an exophytic growth on the right maxillary alveolar ridge (Figure 1). An orthopantomogram (OPG) radiograph revealed absence of the upper right premolars with destruction of the adjacent alveolar bone. Routine haemogram showed all values within normal limits. Histopathologic evaluation of the biopsy suggested it to be a case of EMP (Figure 2). In order to rule out multiple myeloma, further investi-

gations were carried out sequentially.

X-ray of skull, long bones, and vertebrae showed few punched out osteolytic lesions in the skull and lumbar vertebrae. Serum and urine protein electrophoresis did not exhibit any monoclonal light chain band. Quantitative estimations of IgG, IgA, and IgM were done, but all showed values within normal range. Beta-2 microglobulin estimation showed a higher value (2439.9 mcg/L).

Study of the bone marrow biopsy obtained from the iliac crest revealed a normocellular marrow.

Since the findings of an extramedullary plasma cell neoplasm with osteolytic lesions without M band were incongruent for any specific diagnosis, immunohistochemistry of the lesion was done from outside. The tumor cells were negative for CD3 and CD20, while they expressed Mum-1, LCA, CD 138, and CD 79a. Kappa restriction was present and the MIB labeling index (a cellular marker for proliferation) was 40%. The diagnosis offered in the immunohistochemistry report was PBL.

As this lesion occurs in HIV-affected individuals, a screening for HIV was carried out; however, the patient was found to be seronegative.

The patient underwent localized radiotherapy considering the diagnosis of EMP, but the response was poor. He suffered from declining health and refused any further tests. He died within one year of presentation.

Discussion

PBLs of the oral cavity were first described in 1997 as a subcategory of diffuse large B-cell lymphoma. The reported lymphomas were extranodal, with a predilection of oral cavity and showed a close association with HIV infection. These have characteristic morphologic and immunohistochemical features. They show weak or absent staining with CD20 and LCA while frequent staining with CD79a and plasma cell reactive antibody VS38c.¹

Minimum morphologic criteria required to diagnose PBL are: 1) predominant population of plasmablasts which are large mono-

Authors' affiliations: ¹Department of Pathology, Burdwan Medical College, West Bengal, India. ²Department of Oral Pathology, Burdwan Dental College, West Bengal, India. ³Department of Biochemistry, Burdwan Medical College, West Bengal, India.

Corresponding author and reprints: Name Bhawna Bhutoria Jain MBBS MD, 862, Block P, New Alipore, Kolkata -700053, India.

Tel: +91-943-308-9319, E-mail: bbhutoria@gmail.com.

Accepted for publication: 19 February 2013

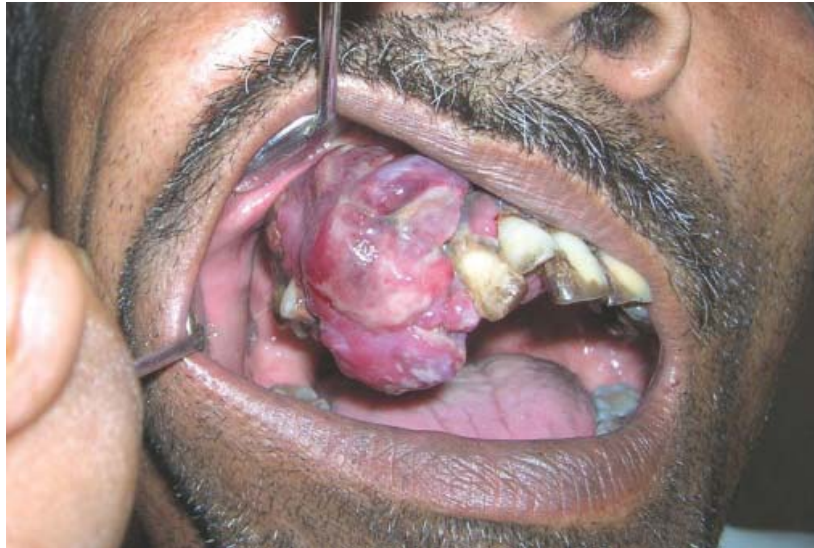

Figure 1. Clinical photograph shows an exophytic ulceroproliferative growth in the right maxillary alveolar ridge.

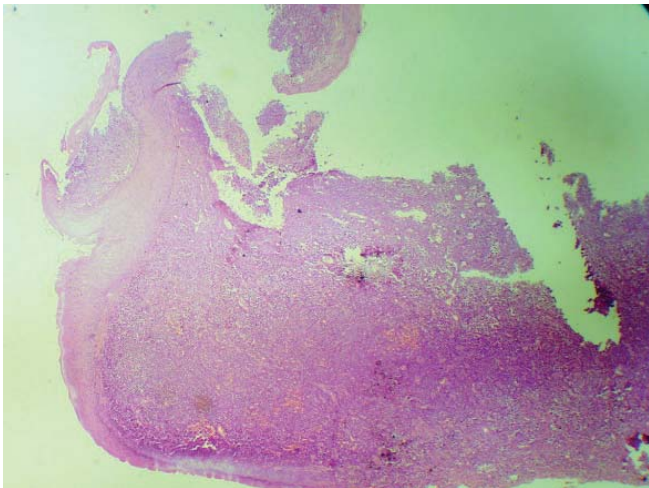


Figure 2a. A section from the tumor mass lined by keratinized stratified squamous epithelium. Lamina propria is completely filled with diffuse sheet of small round cells (HE, 40x).

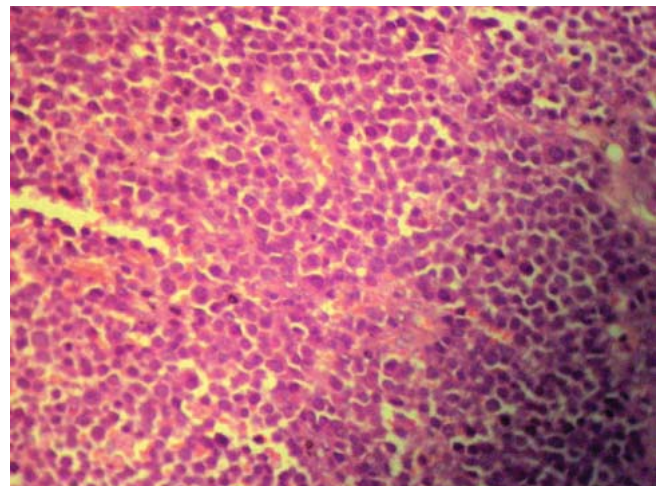


Figure 2b. Cells with varying maturation from mature plasma cells to undifferentiated cells (HE, 400x).

morphic cells with high nuclear-cytoplasmic ratio, and moderate amount of amphophilic cytoplasm and round nucleus with prominent central nucleolus, 2) high mitotic and/or apoptotic index, and 3) absence of neoplastic plasma cells in the background. Essential diagnostic immunophenotype consists of CD20 negativity, variable positivity of LCA, CD138/VS38c diffuse positivity, light chain restriction, and high MIB-1 labeling index (> 60%).⁵

Scheper, et al. described the first case of PBL occurring in an HIV-negative individual, reviewed the histopathologic and immunohistochemical phenotype of this lymphoma.⁶ Another study has described such a case in an immunocompetent HIV-negative male which was Epstein-Bar Virus and Human Herpes Virus 8-negative.⁷

EMP is defined as neoplastic proliferation of plasma cells in soft tissue and accounts for up to 3% of all plasma cell tumors. They arise more commonly in men, occurring in their sixth to eighth decades of life, and approximately, 90% are found in the head and neck region commonly affecting the nasal cavity, paranasal sinuses, tonsillar fossa, and oral cavity.⁸

PBLs may be confused with plasmacytoma with which they

share similar immune profile. Close attention to cellular details helps distinguish these related neoplasms, as PBLs are entirely composed of blasts with a light chromatin and one to a few prominent nucleoli but not containing proplasma cells and mature plasma cells with condensed chromatin and inconspicuous nucleoli, which is typical of plasmacytoma. In addition, extremely high proliferation index as well as numerous mitotic figures would be unusual features for a plasmacytoma.¹ The low MIB-1 proliferation index favors EMP compared to higher expression in PBL (more than 80%).

It has also been reported that PBL with light chain restrictions are considered as plasmablastic EMP.⁹

Radiotherapy is the mainstay of treatment for EMP as it is a radiosensitive tumor. The optimal radiation dose adopted is in the range of 40–60 Gy given over a period of four to six weeks.¹⁰

The present case presented with extramedullary plasma cell neoplasm and the histopathology showed a mixture of immature and mature plasma cells. With immunohistochemistry, it was negative for CD3 and CD20 and positive for Mum-1, LCA, CD 138, and CD 79a. Kappa restriction was present and the MIB labeling

index was 40%. The patient was HIV negative. It also showed punched out osteolytic lesions. Serum and urine protein electrophoresis did not exhibit any monoclonal light chain band. Quantitative estimations of IgG, IgA, and IgM were normal. Even bone marrow biopsy was unremarkable.

A case of anaplastic myeloma in an HIV-positive male was reported by Stewart, et al. Although the cytomorphologic and immunophenotypic findings of both PBL and anaplastic myeloma were overlapping, the pattern of bone involvement with punched-out lytic lesions and absence of localization of the tumor to the mucosa of the oral cavity led them to a diagnosis of anaplastic myeloma. Moreover, their patient was treated with antiretroviral therapy followed by thalidomide and pulse dexamethasone therapy, but the response was poor and he died within two months of presentation.¹¹

Our patient was treated with localized radiotherapy. He suffered from declining health. Unfortunately he refused further tests and died early in the course. Considering the above facts we propose it to be a case of anaplastic myeloma with initial extramedullary presentation in the oral cavity.

Conclusion

Extramedullary plasma cell neoplasm in the oral cavity can sometimes pose diagnostic difficulties and needs regular follow-up.

References

1. Delecluse HJ, Anagnostopoulos I, Dallenbach F, Hummel M, Marafioti T, Schneider U, et al. Plasmablastic lymphomas of the oral cavity: a new entity associated with the human immunodeficiency virus infection. *Blood*. 1997; **89**: 1413 – 1420.
2. Rao S, Kar R, Pati HP. Anaplastic myeloma: a morphologic diagnostic dilemma. *Indian J Hematol Blood Transfus*. 2008; **24**: 188 – 189.
3. Zervas K, Constantinou N, Karakantza M, Tsigalidou-Balla V. Anaplastic myeloma. *Leuk Lymphoma*. 1995; **16**: 515 – 518.
4. Liebross RH, Ha CS, Cox JD, Weber D, Delasalle K, Alexanian R. Clinical course of solitary extramedullary plasmacytoma. *Radiother Oncol*. 1999; **52**: 245 – 249.
5. Kane S, Khurana A, Parulkar G, Shet T, Prabhaskar K, Nair R, et al. Minimum diagnostic criteria for plasmablastic lymphoma of oral/sinonasal region encountered in a tertiary cancer hospital of a developing country. *J Oral Pathol Med*. 2009; **38**: 138 – 144.
6. Scheper MA, Nikitakis NG, Fernandes R, Gocke CD, Ord RA, Sauk JJ. Oral plasmablastic lymphoma in an HIV-negative patient: a case report and review of the literature. *Oral Surg Oral Med Oral Pathol Oral Radiol Endod*. 2005; **100**: 198 – 206.
7. Lee OJ, Kim KW, Lee GK. Epstein-Barr virus and human immunodeficiency virus-negative oral plasmablastic lymphoma. *J Oral Pathol Med*. 2006; **35**: 382 – 384.
8. Moshref M, Mashhadi-Abbass F, Sargolzaei S, Nafarzadeh S. Extramedullary plasmacytoma of gingiva. *Arch Iran Med*. 2007; **10**: 91 – 93.
9. Ponniah I, Rajan S. Plasmablastic extramedullary plasmacytoma. *Indian J Pathol Microbiol*. 2012; **55**: 104 – 106.
10. Alexiou C, Kau RJ, Dietzfelbinger H, Kremer M, Spiess JC, Arnold W. Extramedullary plasmacytoma: tumor occurrence and therapeutic concepts. *Cancer*. 1999; **85**: 2305 – 2314.
11. Stewart JMM, Krishnamurthy S. Fine-needle aspiration cytology of a case of HIV-associated anaplastic myeloma. *Diagn Cytopathol*. 2002; **27**: 218 – 222.