

## Case Report

## Cholethorax (Bilious Effusion in the Thorax): An Unusual Complication of Laparoscopic Cholecystectomy

Akin Aydogan MD<sup>1</sup>, Ersin Sukru Erden MD<sup>2</sup>, Seckin Akkucuk MD<sup>1</sup>, Ramazan Davran MD<sup>3</sup>, Ibrahim Yetim MD<sup>1</sup>, Orhan Veli Ozkan MD<sup>1</sup>

### Abstract

Cholethorax or bilious effusion in the thorax, is a rare condition in which bile passes into the pleural space from the abdominal cavity, necessitating urgent treatment. In this article, we present a case of cholethorax as a complication of laparoscopic cholecystectomy (LC). The patient underwent a LC due to the presence of a gallbladder polyp. The clip attached to the Hartman opened, and the abdominal cavity became contaminated with biliary fluid. Postoperatively, the patient experienced severe right upper quadrant pain and dyspnea. Both the posteroanterior (PA) chest radiography and thoracic computed tomography (CT) were remarkable for marked effusion in the right hemithorax. The patient underwent thoracentesis which resulted in the removal of 250 cc bilious pleural effusion. The bilirubin level of the pleural fluid was 9.1 mg/dL. Following thoracentesis, the patient experienced significant improvement in dyspnea and pain. The patient was discharged without any complications on the seventh day postoperatively. Cholethorax may occur as a result of diaphragmatic injuries secondary to a laparoscopic instrument and can be successfully treated by a thoracentesis.

**Keywords:** Cholethorax, complication, laparoscopic cholecystectomy, pleural effusion, thoracentesis

**Cite the article as:** Aydogan A, Sukru Erden E, Akkucuk S, Davran R, Yetim I, Veli Ozkan O. Cholethorax (Bilious Effusion in the Thorax): An Unusual Complication of Laparoscopic Cholecystectomy. *Arch Iran Med.* 2013; **16(8)**: 489 – 490.

### Introduction

Laparoscopic cholecystectomy (LC) is the gold standard for surgical treatment of gallbladder diseases due to its low morbidity and cost effectiveness. Other than the common complications of laparoscopy, additional complications include gallbladder perforation, clamping or injury of the common bile duct, injury to the right hepatic artery, injury to the vena porta or one of its branches, clamping or injury to the main hepatic biliary duct, and hemorrhage from the liver.<sup>1</sup>

Pleural effusion is a condition that emerges from accumulation of pleural fluid as a result of either pulmonary or extrapulmonary diseases. Postoperative pleural effusion is more frequent in patients who undergo hepatobiliary surgery. Bilious effusion in the thorax or cholethorax is extremely rare and not completely understood, despite the identification of several mechanisms for its pathophysiology.<sup>2</sup>

In this study, a case of bilious effusion in the thorax (cholethorax) with symptoms during the early postoperative period following LC was successfully treated with thoracentesis, respiration physiotherapy, proper analgesia, and antibiotics. This may be the first case of cholethorax following LC.

### Case Report

A 41-year-old male patient with dyspeptic complaints was ad-

mitted to our hospital. The abdominal physical examination revealed no pathologic findings other than right upper quadrant abdominal tenderness. The abdominal ultrasonography (US) was notable for multiple polyps in his gallbladder, of which the largest was 9 mm in diameter. An elective LC was scheduled for the patient whose laboratory tests such as complete blood count, liver function tests, and electrolyte levels were within normal limits. LC was performed according to American standards. During surgery, there was no pathology detected in the abdomen or diaphragm. During removal of the gallbladder from the abdomen, the clip attached to the Hartman opened and approximately 5 cc of bile leaked into the abdominal cavity. The clip was removed from the abdomen by jaws, after which the abdominal cavity was washed and aspirated with 500 cc saline. The operation finished without any additional complications. During the early postoperative period, oxygen support, nonsteroidal anti-inflammatory and narcotic analgesics were administered to the patient who developed dyspnea and severe right upper quadrant pain. The pain was more severe than usual. Complaints of dyspnea and pain continued. The patient had the following vital signs: body temperature (37°C), arterial tension pressure (120/80 mmHg), and pulse (90–100/min). Arterial blood gas examination revealed a pH of 7.46, PCO<sub>2</sub> of 39 mmHg, and PO<sub>2</sub> of 57 mmHg. Posteroanterior (PA) chest X-ray was remarkable for pleural effusion and diaphragmatic elevation (up to the fourth rib level of the right lung; Figure 1). A control abdominal US showed no pathology other than a minimally released effusion in the liver region. As seen in Figure 2, a right pleural effusion was detected on the thoracoabdominal computed tomography (CT). At postoperative day one, the patient's white blood cell count was 16,000/mm<sup>3</sup> and his liver and cholestatic enzymes were within normal limits. Under US-guided thoracentesis we removed 250 cc of bilious pleural effusion from the patient. After thoracentesis, the complaints of dyspnea and pain dramatically improved. Albumin, bilirubin, and lactate dehydrogenase levels were examined from the thoracente-

**Authors' affiliations:** <sup>1</sup>Mustafa Kemal University, Faculty of Medicine, Department of General Surgery, Hatay, Turkey. <sup>2</sup>Mustafa Kemal University, Faculty of Medicine, Department Chest Diseases, Hatay, Turkey. <sup>3</sup>Mustafa Kemal University, Faculty of Medicine, Department of Radiology, Hatay, Turkey.

**Corresponding author and reprints:** Seckin Akkucuk MD, Department of General Surgery, Mustafa Kemal University, Faculty of Medicine, Department of General Surgery, 31100 Hatay, Turkey. GSM: +90-533-6359714, Tel: +90-326-2291000, Fax: +90-326-2455654, E-mail: seckinakkucuk@gmail.com

Accepted for publication: 20 September 2012

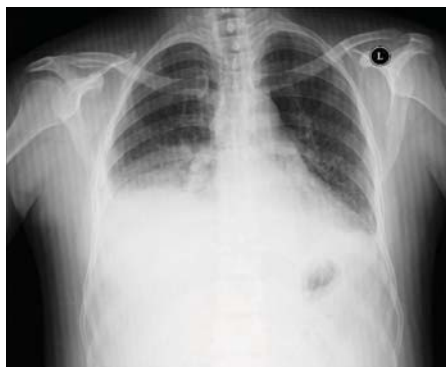

Figure 1. Pleural effusion in posteroanterior (PA) chest X-ray.

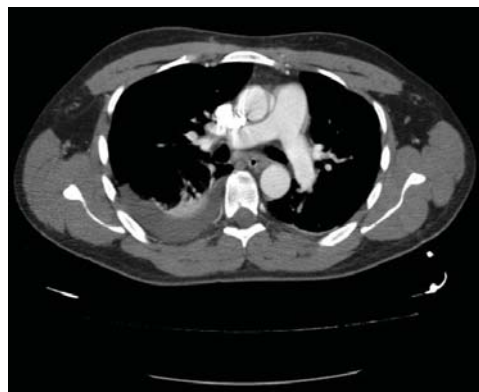


Figure 2. Right pleural effusion in thorax axial CT.

sis fluid, with a bilirubin level of 9.1 mg/dL. The patient received respiratory physiotherapy. Follow up abdominal US and PA chest films showed no evidence of fluid re-accumulation in the pleural space. The patient's complaints of pain and dyspnea completely resolved by the postoperative sixth day and he was discharged without any complaints on postoperative day seven.

## Discussion

Pleural effusion may occur in pulmonary or systemic diseases. In the United States, congestive heart failure, pneumonia and cancer are leading causes of pleural effusion. Other diseases which may cause pleural effusion are pulmonary embolism, coronary by-pass surgery, liver cirrhosis, viral diseases, diseases that affect intra-abdominal organs, and uremia. Rarely, upper abdominal surgery involving the liver, biliary tract, and spleen are responsible for a pleural effusion. Cholethorax, or the presence of a biliary component in pleural effusion, may occur during spontaneous perforation of the gallbladder,<sup>3</sup> open cholecystectomy,<sup>4</sup> percutaneous biliary drainage,<sup>5</sup> and biliary peritonitis caused by jejunal, gastric, or biliary injury.<sup>6</sup>

Non-biliary complications of LC are rare and possibly devastating. One non-biliary complication of LC is diaphragmatic injury due to complications from instrument usage during surgery. In a study by Singh et al., only 2 out of 1748 LC patients sustained diaphragmatic injuries.<sup>7</sup> Non-biliary complications may be difficult to observe if there is no suspicion of an injury. Transition of bile from the abdominal cavity into the pleural space may also occur either due to congenital diaphragmatic defects or through the aortic and esophageal hiatus.

There was no congenital defect in our case, however, a small perforation of the diaphragmatic peritoneum or diaphragm due to the instruments used during the operation might have been the cause for bile transition, with the effect of a negative pleural pressure. In the literature, there was no evidence of any bilio-pleural fistula in a cholethorax that occurred as a complication of LC.<sup>8,9</sup>

Thoracic pain, dyspnea, and pleural effusion increase in a cholethorax due to the chemo-irritating effect of bile in the pleura.<sup>2</sup> Bilirubin in a pleural effusion can be absorbed quickly, so early intervention is necessary to diagnose a cholethorax.<sup>2</sup> In early diagnosis, chest X-ray and thorax CT are the most valuable imaging techniques.

In our case, dyspnea and severe right upper quadrant pain began a few hours after surgery. There was no abdominal fluid collection during the early postoperative period. Pleural effusion was detected in PA chest radiography and thorax CT. There was bil-

ious effusion observed in the thoracentesis material. We considered that transition of negative intrathoracic-pressurized area into a high-pressure abdominal cavity caused this pleural effusion.

Pleural effusions that develop following upper abdominal surgery can resolve spontaneously without requiring specific treatment. However, as with the current case, thoracentesis should be performed for dyspnea and for the cholethorax that is the cause of pain.<sup>2</sup> In this case, a significant improvement occurred in symptoms after thoracentesis. We have suggested that closure of the injured portion of the diaphragm by the liver contributed to the recovery process.

As a result, cholethorax may occur depending on the diaphragmatic injury due to careless manipulation of instruments in LC. If small amounts of bile leak into the thorax from the abdominal cavity, the cholethorax can be successfully treated by a thoracentesis.

## Conflict of interest

Akin Aydoğan and the other co-authors have no conflicts of interest.

## References

1. Linhares BL, Magalhães AD, Cardoso PM, Linhares Filho JP, Pinho JE, Costa ML. Bile duct injury following cholecystectomy. *Rev Col Bras Cir.* 2011; **38**: 95 – 99.
2. Guillaumin J, Chanoit G, Decosne-Junot C, Goy-Thollot I. Biliothorax following cholecystectomy in a dog. *J Small Anim Pract.* 2006; **47**: 733 – 736.
3. Cunningham LW, Grobman M, Paz HL, Hanlon CA, Promisloff RA. Cholecystopleural fistula with cholelithiasis presenting as a right pleural effusion. *Chest.* 1990; **97**: 751 – 752.
4. Prabhu R, Bavare C, Purandare H, Supe A. Pleuro-biliary fistula--a delayed complication following open cholecystectomy. *Indian J Gastroenterol.* 2005; **24**: 28 – 29.
5. Strange E, Allen ML, Freedland PN, Cunningham J, Sahn SA. Pleural fistula as a complication of percutaneous biliary drainage: experimental evidence for pleural inflammation. *Am Rev Respir Dis.* 1988; **137**: 959 – 961.
6. Bini A, Grazia M, Petrella F, Stella F, Bazzocchi R. Spontaneous bilio-pneumothorax (thoracobilia) following gastropleural fistula due to stomach perforation by nasogastric tube. *Ann Thorac Surg.* 2004; **78**: 339 – 341.
7. Singh R, Kaushik R, Sharma R, Attri AK. Non-biliary mishaps during laparoscopic cholecystectomy. *Indian J Gastroenterol.* 2004; **23**: 47 – 49.
8. Brazinsky SA, Colt HG. Thoracoscopic diagnosis of pleurothorax after laparoscopic cholecystectomy. *Chest.* 1993; **104**: 1273 – 1274.
9. Lehur PA, Guiberteau-Canfrère V, Bury A, Cloarec D, Le Borgne J. "Cholethorax" revealing injury to the common bile duct after celioscopic cholecystectomy. *Ann Chir.* 1992; **46**: 450 – 452.