

Original Article

State's Pull-through for Total Colonic Aganglionosis and GI Dismotility

Ahmad Khaleghnejad Tabari MD¹, Hamid Foroutan MD², Abbas Banani MD², Leily Mohajerzadeh MD¹, Mohsen Ruozrokh MD¹, Alireza Mirshemirani MD¹

Abstract

Background: Total colonic aganglionosis (TCA) is present in 4% – 5% of the patients with Hirschsprung's disease and has a high surgical mortality rate between 13% – 23%. Diagnosis and treatment of TCA is still a major challenge for pediatric surgeons. Many techniques with several advantages and disadvantages were established for its treatment. We have performed State's pull-through as total colectomy and ileo-proctostomy with long posterior rectal myotomy in TCA and severe dysmotility disorders.

Methods: In this retrospective study, 13 patients with TCA were evaluated from 1992 through 2012 in two pediatric surgery centers, which consisted of 10 TCA, one intestinal neuronal dysplasia (IND), and two chronic intestinal pseudo-obstruction syndrome (CIP). All patients underwent total colectomy, resection of part of the involved small intestine, and rectal anastomosis in one layer with 4/0 vicryl with long posterior rectal myotomy. All patients had preoperative barium enema and rectal biopsy for diagnosis. Leveling ileostomy was performed in 12 patients and mid-jejunostomy in one patient. In two of 13 children, proximal diverting loop ileostomy was established after definitive operation. In three patients, trans-rectal myotomy was needed two weeks after the initial operation.

Results: All patients were females with the age ranging from six months to six years. State's pull-through was carried out for all (the mean age of definitive procedure was 5.1 months). Rectal biopsy of 10 patients reported no ganglion cells of which one had extended aganglionosis to mid-jejunum, one had IND, and two had ganglionic bowel with clinical presentation of CIP. The follow-up period was from six months to 10 years (the mean follow-up period was 10 months). There were no significant complications in 12 patients except episodes of diarrhea and severe dehydration which needed hospitalization. One patient with mid-jejunum aganglionosis had severe failure to thrive and needed repeated hospitalization for parenteral nutrition. All patients had acceptable bowel function following operation (two to six times a day). Now, five of the 13 patients are above the age of toilet training, having voluntary bowel movement with little or no medication (Leopromid).

Conclusion: State's pull-through is recommended in all cases of TCA and severe dysmotility problems of the colon. This technique is less difficult to perform, and avoids the complications and disadvantages of removal of the rectum and has satisfactory results.

Keywords: Hirschsprung's disease, state's pull-through, total colonic aganglionosis

Cite this article as: Khaleghnejad Tabari A, Foroutan H, Banani A, Mohajerzadeh L, Ruozrokh M, Mirshemirani AR. State's pull-through for total colonic aganglionosis and GI dysmotility. *Arch Iran Med.* 2013; **16**(5): 277 – 280.

Introduction

Total colonic aganglionosis (TCA) is an unusual form of Hirschsprung's disease with clinical, histologic, and genetic differences and is even extra complex to identify and handle.¹

The incidence of TCA is one in every 500,000 live births, and is present in 4% – 5% of the patients with Hirschsprung's disease.² The mortality rate for this group of patients is reported to be 23% – 65% in different studies.³ Patients with extended small intestinal disease have farthest morbidity. All these children require long-term parenteral nutrition support, and the mortality rate is exceptionally high (in some reports 50%). Various operations have been established for treatment of TCA. There is no current agreement on a superior operative procedure.⁴ Longer length of retained colon adversely affects these children's ability to defecate and increases

the incidence of postoperative enterocolitis.⁵ The aim of this study was to evaluate the results of State's pull-through (resection of all aganglionic bowel and ileo-proctostomy with long posterior rectal myotomy in TCA and severe dysmotility disorders).

Patients and Methods

In this retrospective study, we evaluated 13 female patients with TCA within 20 years (December 1992 through March 2012) in Mofid Children's Hospital and Mother and Child Hospital, which consisted of 10 TCA, one intestinal neuronal dysplasia (IND), and two chronic intestinal pseudo-obstruction syndrome (CIP). All patients underwent total colectomy, resection of part of the involved small intestine, and rectal anastomosis in one layer with 4/0 vicryl with long posterior rectal myotomy. All patients had preoperative barium enema and rectal biopsy for diagnosis. Leveling ileostomy was performed in 12 patients and mid-jejunostomy was done in one. In two of the 13 children, proximal diverting loop ileostomy was established after definitive operation. In three patients, trans-rectal myotomy was needed two weeks after the initial operation. Clinical data including age at operation, sex, associated congenital anomalies, symptoms at presentation, diag-

Authors' affiliations: ¹Pediatric Surgery Research Center, Shahid Beheshti University of Medical Sciences, Tehran, Iran. ²Department of Pediatric Surgery, Mother and Child Hospital, Shiraz University of Medical Sciences, Shiraz, Iran. **Corresponding author and reprints:** Ahmad Khaleghnejad Tabari MD, Pediatric Surgery Research Center, Shahid Beheshti University of Medical Sciences, Tehran, Iran. Telfax: +982122908181, E-mail: khalegh@ams.ac.ir

Accepted for publication: 28 December 2012

nostic modalities, and operative details were collected. Early and late functional results (including growth and development, stool frequency, fecal soiling or incontinence, and enterocolitis) were evaluated during follow-up.

Results

Thirteen female patients with the age ranging from six months to six years (the mean age of definitive procedure was 5.1 months) underwent State's pull-through (Figure 1) due to TCA. Nine patients presented as neonatal intestinal obstruction with delayed passage of meconium after birth who underwent laparotomy and multiple biopsies and ileostomy, of whom one had IND. Two patients with TCA were diagnosed after one year with severe constipation and abdominal distension and several episodes of intestinal obstruction. In 10 patients, rectal biopsy reported no ganglion cells of which one had extended aganglionosis to the distal jejunum and one had IND. Two patients with clinical presentation of CIP, who have had several negative laparotomies, had ganglionic bowel in rectal biopsy but with myopathy.

The follow-up period was from six months to 10 years. There were no significant complications in 12 patients except episodes of diarrhea and severe dehydration which needed hospitalization. One patient with mid-jejunal aganglionosis had severe failure to thrive and needed repeated hospitalization for parenteral nutrition. There was no mortality in our patients. All had acceptable bowel function following the operation (two to six times a day). In the recent follow-up, five of the 13 patients were above the age of toilet training, and had voluntary bowel movement with little or no medication (Leopromid).

Discussion

TCA is a difficult form of Hirschsprung's disease because of the increase in morbidity and mortality. TCA can be very difficult to diagnose. The diagnosis is generally made at the time of laparotomy for intestinal obstruction or perforation or while a leveling

colostomy for Hirschsprung's disease is being established.^{6,7} The proximal level of aganglionosis is the terminal ileum in 75% of cases, the mid-ileum in 20%, and the jejunum in 5%.⁸ Several surgical techniques have been planned for TCA (Figure 2). In 1953 Sandegard was reported the first operation for total colonic disease.⁹ The modification of the Duhamel pull-through technique by Martin, which included a longer portion of remnant aganglionic rectum and left colon to assist the absorption of electrolytes and water.¹⁰ Marquez, et al. reported procto-colectomy with a J-pouch ileo-anal anastomosis and laparoscopic pull-through procedure with fine practical consequences and less postoperative complications, but they had a short-term follow-up.⁴ Kottmeier, et al. in 1981 reported a technique in which he used a side to side anastomosis between aganglionic terminal ileum to upper ganglionic ileum as a pouch for better absorptive property of aganglionic ileum.¹¹ Seiichi, et al. in 1987 and Kimura, et al. in 1981 compared Martin extended Duhamel procedure with segmental colon patch in TCA, and believed that preserving of colon patch is much better than entire aganglionic colon.^{12,13} In 1989 Bergmeijer, et al. reported Rehbein procedure in six patients with TCA, which results were acceptable by total colectomy and ileo-rectal anastomosis. In their follow-up, the patients had diarrhea in short time that resolved one year after surgery and they advocated this procedure for treatment of TCA.¹⁴ Heinen, et al. in 2004 performed laparoscopic colectomy in TCA. Laparoscopic dissection of the retrorectal space had satisfactory results.¹⁵ Basnet and Shan in 2006 published papers in PUBMED and MEDLINE about TCA. They found improvement in diagnosis, treatment, and survival of these patients in recent years.¹⁶ Hashish, et al. reviewed 24 patients with TCA from 1998 through 2009. All patients underwent straight endorectal pull-through, in which risk of recurrent enterocolitis and significant perianal excoriation were high and six patients still suffer from different degrees of soiling.¹⁷ But in our study, there was no such complications. In newer investigations in 2009, Bischoff, et al. analyzed 27 patients with TCA, and reported that a direct ileo-rectal anastomosis is more suitable than any form of pouch or patches such as Martin, Duhamel, or Kimura procedures.¹⁸ In our

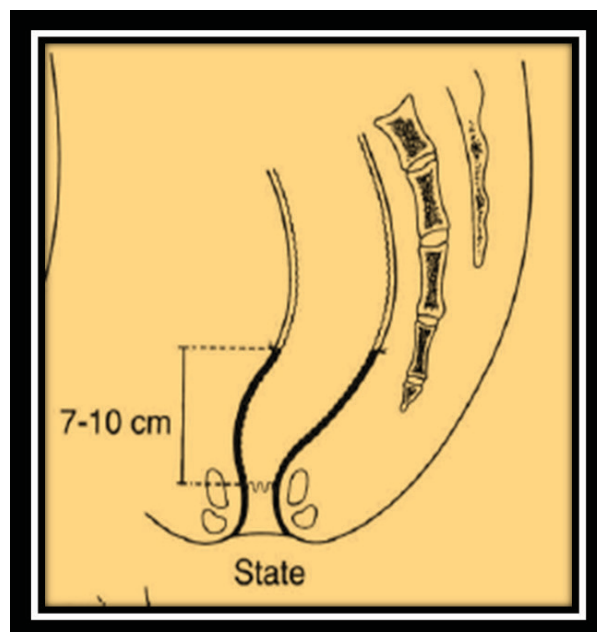


Figure 1. State's pull-through procedure.

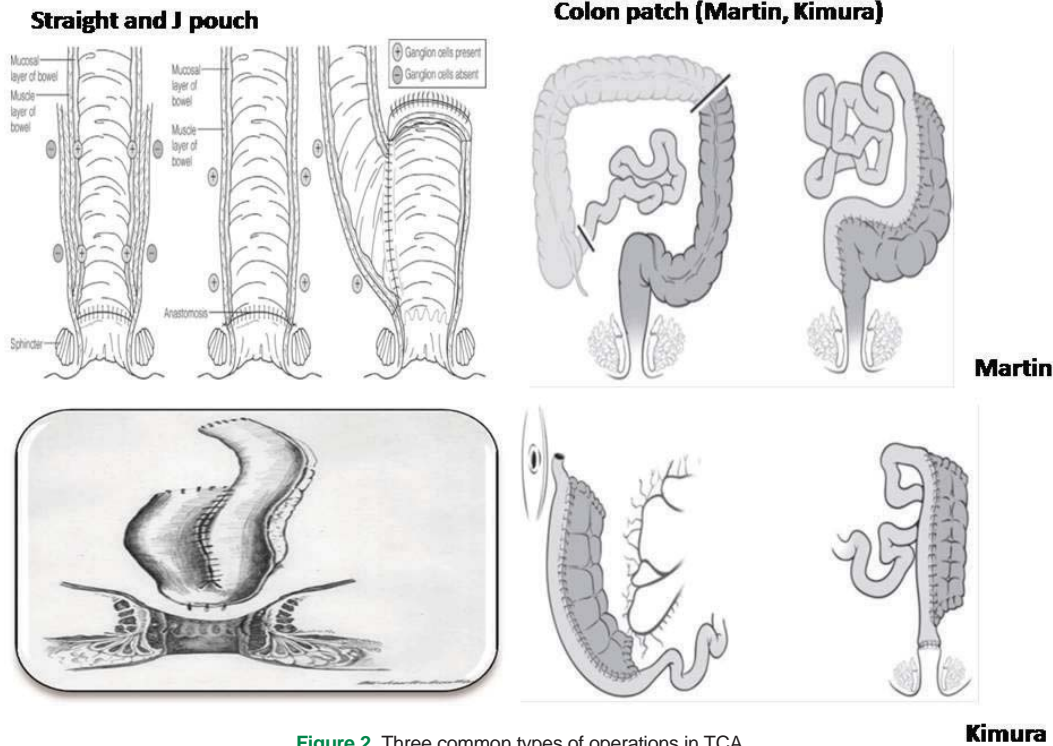


Figure 2. Three common types of operations in TCA.

study, the patients had good outcomes. The overall mortality after treatment of TCA was zero; however, it should be noted that this mortality rate encompasses only those who survived to receive a definitive operation. The overall mortality for TCA has been as high as 53% and has been improved by appropriate and early diagnosis of TCA and preoperative management of nutrition, fluids, and electrolytes.¹⁹ Enterocolitis is a well-known complication in TCA and its reported rate is from 22% to 75%.^{19,20} The length of the retained aganglionic colon has been correlated with higher rates of enterocolitis; however, this was not observed in the series reviewed by Escobar, et al.²¹⁻²⁶ In our study, only one patient had several episodes of enterocolitis that needed admission.

The average number of bowel movements usually improves with time. It was also observed in our study; it was noticed that the patients had gradual improvement in their bowel movements over time. These patients have loose stools for about one to two years after surgery, after which the stool consistency returns to near normal. Escobar, et al. found that 81% of the patients with TCA were continent at long follow-up.²⁰ No operative technique for the treatment of TCA was found to be superior with respect to preoperative outcomes. All procedures were comparable with respect to mortality, morbidity, rate of enterocolitis, and functional outcome. Significant improvement has been made in the overall mortality of TCA, whereas the morbidity is still high. Operative approach to TCA should be based on the surgeon's familiarity and expertise and the overall center's experience.

Based on our experience, State's pull-through is recommended in all patients with TCA and severe dysmotility problems of the colon. This technique does not need to stapler and can be performed easily and very rapidly, and avoids the complications and disadvantages of removal of the rectum and has satisfactory results.

Acknowledgment

This study was financially supported by the Office of the Vice Chancellor for Mofid Children's Hospital Clinical Research Development Center.

References

1. Kapur RP. Practical pathology and genetics of Hirschsprung's disease. *Semin Pediatr Surg.* 2009; **18**(4): 212 – 223.
2. Dykes E, Guiney E. Total colonic aganglionosis. *J Pediatr Gastroen Nutr.* 1989; **8**: 129 – 132.
3. Coran AG, Bjordal R, Eck S, Kunrud O. The surgical management of total colonic and partial small intestine aganglionosis. *J Pediatr Surg.* 1969; **4**: 531.
4. Marquez TT, Acton RD, Hess DJ, Duval S, Saltzman DA. Comprehensive review of procedures for total colonic aganglionosis. *J Pediatr Surg.* 2009; **44**: 257 – 265.
5. Hoehner C, Ein SH, Shandling B, Kim PC. Long-term morbidity in total colonic aganglionosis. *J Pediatr Surg.* 1998; **33**: 961 – 965.
6. Wildhaber B, Coran A, Teitelbaum O. Total colonic Hirschsprung's disease: A 28-year experience. *J Pediatr Surg.* 2005; **40**: 203 – 206.
7. Mirshemirani A, Sadeghian S, Kouranloo J. Long-segment aganglionosis: A 15-year experience. *Acta Medica Iranica.* 2009; **47**(1): 71 – 74.
8. Asonni V, Martucciello G. Total colonic aganglionosis. *Semin Pediatr Surg.* 1998; **7**: 174 – 180.
9. Sandegard E. Hirschsprung's disease with ganglion cell aplasia of the colon and terminal ileum: Report of a case treated with total colectomy and ileo-anostomosis. *Acta Chir Scand.* 1953; **106**: 367 – 376.
10. Martin L. Surgical management of Hirschsprung's disease involving the small intestine. *Arch Surg.* 1968; **97**: 183 – 189.
11. Kottmeier PK, Jongco B, Velcek FT, Friedman A, Klotz DH. Absorptive Function of the Aganglionic Ileum. Presented before the 29th annual meeting of the surgical section of the American Academy of Pediatrics, Detroit, Michigan. 1980; 27 – 28.
12. Seiichi G, Grosfeld JL. Is preserving the entire aganglionic colon rea-

- sonable in the surgical treatment of total colonic aganglionosis? *J Pediatr Surg.* 1987; **22(7)**: 623 – 627.
13. Kimura K, Nishijima E, Muraji T, Tsugawa C, Matsumoto YA. New surgical approach to extensive aganglionosis. *J Pediatr Surg.* 1981; **16(6)**: 840 – 843.
 14. Bergmeijer J, Tibboel D, Molenaar J. Total colectomy and ileo-rectal anastomosis in the treatment of total colonic aganglionosis: A long-term follow-up study of six patients. *J Pediatr Surg.* 1989; **24(3)**: 282 – 285.
 15. Heinen DF, Elmo G, Vallone P, Bailez M. Aganglionosis total del colon, Tactica Video-laparoscopica Rev decir. *Infantil.* 2004; **14(1)**: 42 – 47.
 16. Basnet A, Shan Z, Xianmin X. Ten-year experience in the management of Total colonic aganglionosis. *Journal of Pediatric Surgery.* 2007; **42**: 1671 – 1676.
 17. Hashish A, Fayad H, El-Asharf el-attar A, Metwally MF, AbdElmotelb E, Elhalaby E, et al. Total colonic aganglionosis: Out come at both short- and long- term follow- up. *Annals of Pediatric Surgery.* 2009; **5(3)**: 154 – 160.
 18. Bischoff A, Levitt MA, Penea A. Total colonic aganglionosis: A surgical challenge; how to avoid complications? *Pediatr Surg Int.* 2011; **27(10)**: 1047 – 1052.
 19. Wildhaber B, Teitelbaum D, Coran A. Total colonic Hirschsprung's disease: A 28-year experience. *J Pediatr Surg.* 2005; **40**: 203 – 207.
 20. Khaleghnejad Tabari A, Moslemi-Kebria M. The Results of two-stage surgical management of Hirschsprung's disease in A 10-year period. *Arch Iran Med.* 2001; **4(2)**: 84 – 87.
 21. Escobar MA, Grosfeld JL, West KW, Scherer LR, Rouse TM, Engum SA, et al. Long-term outcomes in total colonic aganglionosis: A 32- year experience. *J Pediatr Surg.* 2005; **40**: 955 – 961.
 22. Miyano G, Ochi T, Lane GJ, Okzaki T, Yamatoka A. Factors affected by surgical technique when treating total colonic aganglionosis: laparoscopy assisted versus open surgery. *Pediatr Surg Int.* 2013; **29(4)**: 349 – 352.
 23. Kella N, Talpura, Sangrasi AK, Leghari F, Rathi PK. Intestinal aganglionosis in Shah-Waardenburgsyndrome; Analysis of 12 cases. *Medical Channel.* 2011; **17(4)**: 45 – 48.
 24. Castle S, Suliman A, Shayan K, Kling K, Bicler S, Losasso B. Total colonic aganglionosis with skip lesions: report of a case and management. *J Pediatr Surg.* 2012; **47(3)**: 581 – 584.
 25. Choe EK, Moon SB, Kim Y, Lee SC, Park KW, Jung SE. Outcomes of surgical management of total colonic aganglionosis. *World Journal of Surgery.* 2008; **32(1)**: 62 – 68.
 26. Ardelean MA, Bauer J, Schemke C, Schnoll J, Heil C, Ludwikowski L. Long segment aganglionosis; treatment and results. *Journal of Pediatric Surgical Specialties.* 2010; **4(1)**: 166.