

Photoclinic

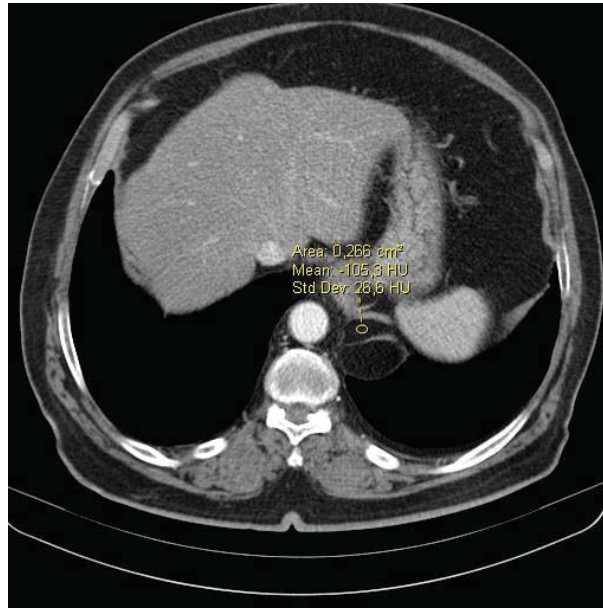


Figure 1. Left diaphragmatic crura showed a smooth, rounded small hypodense mass that measured approximately -105 HU, which was consistent with adipose tissue.

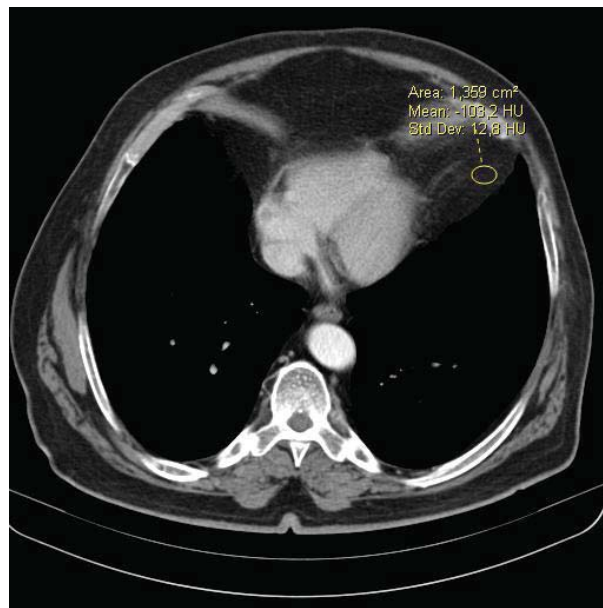


Figure 2. Enormous pericardial fat pad area that measured approximately -103 HU which was consistent with adipose tissue.

Cite the article as: Keskin Z, Keskin S, Yeşildağ M, Yeşildağ A. Photoclinic. *Arch Iran Med.* 2013; **16(4)**: 249 – 250.

A 72-year-old male presented to our outpatient clinic with a history of long term dyspnea. During a high resolution thoracic computed tomography (CT) scan, the left diaphragmatic crura showed

Zeynep Keskin MD¹, Suat Keskin MD², Mihrican Yeşildağ MD³, Ahmet Yeşildağ MD²

Authors' affiliations: ¹Department of Radiology, Konya Training and Research Hospital, Konya, Turkey. ²Department of Radiology, Necmettin Erbakan University, Meram School of Medicine, Konya, Turkey. ³Department of Chest, Konya Training and Research Hospital, Konya, Turkey.

Corresponding author and reprints: Suat Keskin MD, Necmettin Erbakan University, Meram School of Medicine, Radiology Department, Konya, Turkey. P.O. Box: 42080; Telefax: +90-332-2236181, E-mail: drsuatkeskin@yahoo.com
Accepted for publication: 8 September 2012

a smooth, rounded small hypodense mass and an enormous pericardial mass. The diameter of the hypodense mass was 41 mm; the pericardial mass diameter was approximately 192 mm. Both had similar densities that measured approximately -105 HU, which was consistent with adipose tissue. Scans above and below this region showed that the diaphragmatic crura had a normal thickness, shape and density. Laboratory tests were normal. The patient did not consent to surgery.

**What is your diagnosis?
See the next page for diagnosis.**

Photoclinic Diagnosis:

Primary Lipoma of the Diaphragm and Enormous Pericardial Fat Pad Presenting with Long-term Dyspnea

Photoclinic Diagnosis: Lipomas are common, however they are rarely located in the diaphragm.¹ Primary diaphragmatic lipomas are usually incidental findings.² Diaphragmatic lipomas are encapsulated, soft fatty tumors frequently occurring in obese patients. They are equally common in men and women, reported twice as often on the left side, and are primarily in a posterolateral location.^{2,3} On occasion, they may be bilateral.⁴ Diaphragmatic crus lipomas are sometimes mistaken for Bochdalek hernias.^{1,4-6} Most of Bochdalek hernias are round-oval masses located in the posteromedial aspect of the hemidiaphragm and they also contain fat, so they may erroneously be interpreted as diaphragmatic lipoma. Because the diaphragmatic muscle is interrupted in a hernia, it is intact in a lipoma.⁷ The continuity of the diaphragm caudally also differentiates a lipoma from retroperitoneal adipose tissue. Pericardial fat deposition is common in multiple conditions. Although it can be found in any location, however it is most common over the anterior portion of the heart.⁸ Excessive fat accumulation is most common in older, obese, diabetic patients, usually women, and may be observed in patients with exogenous or endogenous steroid excess.⁹

References

1. Ferguson DD, Westcott JL. Lipoma of the diaphragm; report of a case. *Radiology*. 1976; **118**: 527 – 528.
2. Wiener MF, Chou WH. Primary tumors of the diaphragm. *Arch Surg*. 1965; **90**: 143 – 152.
3. Dalquen P. Lipoma of the diaphragm: Malformation or hernia? *Thoraxchir Vask Chir*. 1972; **20**: 112 – 115.
4. Tihansky DP, Lopez GM. Bilateral lipomas of the diaphragm. *NY State J Med*. 1988; **88**: 151 – 152.
5. Oyar O, Kayahoglu G, Cagirci U. Diaphragmatic crus lipoma: a case report. *Comput Med Imag and Graphics*. 1998; **22**: 421 – 423.
6. Castillo M, Shirkhoda A. Computed tomography of the diaphragmatic lipoma. *J Comput Tomogr*. 1985; **9**: 167 – 170.
7. Shin MS, Mulian SA, Baxley WA, Ho KJ. Bochdalek hernia of diaphragm in the adult. Diagnosis by computed tomography. *Chest*. 1987; **92**: 1098 – 1101.
8. Pressman G, Verma N. Pericardial fat masquerading as tumor. *Echocardiography*. 2010; **27**: 18 – 20.
9. Sanfillippo AJ, Weyman AE. Pericardial disease. In: Weyman AE, ed. *Principles and Practice of Echocardiography*. Pennsylvania: Lea and Febiger; 1994: 1102 – 1134.



A sunrise view in Taleqan - Alborz Province - Iran. (photo by M.H.Azizi MD)