

## Case Report

# Bilateral Congenital Absence of the Abductor Pollicis Brevis Muscle: A Case Report

Ali Aydin MD<sup>1</sup>, Murat Topal MD<sup>1</sup>, Kutsi Tuncer MD<sup>1</sup>, Mesut Kilic MD<sup>1</sup>

## Abstract

Congenital absence of the abductor pollicis brevis is a very rare condition and is usually associated with other congenital anomalies. Here we report a case of bilateral congenital absence of the abductor pollicis brevis without any other abnormalities, which has not been previously reported. A 24-year-old Caucasian male patient presented to our clinic with flattening in the palmar region, pain and discomfort in writing, and weakness in both hands. USG and MRI revealed bilateral absence of the abductor pollicis brevis muscle. Bilateral congenital absence of the abductor pollicis brevis muscle requires no treatment due to satisfactory hand function, and results in cosmetic problems. Congenital absence of the abductor pollicis brevis muscle should be kept in mind in patients with flattening of the thenar eminences.

**Keywords:** Absence of abductor pollicis brevis muscle, congenital anomalies of thumb

**Cite this article as:** Aydin A, Topal M, Tuncer K, Kilic M. Bilateral congenital absence of the abductor pollicis brevis muscle: A case report. *Arch Iran Med.* 2013; **16(1)**: 56 – 58.

## Introduction

Although congenital absence of thenar muscles and tendons of the thumb has been reported previously,<sup>1</sup> congenital absence of the abductor pollicis brevis has not been published yet. Thenar muscle anomalies and thumb hypoplasia distorting hand functions, are complex congenital anomalies and are often seen in connection with other syndromes or congenital anomalies.<sup>2-4</sup> We present a rare case of absence of the abductor pollicis brevis with an intact functioning abductor pollicis longus.

## Case Report

A 24-year-old Caucasian male patient presented to our clinic with flattening in the palmar region, pain, and discomfort in writing. He reported no trauma and there were no relatives with musculoskeletal abnormalities, diseases, or with hereditary syndromes. On physical examination, there were flattening of the thenar eminences in both hands and atrophy in both thumbs. There were no contractures in first web regions. Range of motions was normal at the wrists and there were mild limitation of abduction of the thumbs. Opposition in the left hand was limited whereas opposition in the right hand was weak (Figure 1. a, b, c, d, e). Pinch grip strengths of both hands were weak. Movements of the metacarpophalangeal, carpometacarpal, and interphalangeal joints were normal. Neurologic examination of the left upper extremity was unremarkable. Other systemic physical examinations were normal. Direct X-ray graphics of both wrists were evaluated normal (Figure 2). Ultrasonography (USG) revealed bilateral absence of the abductor pollicis brevis muscle. Flexor pollicis longus, abductor pollicis longus, extensor pollicis longus, extensor

pollicis brevis, adductor pollicis, flexor pollicis brevis, and opponens pollicis were determined as active by electromyography. There was no electromyographic activity of the abductor pollicis brevis. Activity of median, ulnar, and radial nerves were normal. Magnetic resonance imaging (MRI) confirmed the absence of the abductor pollicis brevis muscle (Figure 3. a, b, c, d).

## Discussion

The primary function of the abductor pollicis brevis muscle, which is located in the radial part of the thenar region, is abduction and opposition of the thumb, as well as taking role in the fine movements of the hand. The congenital absence of the abductor pollicis brevis is a very rare disorder. Thumb hypoplasia and thenar muscle anomalies are seen in connection with other syndromes or congenital anomalies.<sup>1</sup> Muscle and bone abnormalities of the upper extremity has a ratio of 3:2 (male:female) between gender and an incidence of 1/100000. The anomalies of the thenar muscles and hypoplasia of the thumb are seen in several diseases and syndromes such as Fanconi, TAR (thrombocytopenia and absent radius), VACTERL (vertebra, anal, cardiovascular, tracheo-esophageal, renal, and limb defects), and Holt-Oram. The most common skeletal anomalies are the abnormalities of the radius.<sup>2,3</sup> Iyer et al. reported congenital absence of the abductor pollicis brevis and flexor pollicis brevis muscles with laxity of ulnar and radial collateral ligaments of the metacarpophalangeal joints.<sup>1</sup> Our patient was a sporadic case without any other syndromes or diseases.

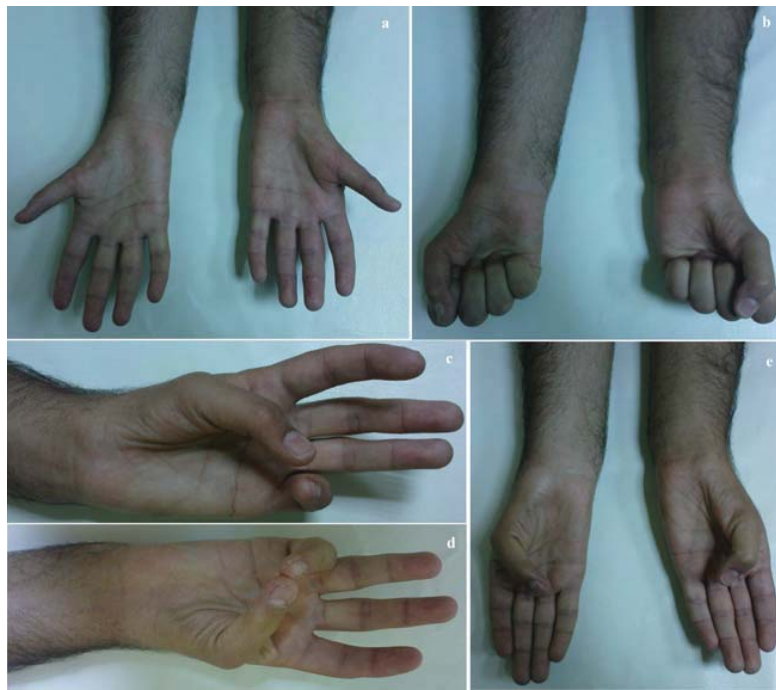Congenital abnormalities of the thenar muscles accompanying nerve abnormality and other syndromes have been reported previously such as absence of the abductor pollicis brevis muscle accompanying with the absences of the opponens pollicis muscle and the motor branch of the median nerve.<sup>4</sup> There were no neurologic or muscular abnormalities in our case.

The thumb is the strongest and most functional finger, making it the most important part of the hand.<sup>5</sup> Therefore, congenital anomalies of the thumb pose more serious functional and cosmetic

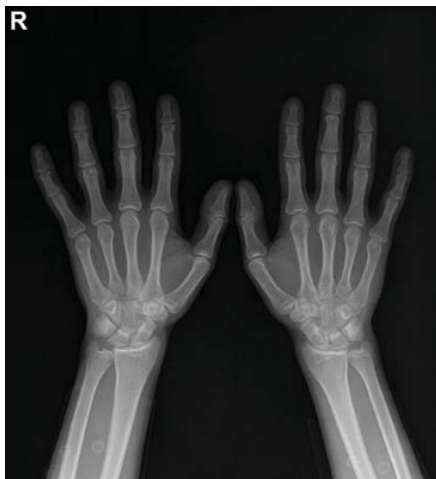**Authors' affiliations:** <sup>1</sup>Department of Orthopedics and Traumatology, Medical School Hospital, Atatürk University.

**•Corresponding author and reprints:** Ali Aydin MD, Department of Orthopedics and Traumatology, Medical School Hospital, Atatürk University, 25240, Erzurum, Turkey. Tel: +90 442 3166333, Fax: +90 442 2361301, E-mail: dr.aliaydin@hotmail.com.

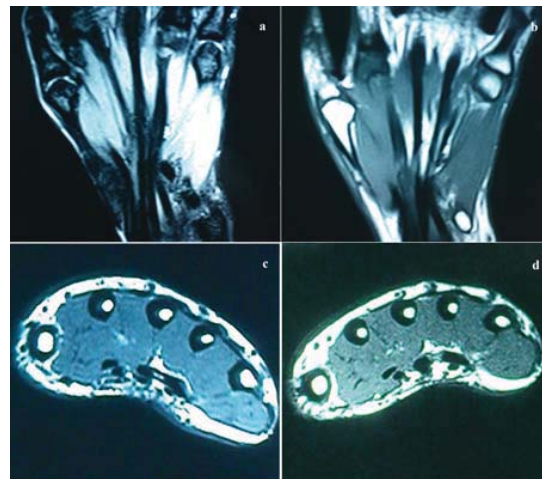
Accepted for publication: 16 May 2012



**Figure 1.** a) Atrophy in both thumbs and bilateral flattening of the thenar eminences, b) Atrophy in both thumbs and bilateral flattening of the thenar eminences c) Opposition deficit in the left hand, d) Opposition in the right hand, e) Abduction deficit in both thumbs.



**Figure 2.** X-ray (AP) graphies of both of the wrists.



**Figure 3.** a) MRI showing the absence of the abductor pollicis brevis in the left hand, b) MRI showing the absence of the abductor pollicis brevis in the right hand, c) MRI showing the absence of the abductor pollicis brevis in the left hand, d) MRI showing the absence of the abductor pollicis brevis in the right hand.

problems than anomalies of the other fingers.<sup>6,7</sup> In our case, as the absence of the abductor pollicis brevis muscle did not result in significant loss of hand functioning, the patient only had cosmetic complaints due to the flattening of the thenar eminence.

As patients are usually earlier diagnosed by parents due to inability to flex the interphalangeal joint of the thumb at the childhood, most of the case reports are in children.<sup>7</sup> Rarely, patients are late diagnosed.<sup>8</sup> In our patient, diagnosis was late because the patient had been satisfied with functioning of his hands other than cosmetic problems until the diagnosis.

In case of congenital absence of tendons of the thumb, especially

in absence of the flexor pollicis longus muscle, tendon transfers have been successfully used.<sup>6-10</sup> In the previously reported cases of congenital absence of the abductor pollicis brevis, none of the patients underwent surgery.<sup>1</sup> Eventually, we did not offer any treatment to our patient as he was satisfied with functioning of his hands other than minor cosmetic problems.

In this report, we present a unique case of bilateral congenital absence of the abductor pollicis brevis muscle without other anomalies. The patient was diagnosed at the age of 24 which can be assumed as late, as he did not have significant symptoms other than cosmetic problems. Bilateral congenital absence of the abductor

pollicis brevis muscle is a rare condition, requiring no treatment due to satisfactory hand function; it causes cosmetic problems. Congenital absence of the abductor pollicis brevis muscle should be kept in mind in patients with flattening of the thenar eminences.

## References

1. Iyer KM, Stanley JK. Congenital absence of flexor pollicis brevis and abductor pollicis brevis. *Hand*. 1982; **14**: 313 – 316.
2. James MA, McCarroll HR Jr, Manske PR. Characteristics of patients with hypoplastic thumbs. *J Hand Surg Am*. 1996; **21**: 104 – 113.
3. James MA, Green HD, McCarroll HR Jr, Manske PR. The association of radial deficiency with thumb hypoplasia. *J Bone Joint Surg Am*. 2004; **86**: 2196 – 2205.
4. Dellon AL, Rayan G. Congenital absence of the thenar muscles. Report of two cases. *J Bone Joint Surg Am*. 1981; **63**: 1014 – 1015.
5. Kozin SH. Deformities of the thumb. In: Gren DP, editor. *Green's operative hand surgery*. 5<sup>th</sup> eds. Philadelphia: Elsevier Churchill- Livingstone. 2005; **2**: 1445 – 1468.
6. Demirseren ME, Afandiyev K, Durgun M, Kilicarslan K, Yorubulut M. Congenital absence of flexor pollicis longus tendon without associated anomalies of thumb hypoplasia: a case report and review of the literature. *Hand*. 2007; **2**: 184 – 187.
7. Thomas C, Mathivanan T. Congenital absence of flexor pollicis longus without hypoplasia of the thenar muscles. *J Hand Surg Br*. 1999; **24**: 385 – 386.
8. Lutes WB, Tamurian R. Bilateral congenital absence of the flexor pollicis longus. *Orthopedics*. 2007; **30**: 318 – 319.
9. DeHaan MR, Wong LB, Petersen DP. Congenital anomaly of the thumb: aplasia of the flexor pollicis longus. *J Hand Surg Am*. 1987; **12**: 108 – 109.
10. Miura T. Congenital absence of the flexor pollicis longus: a case report. *Hand*. 1977; **9**: 272 – 274.