

Original Article

Potential Protective Effect of Honey Against Paracetamol-induced Hepatotoxicity

Reem M Galal MSc¹, Hala F Zaki PhD¹, Mona M Seif El-Nasr PhD¹, Azza M Agha PhD¹

Abstract

Background: Paracetamol overdose causes severe hepatotoxicity that leads to liver failure in both humans and experimental animals. The present study investigates the protective effect of honey against paracetamol-induced hepatotoxicity in Wistar albino rats. We have used silymarin as a standard reference hepatoprotective drug.

Methods: Hepatoprotective activity was assessed by measuring biochemical parameters such as the liver function enzymes, serum alanine aminotransferase (ALT) and serum aspartate aminotransferase (AST). Equally, comparative effects of honey on oxidative stress biomarkers such as malondialdehyde (MDA), reduced glutathione (GSH) and glutathione peroxidase (GPx) were also evaluated in the rat liver homogenates. We estimated the effect of honey on serum levels and hepatic content of interleukin-1beta (IL-1 β) because the initial event in paracetamol-induced hepatotoxicity has been shown to be a toxic-metabolic injury that leads to hepatocyte death, activation of the innate immune response and upregulation of inflammatory cytokines.

Results: Paracetamol caused marked liver damage as noted by significant increased activities of serum AST and ALT as well as the level of IL-1 β . Paracetamol also resulted in a significant decrease in liver GSH content and GPx activity which paralleled an increase in IL-1 β and MDA levels. Pretreatment with honey and silymarin prior to the administration of paracetamol significantly prevented the increase in the serum levels of hepatic enzyme markers, and reduced both oxidative stress and inflammatory cytokines. Histopathological evaluation of the livers also revealed that honey reduced the incidence of paracetamol-induced liver lesions.

Conclusion: Honey can be used as an effective hepatoprotective agent against paracetamol-induced liver damage.

Keywords: Antioxidant, honey, hepatotoxicity, paracetamol, silymarin

Cite this article as: Galal RM, Zaki HF, Seif El-Nasr MM, Agha AM. Potential protective effect of honey against paracetamol-induced hepatotoxicity. *Arch Iran Med.* 2012; **15(11)**: 674 – 680.

Introduction

Paracetamol, a commonly used analgesic, is considered safe at therapeutic doses. However, an overdose of paracetamol causes severe hepatotoxicity and necrosis in both humans and experimental animals.^{1,2} At therapeutic levels, paracetamol is primarily metabolized in the liver by glucuronidation and sulphation; however, a small proportion undergoes cytochrome P450 (CYP450)-mediated bioactivation to N-acetyl-p-benzoquinimine (NAPQI), which is rapidly quenched by glutathione (GSH).³ After an overdose of paracetamol, elevated levels of the toxic NAPQI metabolite are generated, which extensively deplete hepatocellular GSH and covalently modify cellular proteins resulting in hepatocyte death.^{4,5}

Although the precise biochemical mechanism of cell necrosis is not fully understood, it is generally recognized that there is a simultaneous involvement of covalent binding, lipid peroxidation and oxidative stress.^{6,7} Many authors have demonstrated that honey is effective in reducing the risk of heart disease, cancer, declines in the immune system, cataracts, and different inflammatory processes.⁸ However, since the etiology of most diseases

involves oxidative damage, it is possible that some of the therapeutic properties of products produced by the honeybee are based on their antioxidant capacities.⁹

Over the past few years the use of honey in different pathologies has re-emerged, mainly due to clinical observations of its hepatoprotective and gastro-protective effects as well as acceleration of wound healing.^{10,11} Honey contains important components that can act as antioxidants, such as α -tocopherol, ascorbic acid, vitamins, organic acid, flavonoids, phenolic enzymes and other phytochemical compounds.¹²⁻¹⁴

Silymarin, a known hepatoprotective agent, is a flavonoid obtained from the plant *Silybum marianum* or milk thistle and is composed of three isomers: silybinin, silydianin and silychristin, of which silybinin is quantitatively the most important.¹⁵ Silybinin has been shown to inhibit the function of Kupffer cells, which are well-recognized sources of fibrogenic mediators.^{16,17} In addition, silymarin stabilizes the lipid structures in the hepatocellular membrane, which may generally apply to all cell membranes and even outside the liver.¹⁷

The aim of the present study is to evaluate the protective effects of honey in paracetamol-induced hepatotoxicity. Considering the fact that the initial event in paracetamol-induced hepatotoxicity is a toxic-metabolic injury that leads to hepatocyte death by necrosis and apoptosis and resultant activation of inflammatory cytokines, we have also estimated the effects of honey on serum levels and hepatic content of interleukin-1beta (IL-1 β). Finally histological examination of liver sections from all studied groups was performed.

Authors' Affiliations: ¹Department of Pharmacology and Toxicology, Cairo University, Cairo, Egypt.

Corresponding author and reprints: Reem M Galal MD, Department of Pharmacology and Toxicology, Cairo University, Cairo, Egypt. Address: 5 Hamouda Mahmoud, Nasr city, Cairo, Egypt. Tel: (+202)01226007408, Fax (+202)22748579, E-mail: Remogalal@yahoo.com.

Accepted for publication: 2 May 2012

Materials and Methods

Drugs and Chemicals

Paracetamol and silymarin were provided as gifts from Sedico Pharmaceutical Company. Honey was purchased from the Agricultural Research Center, El-dokki, Cairo, Egypt. The fresh multifloral honey samples were collected in the summer from the farm of the Agricultural Research Center which is based in El Monofiya Province in Egypt. The vegetation in these areas can be described as a mixture of various natural plants. Honey was standardized in the National Research Center, El-dokki, Cairo, Egypt. It is a complex mixture of carbohydrates, fatty acids, proteins and amino acids, vitamins and minerals. The primary flavonoids identified were the flavanones, pinobanksin and pinocembrin, and the flavones, chrysin and galangin.

Honey was dissolved in distilled water and orally administered in doses of 5, 10 and 20 g/kg, respectively. Kits for determination of serum aspartate aminotransferase (AST), serum alanine aminotransferase (ALT), GSH, glutathione peroxidase (GPx) and malondialdehyde (MDA) levels were obtained from Biodiagnostics, Egypt. The IL-1 β reagent kit was obtained from Biosource, USA.

Animals

Adult male albino rats of weights 150 – 200 g were purchased from the Faculty of Medicine, Cairo University (Cairo, Egypt). The animals were kept under suitable laboratory conditions throughout the period of investigation. Animals were fed standard pellet chow (El-Nasr Chemical Company, Cairo, Egypt) and allowed free access to water. The study was carried out according to the guidelines of the Ethics Committee of the Faculty of Pharmacy, Cairo University.

Experimental design

Six groups each that were comprised of six male Wistar albino rats were selected. The animals were orally treated for seven successive days as follows: groups I and II received normal saline (5 ml/kg) and served as the normal and control groups, respectively. Group III received silymarin (100 mg/kg/day) whereas groups IV-VI received 5, 10 and 20 g/kg honey, respectively.

On the sixth day (i.e., one day before the last treatment) animals of all groups fasted for 18 hours. On the seventh day, 1 h after the last dose of the test agents, all rats except those in the first group were given paracetamol (2 g/kg; p.o.). Blood samples were collected from the retro-orbital plexus of all rats 24 h after paracetamol administration. The separated sera were used for estimation of liver function tests as well as IL-1 β levels. Animals were then sacrificed by decapitation. Livers were rapidly isolated, a part of the liver was homogenized by using cold saline to prepare a 10% homogenate that was used for estimation of the chosen biochemical parameters. The second part of the liver was preserved in 10% formalin for histological examination.

Determination of biochemical parameters in the liver

Treatment of liver samples

Prepared homogenates were divided into three aliquots. The first one was deproteinized with ice-cooled 12% trichloroacetic acid. The obtained supernatant, after centrifugation at 1000 x g, was used for the estimation of GSH. The second aliquot was centrifuged at 1000 x g and the resultant supernatant was used for

estimation of MDA and IL-1 β contents. The third aliquot of the homogenate was used to prepare a cytosolic fraction of the liver by centrifugation at 105,000 x g for 15 min at 4°C using a cooling ultra-centrifuge (Sorvall Combiplus T-880, Du Pont, USA). The obtained clear supernatant (cytosolic fraction) was used for the determination of GPx activity.

Estimation of the chosen biochemical parameters

Serum ALT and AST activities were estimated using commercial kits and expressed as U/L. Hepatic GSH content and GPx activity were determined using a biodiagnostic kit and expressed as nmol/g. wet tissue and U/g. wet tissue, respectively. MDA content was determined colorimetrically using commercial kits and expressed in nmol/g. wet tissue. The serum and liver content of IL-1 β was carried out using an ELISA reagent kit and expressed as pg/ml and pg/g. wet tissue, respectively.

Statistical analysis

Values are presented as means \pm SE of the mean. Comparisons between different groups were carried out by one way analysis of variance (ANOVA) followed by Tukey-Karmer multiple comparisons tests. The level of significance was set at $P < 0.05$. SPSS was used for statistical analyses.

Results

Administration of paracetamol (2 g/kg) to animals that fasted for 18 h resulted in a 34-fold increased serum ALT level and a 17-fold increased AST level compared to the normal value (Figures 1 and 2). Prophylactic treatment with silymarin (100 mg/kg) and honey (5, 10 and 20 g/kg) prevented paracetamol-induced elevations in ALT and AST levels compared to the paracetamol control group (Figures 1 and 2).

Paracetamol caused marked depletion of hepatic GSH stores by 66% compared to the normal group (Figure 3). Pretreatment with silymarin or honey (20 g/kg) protected against GSH depletion by 42% and 44% respectively, compared to the paracetamol control group (Figure 3).

Hepatic GPx activity of the paracetamol group significantly reduced by 51% compared to the normal group. This effect was prevented by pretreatment with silymarin and honey (20 g/kg) by 55% and 48%, respectively, compared to the paracetamol control group (Figure 4).

Paracetamol resulted in an almost three-fold significant elevation in liver MDA content compared to the normal group (Figure 5). Pretreatment with silymarin ameliorated this effect by 55%; this effect was also ameliorated by honey at the following doses: 5 g/kg (57%), 10 g/kg (57%) and 20 g/kg (65%) compared to the paracetamol control group (Figure 5).

Paracetamol caused significant increases in serum (three-fold) and hepatic IL-1 β (four-fold) levels compared to the normal group (Figures 6a and 6b). The increase in serum IL-1 β level was attenuated by 20% in groups pretreated for one week with silymarin (100 mg/kg) and in honey at the following doses: 5 g/kg (14%), 10 g/kg (24%) and 20 g/kg (29%) compared to the paracetamol control group (Figure 6a). Similarly, the increase in hepatic IL-1 β content was ameliorated in the groups pretreated for one week with silymarin (10%); a 12% improvement was seen in the group treated with 5 g/kg honey, whereas a 20% improvement was

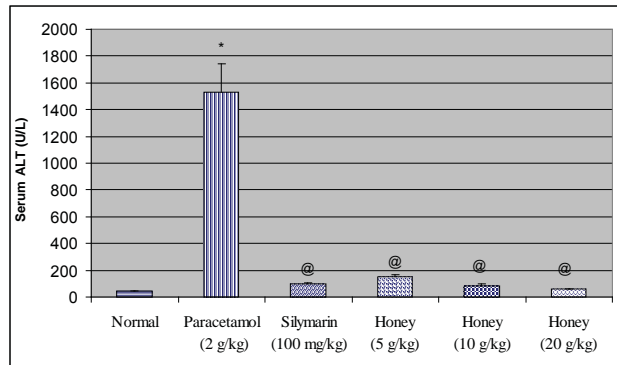


Figure 1. Effect of silymarin and varying doses of honey on serum alanine aminotransferase (ALT) activity in rats subjected to paracetamol-induced hepatotoxicity.*Significantly different from normal group at $P<0.05$. @Significantly different from paracetamol control group at $P<0.05$.

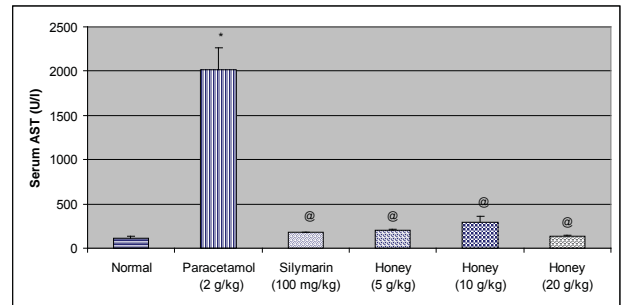


Figure 2. Effect of silymarin and varying doses of honey on serum aspartate aminotransferase (AST) activity in rats subjected to paracetamol-induced hepatotoxicity.*Significantly different from normal group at $P<0.05$. @Significantly different from paracetamol control group at $P<0.05$.

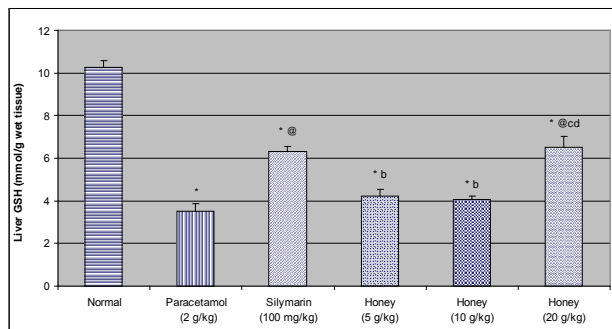


Figure 3. Effect of silymarin and varying doses of honey on liver glutathione (GSH) content in rats subjected to paracetamol-induced hepatotoxicity. *Significantly different from normal group at $P<0.05$. @Significantly different from paracetamol control group at $P<0.05$. ^bSignificantly different from silymarin group at $P<0.05$. ^cSignificantly different from honey group (5 g/kg) at $P<0.05$. ^dSignificantly different from honey group (10 g/kg) at $P<0.05$.

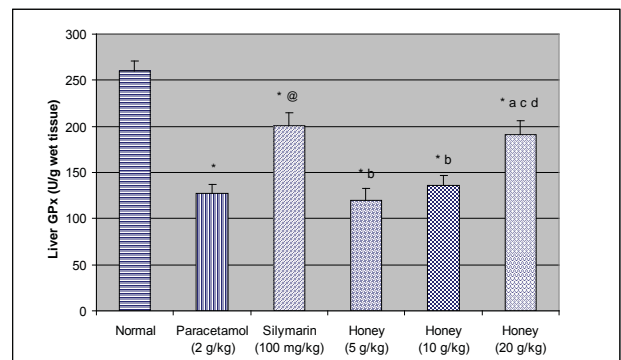


Figure 4. Effect of silymarin and varying doses of honey on liver glutathione peroxidase (GPx) activity in rats subjected to paracetamol-induced hepatotoxicity.*Significantly different from normal group at $P<0.05$. @Significantly different from paracetamol control group at $P<0.05$. ^bSignificantly different from silymarin group at $P<0.05$. ^cSignificantly different from honey group (5 g/kg) at $P<0.05$. ^dSignificantly different from honey group (10 g/kg) at $P<0.05$.

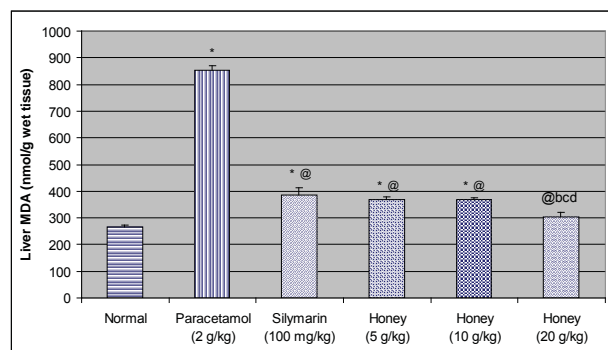


Figure 5. Effect of silymarin and varying doses of honey on liver malondialdehyde (MDA) content in rats subjected to paracetamol-induced hepatotoxicity. *Significantly different from normal group at $P<0.05$. @Significantly different from paracetamol control group at $P<0.05$. ^bSignificantly different from silymarin group at $P<0.05$. ^cSignificantly different from honey group (5 g/kg) at $P<0.05$. ^dSignificantly different from honey group (10 g/kg) at $P<0.05$.

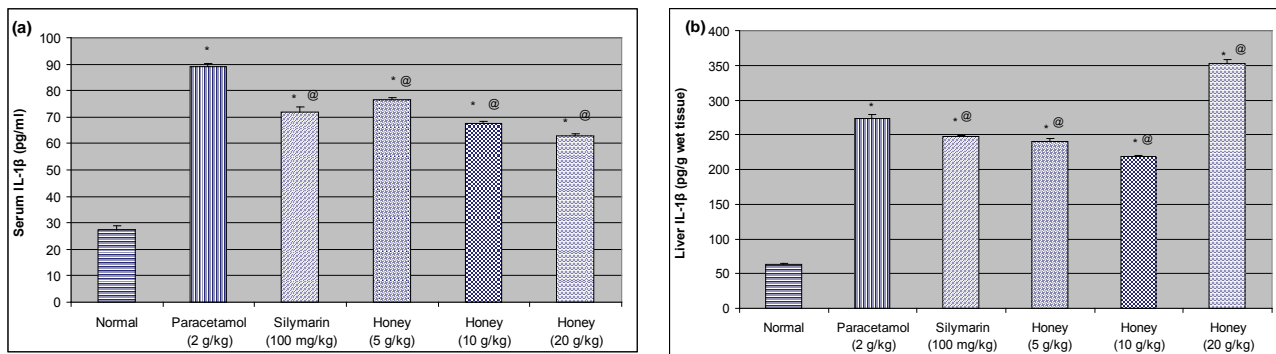


Figure 6. Effect of silymarin and varying doses of honey on serum level **a)** and liver content **b)** of interleukin-1beta (IL-1β) in rats subjected to paracetamol-induced hepatotoxicity. *Significantly different from normal group at $P < 0.05$. @Significantly different from paracetamol control group at $P < 0.05$.

noted in the group that received 10 g/kg honey compared to the paracetamol control group (Figure 6b).

Histologically, animals of group I (normal group) had normal hepatic architecture. The central veins, portal tracts, hepatocytes and sinusoids were of normal appearance (Figure 7). Group II (control group that received paracetamol) showed degenerative changes in most of the hepatic lobules (Figure 8). Wide areas of centrilobular coagulative necrosis with severe congestion and dilatation in both central and portal veins were also observed. The coagulative necrosis was characterized by loss of cellular detail and general architecture of hepatic parenchyma associated with mononuclear leucocyte inflammatory cell infiltration in between the remaining intact hepatocytes (Figure 8).

However, the rat groups that were pre-treated with silymarin and honey at a dose of 20 g/kg (Groups III and VI) exhibited significant liver protection against paracetamol-induced liver damage, as evident by the presence of normal hepatic cells and absence of necrosis (Figures 9 and 12).

Honey (5 g/kg) given prophylactically for one week did not prevent paracetamol-induced hepatic damage as noted by the presence of centrilobular coagulative necrosis characterized by loss of cell details which were observed in the examined liver sections, with some histologically intact hepatic parenchyma (Figure 10).

In case of sections from rats pretreated with honey (10 g/kg),

the hepatocytes showed hydropic degeneration in the cytoplasm characterized by intracytoplasmic vacuoles with eccentric nuclei (Figure 12). Diffuse Kupffer cell proliferation was also detected in between the hepatocytes (Figure 11).

Discussion

In the present study, administration of paracetamol (2 g/kg, p.o.) to fasting rats resulted in massive increases in both serum ALT and AST levels. Several researchers have reported elevations in serum transaminases following administration of toxic doses of paracetamol in rats.^{7,18,19}

Owing to their high concentrations and ease of liberation from the hepatocyte cytoplasm, ALT and AST are sensitive indicators of necrotic lesions within the liver.^{18,20} Hence, the marked release of transaminases into the circulation is indicative of severe damage to hepatic tissue membranes during paracetamol intoxication.^{21,22}

The observed significant decrease in serum transaminase activities in the honey and silymarin treated groups demonstrated their hepatoprotective effects against paracetamol damage. Similar results have been reported by other investigators.^{7,23-25} The protective effects of silymarin and honey could be explained via the preservation of membrane integrity mediated by their observed

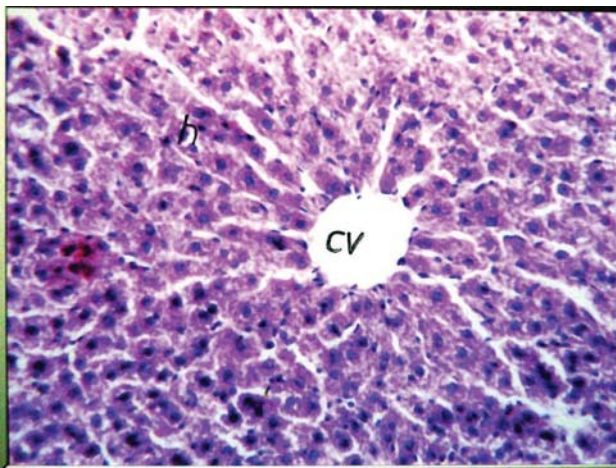


Figure 7. Photomicrograph of a liver section of normal rat showing the normal histological structure of the central vein (cv) and surrounding hepatocytes (h). (H&E; 64x)

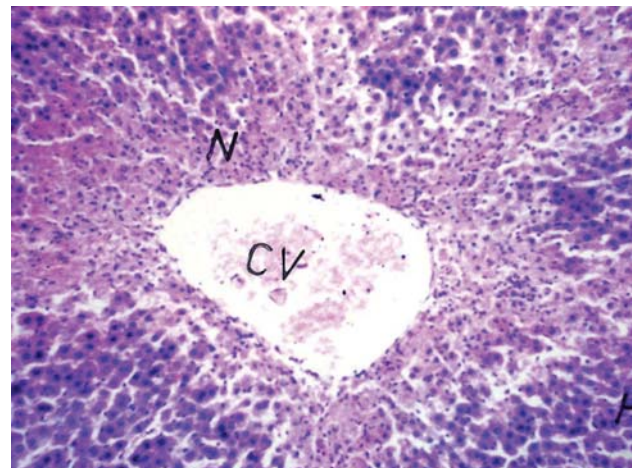


Figure 8. Photomicrograph of liver section of a rat subjected to paracetamol-induced hepatotoxicity showing congestion and dilatation of the central vein (cv) with centrilobular necrosis (N) in the surrounding parenchyma. (H&E; 40x)

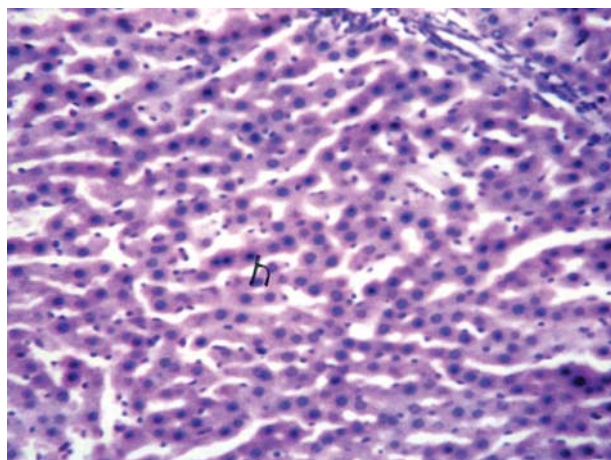


Figure 9. Photomicrograph of liver section of a rat pretreated for one week with silymarin (100 mg/kg) then subjected to paracetamol-induced hepatotoxicity showing an almost normal hepatic lobule with intact hepatocytes (h). (H&E; 40x)

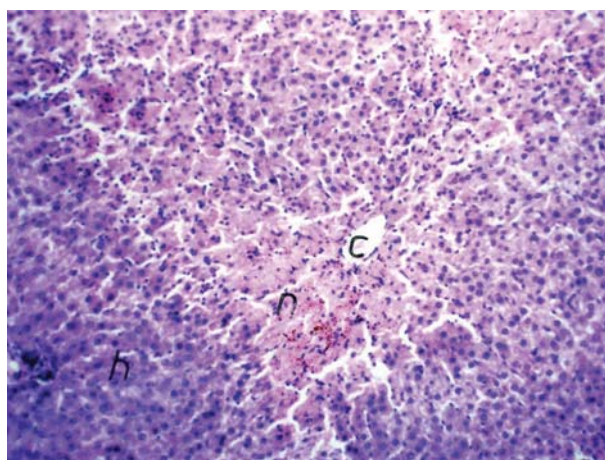


Figure 10. Photomicrograph of liver section of a rat pretreated for one week with honey (5 g/kg) then subjected to paracetamol-induced hepatotoxicity showing centrilobular necrosis (n) in the hepatocytes (h) surrounding the central vein (c). (H&E; 40x)

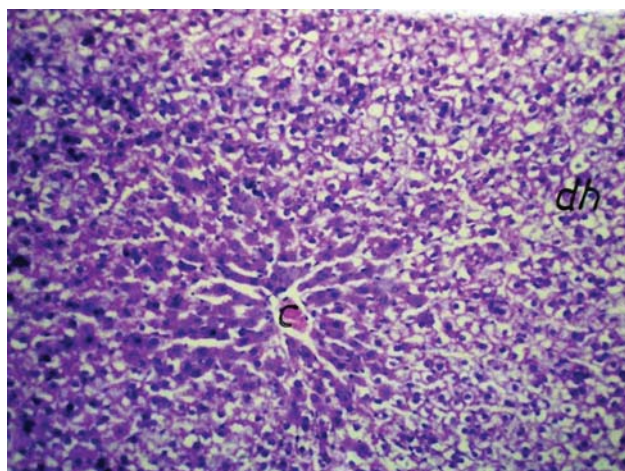


Figure 11. Photomicrograph of liver section of a rat pretreated for one week with honey (10 g/kg) then subjected to paracetamol-induced hepatotoxicity showing degeneration in the hepatocytes (dh) in a diffuse manner throughout the hepatic parenchyma. (H&E; 40x)

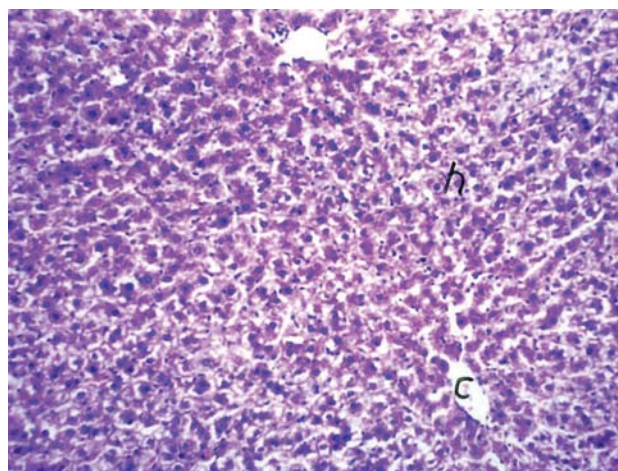


Figure 12. Photomicrograph of liver section of a rat pretreated for one week with honey (20 g/kg) then subjected to paracetamol-induced hepatotoxicity showing intact histological structure of the hepatic parenchyma (h) surrounding the central vein (c). (H&E; 40x)

antioxidants effects.

Histological examinations of liver sections of rats subjected to paracetamol hepatotoxicity revealed degenerative changes that involved the hepatocytes and cells that line the blood sinusoids. The damage extended to the majority of the hepatic lobule with marked loss of its normal pattern. These changes positively correlated with the noted increases in transaminase activities.

In the present study, paracetamol administration was accompanied by increased lipid peroxidation, depletion in GSH stores and reduced GPx activity in the liver. It has been generally accepted that P450-dependent bioactivation of paracetamol is the main cause for potentially fulminant hepatic necrosis upon administration or intake of lethal doses of paracetamol.^{26,27} NAPQI is initially detoxified by conjugation with reduced GSH to form mercapturic acid.²⁸ Under conditions of NAPQI formation following toxic paracetamol doses, GSH concentrations become very low in the centrilobular cells,²⁹⁻³¹ which could account for the observed depletion in liver GSH stores.

GPx plays a critical role in maintaining balance in the redox status of animals under acute oxidative stress and protects against

chemically-induced oxidative destruction of lipids and proteins.³² Consequently, it could be consumed during this process which would explain the observed reduced GPx activity in the paracetamol-treated group.

Increased lipid peroxidation, as evidenced by the elevated levels of MDA in hepatic tissues demonstrated in the present study after administration of paracetamol could be expected owing to the depletion in GSH stores and reduced GPx activity. It is well documented that liver tissue contains a relatively high content of polyunsaturated fatty acids (PUFAs), which are sensitive to peroxidative damage,^{33,34} another reason that could explain the marked effects of paracetamol on lipid peroxidation that has been observed in the liver in this study.

The observed protective effect of silymarin against lipid peroxidation could be related to its antioxidant effects which assist in the preservation of membrane integrity. This has also been supported by the observed parallel protection against paracetamol-induced depletion in GSH stores and GPx activity. Similar results have been reported by other investigators.^{19,23} Flavonoids as silymarin can chelate transition metal ions such as iron and copper, render-

ing them effective antioxidants.³⁵ In addition, silymarin by virtue of increasing GSH content in some tissues might protect these tissues against the toxicity of GSH depletors such as paracetamol.³⁶

In the present study, pretreatment with honey prevented paracetamol-induced increase in lipid peroxidation, depletion of GSH stores and reduced GPx activity. These findings have suggested that reduction of oxidative stress by honey plays an important role in the mechanism of its hepatoprotective effects.

Honey contains a variety of antioxidant phenolics such as pinobanksin and pinocembrin, and the flavones, chrysin and galangin, which makes it a good antioxidant supplement and increases its usability potential in ethnomedicine.^{37,38} The antioxidant effects of the phenolic compounds are related to a number of different mechanisms, such as free radical-scavenging, hydrogen-donation, singlet oxygen quenching, metal ion chelation, and their action as substrates for free radicals such as superoxide anion and hydroxyl radical.³⁹⁻⁴¹

In the present study, paracetamol hepatotoxicity was associated with an increase in serum level and liver content of IL-1 β . Similar results were reported by other investigators.⁴²⁻⁴⁵

Signaling through the IL-1 receptor (IL-1R) was recently shown to play an important role in paracetamol-induced hepatotoxicity.⁴⁶ The mechanisms by which IL-1 β is upregulated during the inflammatory response are not known. There are, however, extensive data on IL-1 β upregulation by a variety of pathogens. Activation of Toll-like receptors (TLRs) by pathogen-associated molecular patterns (PAMPs) results in upregulation of pro-IL-1 β via a MyD88/NF- κ B pathway. This is followed by a second signal that results in caspase-1-mediated cleavage of pro-IL-1 β to release the active molecule.^{47,48}

Pretreatment with silymarin in the present study decreased serum levels and liver content of IL-1 β in rats subjected to paracetamol hepatotoxicity. Similar results were reported by Soon et al.⁴⁹ who showed that silymarin has an inhibitory effect on the secretion of IL-1 β and expression of the IL-1 β gene in mouse peritoneal macrophages.

Previous studies have shown that silymarin has an inhibitory effect on NF- κ B/Rel activity in a human hepatoblastoma-derived cell line and human histiocytic lymphoma cells.^{50,51} Activation of NF- κ B/Rel transcription factor leads to the increased production of various inflammatory mediators, including IL-1 β and tumor necrosis factor-alpha (TNF- α).⁵²⁻⁵⁴

Soon et al., in 2004, have demonstrated that NF- κ B/Rel DNA binding is completely blocked by silymarin treatment in RAW264.7 cells. These results may suggest that inhibition of IL-1 β production by silymarin is mediated, at least in part, by the inhibition of the NF- κ B/Rel transcription factor.

In the present study, prophylactic treatment with honey (5 and 10 g/kg) decreased serum levels and the liver content of IL-1 β in rats subjected to paracetamol hepatotoxicity; whereas the highest dose level increased hepatic IL-1 β content. Interestingly, Tonks et al.⁵⁵ have reported that components isolated from honey stimulate the production of inflammatory cytokines [IL-1 β , interleukin-6 (IL-6) and TNF α] via TLR4. Similarly, it was shown previously that a variety of honey types stimulate human monocytic cells to produce inflammatory cytokines important in resolution of infection and tissue repair.⁵⁶

Honey has been reported to stimulate monocytes in cell cultures to release cytokines as TNF- α , IL-1, and IL-6, which act as intermediates in the immune response. Honey also supplies glucose

that is critical for the 'respiratory burst' in macrophages needed to generate hydrogen peroxide, and it provides substrates for glycolysis needed for energy production in macrophages.⁵⁷

Tonks et al. have demonstrated increased production of cytokines by myeloid cells in response to treatment with honey. The authors have related this effect to the 5.8 kDa moiety isolated from manuka honey, which stimulates inflammatory responses in monocytes via interactions with TLR4.

In conclusion, the results of this experiment demonstrate a potent hepatoprotective action of honey in paracetamol-induced oxidative stress and liver toxicity in rats. Such effects can be correlated directly with its ability to reduce lipid peroxidation and enhance the antioxidant defense status. Thus honey may be used as a safe, cheap, and effective alternative chemopreventive and protective agent in the management of liver diseases.

Acknowledgments

The authors are grateful to Dr. Adel Bekeer, Professor of Histology, Cairo University for examining and interpreting the histopathological data of this study.

References

- Kaplowitz N. Idiosyncratic drug hepatotoxicity. *Nat Rev Drug Discov*. 2005; **4**: 489 – 499.
- Jaeschke H, Williams CD, McGill MR, Farhood A. Herbal extracts as hepatoprotectants against acetaminophen hepatotoxicity. *World J Gastroenterol*. 2010; **16**: 2448 – 2450.
- James LP, Mayeux PR, Hinson JA. Acetaminophen-induced hepatotoxicity. *Drug Metab Dispos*. 2003; **31**: 1499 – 1506.
- Jollow DJ, Mitchell JR, Potter WZ, Davis DC, Gillette JR, Brodie BB. Acetaminophen-induced hepatic necrosis. II. Role of covalent binding in vivo. *J Pharmacol Exp Ther*. 1973; **187**: 195 – 202.
- Tiwari BK, Khosa RL. Hepatoprotective and antioxidant effect of *Sphaeranthus indicus* against acetaminophen-induced hepatotoxicity in rats. *The Internet Journal of Tropical Medicine*. 2010; **6**: 1540 – 2681.
- Bessemis JG, Vermeulen NP. Paracetamol (acetaminophen)-induced toxicity: molecular and biochemical mechanisms, analogues and protective approaches. *Crit Rev Toxicol*. 2001; **31**: 55 – 138.
- Randle LE, Sathish JG, Kitteringham NR, Macdonald I, Williams DP, Park BK. Alpha(1)-adrenoceptor antagonists prevent paracetamol-induced hepatotoxicity in mice. *Br J Pharmacol*. 2008; **153**: 820 – 830.
- Bertoncelj J, Dobersek U, Jamnik M, Golob T. Evaluation of the phenolic content, antioxidant activity and colour of Slovenian honey. *Food Chemistry*. 2007; **105**: 822 – 828.
- Hegazi AG, Abd El-Hady FK. Influence of honey on the suppression of human low density lipoprotein (LDL) peroxidation (In vitro). *Evid Based Complement Alternat Med*. 2009; **6**: 113 – 121.
- Molan PC. Potential of honey in the treatment of wounds and burns. *Am J Clin Dermatol*. 2001; **2**: 13 – 19.
- French VM, Cooper RA, Molan PC. The antibacterial activity of honey against coagulase-negative staphylococci. *J Antimicrob Chemother*. 2005; **56**: 228 – 231.
- Aljadi AM, Kamaruddin MY. Evaluation of the phenolic contents and antioxidant capacities of two Malaysian floral honeys. *Food Chemistry*. 2004; **85**: 513 – 518.
- Baltrusaityte V, Venskutonis PR, Ceksteryte V. Radical scavenging activity of different floral origin honey and beebread phenolic extracts. *Food Chemistry*. 2007; **101**: 502 – 514.
- Mahaneem M, Sirajudeen NS, Swamy M, Yaacob NS, Sulaiman SA. Studies on the antioxidant properties of tualang honey of Malaysia. *Afr J Trad CAM*. 2010; **7**: 59 – 63.
- Kshirsagar A, Ingawale D, Ashok P, Vyawahare N. Silymarin: A Comprehensive Review. *Pharmacognosy Reviews*. 2009; **3**: 116 – 121.
- Dehmlow C, Erhard J, de Groot H. Inhibition of Kupffer cell functions as an explanation for the hepatoprotective properties of silibinin. *Hepatology*. 1996; **23**: 749 – 754.

17. Jeong DH, Lee GP, Jeong WI, Do SH, Yang HJ, Yuan DW, et al. Alterations of mast cells and TGF-beta1 on the silymarin treatment for CCl(4)-induced hepatic fibrosis. *World J Gastroenterol.* 2005; **11**: 1141 – 1148.
18. Mahesh A, Shaheetha J, Thangadurai D, Rao DM. Protective effect of Indian honey on acetaminophen induced oxidative stress and liver toxicity in rat. *Biologia.* 2009; **64**: 1225 – 1231.
19. Rasool MK, Sabina EP, Ramya SR, Preety P, Patel S, Mandal N, et al. Hepatoprotective and antioxidant effects of gallic acid in paracetamol-induced liver damage in mice. *J Pharm Pharmacol.* 2010; **62**: 638 – 643.
20. Nkosi CZ, Opoku AR, Terblanche SE. Effect of pumpkin seed (Cucurbita pepo) protein isolate on the activity levels of certain plasma enzymes in CCl4-induced liver injury in low-protein fed rats. *Phytother Res.* 2005; **19**: 341 – 345.
21. Bairwa, NK Sethiya, Mishra S. Protective effect of stem bark of Ceiba pentandra linn. against paracetamol-induced hepatotoxicity in rats. *Pharmacognsy research.* 2010; **2**: 26 – 30.
22. Kuriakose GC, Kurup MG. Hepatoprotective effect of Spirulina lonar on paracetamol induced liver damage in rats. *Asian J Exp Biol Sci.* 2010; **1**: 614 – 662.
23. Girish C, Koner BC, Jayanthi S, Ramachandra Rao K, Rajesh B, Pradhan, SC. Hepatoprotective activity of picroliv, curcumin and ellagic acid compared to silymarin on paracetamol induced liver toxicity in mice. *Fundam Clin Pharmacol.* 2009; **23**: 735 – 745.
24. Patel N, Joseph, C, Corcoran, GB, Ray SD. Silymarin modulates doxorubicin-induced oxidative stress, Bcl-xL and p53 expression while preventing apoptotic and necrotic cell death in the liver. *Toxicol Appl Pharmacol.* 2010; **245**: 143 – 152.
25. Shati AA, Alamri SA. Role of saffron (Crocus sativus L.) and honey syrup on aluminum-induced hepatotoxicity. *Saudi Med J.* 2010; **31**: 1106 – 1113.
26. Bailey B, Amre DK, Gaudreault P. Fulminant hepatic failure secondary to acetaminophen poisoning: a systematic review and meta-analysis of prognostic criteria determining the need for liver transplantation. *Crit Care Med.* 2003; **31**: 299 – 305.
27. Lee WM. Acetaminophen and the U.S. Acute Liver Failure Study Group: lowering the risks of hepatic failure. *Hepatology.* 2004; **4**: 6 – 9.
28. Moore M, Thor H, Moore G, Nelson S, Moldeus P, Orrenius S. The toxicity of acetaminophen and N-acetyl-p-benzoquinone imine in isolated hepatocytes is associated with thiol depletion and increased cytosolic Ca²⁺. *J Biol Chem.* 1985; **260**: 13035 – 13040.
29. Oz HS, McClain CJ, Nagasawa HT, Ray MB, De Villiers WJ, Chen TS. Diverse antioxidants protect against acetaminophen hepatotoxicity. *J Biochem Mol Toxicol.* 2004; **18**: 361 – 368.
30. Masubuchi Y, Suda C, Horie T. Involvement of mitochondrial permeability transition in acetaminophen-induced liver injury in mice. *J Hepatol.* 2005; **42**: 110 – 116.
31. Volmar B, Menger MD. The hepatic microcirculation: mechanistic contributions and therapeutic targets in liver injury and repair. *Physiol Rev.* 2009; **89**: 1269 – 1339.
32. Cheng W, Fu YX, Porres, JM, Ross DA, Lei, XG. Selenium-dependent cellular glutathione peroxidase protects mice against a pro-oxidant-induced oxidation of NADPH, NADH, lipids, and protein. *FASEB J.* 1999; **13**: 1467 – 1475.
33. Peter B, Wartena M, Kampinga HH, Konings AW. Role of lipid peroxidation and DNA damage in paraquat toxicity and the interaction of paraquat with ionizing radiation. *Biochem Pharmacol.* 1992; **43**: 705 – 715.
34. Catala A. Lipid peroxidation of membrane phospholipids generates hydroxy-alkenals and oxidized phospholipids active in physiological and/or pathological conditions. *Chemistry and Physics of Lipids.* 2009; **157**: 1 – 11.
35. Bors W, Saran M. Radical scavenging by flavonoid antioxidants. *Free Radic Res Commun.* 1987; **2**: 289 – 294.
36. Videla LA, Valenzuela A. Alcohol ingestion, liver glutathione and lipoperoxidation: metabolic interrelations and pathological implications. *Life Sci.* 1982; **31**: 2395 – 2407.
37. Beretta G, Granata P, Ferrero M, Orioli, M, Facino, MR. Standardization of antioxidant properties of honey by a combination of spectrophotometric/florimetric assays and chemometrics. *Analytica Chimica Acta.* 2005; **533**: 185 – 191.
38. Van den Berg AJ, Van den Worm E, Van Ufford HC, Halkes SB, Hoekstra MJ, Beukelman CJ. An in vitro examination of the antioxidant and anti-inflammatory properties of buckwheat honey. *J Wound Care.* 2008; **17**: 172 – 174, 176 – 178.
39. Robards K, Prenzler PD, Tucker G, Swatsitang P, Glover W. Phenolic compounds and their role in oxidative processes in fruits. *Food Chemistry.* 1999; **66**: 401 – 436.
40. Al-Mamary M, Al-Meerri A, Al-Habori M. Antioxidant activities and total phenolics of different types of honey. *Nutrition Research.* 2002; **22**: 1041 – 1047.
41. Gupta VK, Sharma SK. Plants as natural antioxidants. *Natural products radiance.* 2006; **5**: 326 – 334.
42. Fiorucci S, Antonelli E, Mencarelli A, Palazzetti B, Alvarez-Miller L, Muscara M, et al. A NO-releasing derivative of acetaminophen spares the liver by acting at several checkpoints in the Fas pathway. *Br J Pharmacol.* 2002; **135**: 589 – 599.
43. Cover C, Liu J, Farhood A, Malle E, Waalkes, MP, Bajt ML, et al. Pathophysiological role of the acute inflammatory response during acetaminophen hepatotoxicity. *Toxicol Appl Pharmacol.* 2006; **216**: 98 – 107.
44. Imaeda AB, Watanabe A, Sohail MA, Mahmood S, Mohamadnejad M, Sutterwala, FS, et al. Acetaminophen-induced hepatotoxicity in mice is dependent on Tlr9 and the Nalp3 inflammasome. *J Clin Invest.* 2009; **119**: 305 – 14.
45. Stirnimann G, Kessebohm K, Lauterburg B. Liver injury caused by drugs: an update. *Swiss Med Wkly.* 2010; **140**: 13080.
46. Chen CJ, Kono H, Golenbock D, Reed G, Akira S, Rock KL. Identification of a key pathway required for the sterile inflammatory response triggered by dying cells. *Nat Med.* 2007; **13**: 851 – 856.
47. Mariathasan S, Newton K, Monack DM, Vucic D, French DM, Lee WP, et al. Differential activation of the inflammasome by caspase-1 adaptors ASC and Ipaf. *Nature.* 2004; **430**: 213 – 218.
48. Ogura Y, Sutterwala FS, Flavell RA. The inflammasome: first line of the immune response to cell stress. *Cell.* 2006; **126**: 659 – 662.
49. Soon KJ, Young JJ, Song-Kyu P, Kyu-Hwan Y, Mook KH. Protection against lipopolysaccharide-induced sepsis and inhibition of interleukin-1b and prostaglandin E2 synthesis by silymarin. *Biochemical Pharmacology.* 2004; **67**: 175 – 181.
50. Saliou C, Rihn B, Cillard J, Okamoto T, Packer L. Selective inhibition of NF-kappaB activation by the flavonoid hepatoprotector silymarin in HepG2. Evidence for different activating pathways. *FEBS Lett.* 1998; **440**: 8 – 12.
51. Manna SK, Mukhopadhyay A, Van NT, Aggarwal BB. Silymarin suppresses TNF-induced activation of NF-kappa B, c-Jun N-terminal kinase, and apoptosis. *J Immunol.* 1999; **163**: 6800 – 6809.
52. Hiscott J, Marois J, Garoufalis J, D'Addario M, Roulston A, Kwan I, et al. Characterization of a functional NF-kappa B site in the human interleukin 1 beta promoter: evidence for a positive autoregulatory loop. *Mol Cell Biol.* 2006; **13**: 6231 – 6240.
53. Hwang D, Jang BC, Yu G, Boudreau M. Expression of mitogen-inducible cyclooxygenase induced by lipopolysaccharide: mediation through both mitogen-activated protein kinase and NF-kappaB signaling pathways in macrophages. *Biochem Pharmacol.* 1997; **54**: 87 – 96.
54. Bohrer H, Nawroth PP. Nuclear factor kappaB--a new therapeutic approach? *Intensive Care Med.* 1998; **24**: 1129 – 1130.
55. Tonks AJ, Dudley E, Porter NG, Parton J, Brazier J, Smith EL et al. A 5.8-kDa component of manuka honey stimulates immune cells via TLR4. *J Leukoc Biol.* 2007; **82**: 1147 – 1155.
56. Tonks AJ, Cooper RA, Jones KP, Blair S, Parton J, Tonks A. Honey stimulates inflammatory cytokine production from monocytes. *Cytokine.* 2003; **21**: 242 – 247.
57. Molan PC. Re-introducing honey in the management of wounds and ulcers - theory and practice. *Ostomy Wound Manage.* 2002; **48**: 28 – 40.