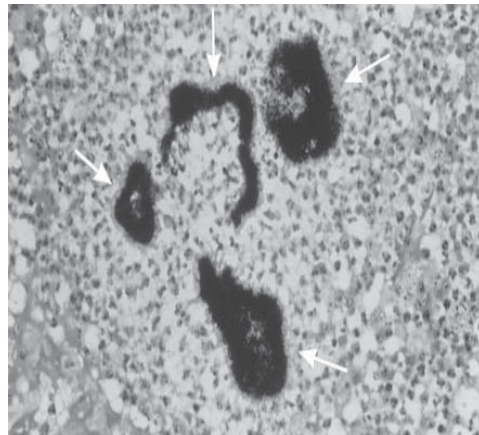
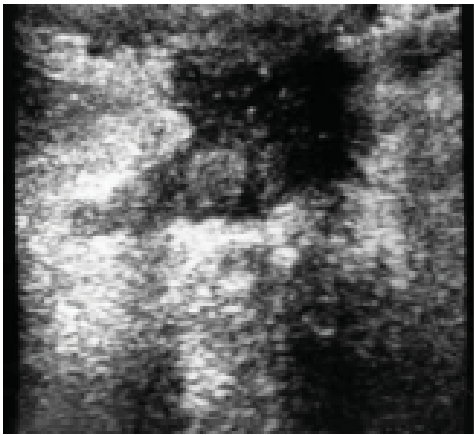
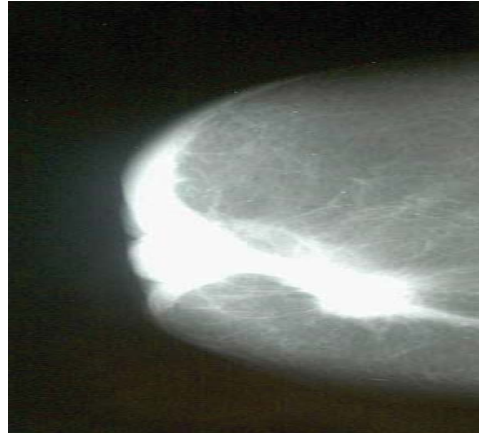
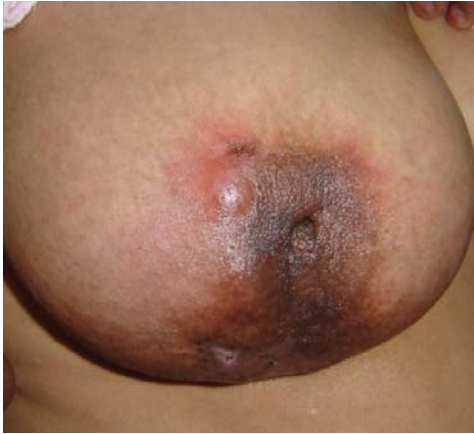
Photoclinic



Cite this article as: Farrokh D, Abedi M, Fallah Rastegar Y. *Arch Iran Med.* 2012; **15(11)**: 731 – 732.

A 46-year-old woman, presented to our Breast Clinic in the Surgery Department with complaints of a lump in the upper, central portion of her right breast (between the 12-and 1-o'clock positions), cutaneous fistula and nipple retraction of two years duration. She complained of no other symptoms and on physical examination she appeared healthy, except for the right breast mass. There was a skin fistula and skin discoloration. Nipple retraction and breast tenderness at palpation were also evident. Axillary lymph nodes were not palpable. Peripheral lymphadenopathy, hepatosplenomegaly or other abnormalities were not detected and general physical examination was unremarkable. The patient was afebrile. Her past medical history was unremarkable. She had a positive familial history for breast cancer in her grandmother.

Chest X-ray was normal. Routine laboratory examination revealed a mild leukocytosis. Erythrocyte sedimentation rate (ESR) was 65 and the other laboratory data were within normal limits.

Donya Farrokh MD¹, Mahboobeh Abedi MD¹, Yalda Fallah Rastegar MD¹
Authors' affiliations: ¹Department of Radiology, Imam Reza Hospital, Faculty of Medicine, Mashhad University of Medical Sciences, Mashhad, Iran.

•**Corresponding author and reprints:** Mahboobeh Abedi MD, Department of Radiology, Imam Reza Hospital, Faculty of Medicine, Mashhad University of Medical Sciences, Mashhad, Iran. Tel: +989133223400, Fax: +985118525004, E-mail: abedim871@mums.ac.ir.

Accepted for publication: 20 June 2012

The patient referred for radiological examination. Mammography showed an irregular mass with lobulated contours (spiculated margins) in the upper and central portion of the right breast accompanied by nipple retraction and skin thickening over the breast lesion. Our first diagnosis was inflammatory carcinoma or breast tuberculosis based on clinical and mammographic findings.

Ultrasonography of the right breast showed a collection of fluid with internal debris and fistulas draining to the skin. No axillary lymphadenopathy was found.

Fine needle aspiration biopsy of the breast mass was nondiagnostic, therefore an excisional biopsy was performed. Histological study revealed filamentous branching bacteria positive to silver impregnation stain (Grocott-Gomori methenamine-silver nitrate stain) and negative for Ziehl-Neelsen stain. Biopsy specimen was negative for malignant cells. The patient was treated with a two-month course of 24 million u/day of IV penicillin, followed by amoxicillin (500 mg orally), four times per day for an additional six months. The patient responded to treatment and imaging study (mammography and ultrasonography) on follow up showed no significant breast lesion.

**What is your diagnosis?
See the next page**

Actinomycosis is a chronic, suppurative granulomatous disease caused by the filamentous bacteria, *Actinomyces israeli*, which was once thought to be a fungus. It is a gram positive, aerobic or microaerobic, non-acid-fast bacteria which normally exists in the mouth, colon and vagina.¹⁻³ This disease is characterized by the formation of abscesses that drain from multiple sinus tracts containing discharges with sulfur granules.^{3,4}

Breast actinomycosis is an uncommon infectious disease that may be primary or secondary. Primary actinomycosis of the breast was first described by Ammentrep in 1893.^{1,2} Secondary actinomycosis of the breast is usually due to the extension of a pulmonary lesion through the thoracic cage in a process that can affect the ribs, muscles, and finally the breast. The disease usually presents as sinus tracts or mass-like lesions. The clinical presentation makes it difficult to distinguish primary breast actinomycosis from inflammatory carcinoma and mastitis.⁵

The main clinical forms of actinomycosis are craniofacial, thoracic, abdominal, and in women, pelvic.⁶ The disease is more common in men. Primary actinomycosis of the breast is a rare, slowly progressive infection. Inoculation occurs through the nipple. Possible causes of this unusual condition are trauma, lactation and kissing. The most common isolated cause is *Actinomyces israeli*. In recent years, other strains of actinomyces have been discovered. Capobianco et al. reported primary actinomycosis of the breast that was caused by *Actinomyces viscosus*.⁷ Attar et al. have reported cases of breast actinomycosis caused by *Actinomyces turicensis* and *Actinomyces radingae*.⁸

Breast actinomycosis usually involves premenopausal women. Our patient was a 46-year-old woman. Primary actinomycosis of the breast usually starts at the nipple, and most of the breast abscesses are retromamillary.¹ The most common clinical presentation in primary actinomycosis is recurrent abscesses with fistulas and sinus tracts.^{9,10} Purulent or bloody discharge from sinuses may be seen. Fibrosis with local cicatrization, skin retraction, and architectural distortion of the breast may occur in advanced cases. The disease may present as a breast lump that is usually impossible to distinguish from inflammatory carcinoma.^{7,9,11} Gogas et al. have stated that the correct diagnosis is frequently made after excisional biopsy or surgery.³ According to Jain et al., primary breast actinomycosis must be considered in the differential diagnosis of chronic abscesses and malignant lesions, based on clinical presentation.¹² Imaging findings that include mammography and ultrasonography are usually non-specific. According to de Barros et al., imaging studies may be helpful in some cases of suspected inflammatory carcinoma.¹³ Although imaging study may differentiate an inflammatory process from a malignant lesion by identifying a breast abscess, however distinguishing breast actinomycosis from other chronic mastitis, in particular breast tuberculosis and inflammatory carcinoma is possible only through pathologic examination.^{14,15} Computed tomography scanning and magnetic resonance imaging may help to detect the extension of the breast abscess and secondary involvement of the chest wall.¹³ Histological examination of the biopsy or mastectomy specimen usually shows sulfur granules which are composed of bacterial colonies.

Grocott-Gomori staining assists with establishing the diagnosis because it allows for detection of organisms that have filamentous branching, as observed with fungi and some bacteria such as No-

cardia and *Actinomyces israeli*.^{12,16} Nocardia can be excluded by Ziehl-Neelsen staining. In our patient the diagnosis was confirmed by histological study of the biopsy specimen. The Ziehl-Neelsen staining in our patient showed the presence of sulfur granules.

Cytological study of the specimen is often recommended to rule out a malignancy. The culture gives positive results in 50% of patients and should be performed with both aerobic and anaerobic media.¹² A gram stain of the specimen is usually more sensitive than cell culture, especially if the patient has received prior antibiotic treatment.

The most important differential diagnosis is inflammatory carcinoma.^{7,9,12,14} When fistulas are present, it is important to exclude chronic suppurative mastitis, breast tuberculosis, and chronic osteomyelitis of the rib.

The treatment of choice consists of the prolonged administration of penicillin. Alternative antibiotics are doxycycline, amoxicillin, erythromycin or clindamycin. Surgery may be indicated in advanced cases with multiple chronic breast abscesses and progressive cicatrization of the breast tissue.^{7,9,13}

References

- Lloyd-Davis JA. Primary actinomycosis of the breast. *Br J Surg*. 1951; **38**: 378 – 387.
- Pinto MM, Longstreth GB, Khoury GM. Fine needle aspiration of Actinomyces infection of the breast: A novel presentation of thoracopleural actinomycosis. *Acta Cytol*. 1991; **35**(4): 409 – 411.
- Gogas J, Sechas M, Diamantis S, Sbotos C. Actinomycosis of the breast. *Int surg*. 1972; **57**: 664 – 665.
- Lerner PI. Actinomycosis. In : Harrison TR, eds. *Medicina interna*. Rio de Janeiro. Mc Graw Hill. 1999: 732 – 735.
- Weese WC, Smith IM. A study of 57 cases of actinomycosis over a 36 – year period. A diagnostic “failure” with good prognosis after treatment. *Arch Intern Med*. 1975; **135**(12): 1562 – 1568.
- Apotheloz C, Royamey C. Disseminated infection due to actinomyces meyeri: case report and review. *Clin infect dis*. 1996; **22**: 621 – 625.
- Capobianco G, Dessole S, Becchere MP, Profilli S, Cosmi E, Cherchi PL, et al. A rare case of primary actinomycosis of the breast caused by actinomyces viscosus, diagnosed by fine – needle aspiration cytology under ultrasound guidance. *Breast J*. 2005; **11**(1): 57 – 59.
- Attar KH, Waghorn D, Lyons M, Cunnick G. Rare species of actinomyces as causative pathogen in breast abscess. *Breast J*. 2007; **13**: 501 – 505.
- Salmasi A, Asgari M, Khodadadi N, Rezaee A. Primary actinomycosis of the breast presenting as a breast mass. *Breast care (Basel)*. 2010; **5**(2): 105 – 107.
- Akhlaghi M, Ghazivini RD. Clinical presentation of primary actinomycosis of the breast. *Breast J*. 2009; **15**(1): 102 – 103.
- Ghazivini RD, Zibafar E, Zaini F, Omidi K. First case report of primary actinomycosis of the breast due to actinomyces israeli from Iran. *Acta Med Iran*. 2003; **41**: 110 – 112.
- Jain BK, Sehgal VN, Jagdish S, Ratnakar C, Smile SR. Primary actinomycosis of the breast: a clinical review and a case report. *J Dermatol*. 1994; **21**: 497 – 500.
- de Barros N, Issa FK, Barros AC, D’Avila MS, Nisida AV, Chammam Mc, et al. Imaging of primary actinomycosis of the breast. *AJR Am J Roentgenol*. 2000; **174**: 1784 – 1786.
- Lacoste C, Escande MC, Jammot C, Nos C. Breast actinomycosis: abscess simulating primary malignancy : a case diagnosed by fine – needle aspiration. *Diagn Cytopathol*. 2009; **37**(4): 311 – 312.
- Nandell GL, Bennett JE, Dolin R. Principles and practice of infectious diseases. 6th Eds. Saunders. 2005; 2924 – 2931.
- Hennrikus EF, Pederson L. Disseminated actinomycosis. *West J Med*. 1987; **147**: 201 – 204.