
Case Report

Shrapnel Splinter in the Common Bile Duct

Mohammad Hossein Somi MD*, Parisa Rezaeifar MD*

Obstructive jaundice is infrequently caused by a foreign body. We report a 42-year-old man who presented with obstructive jaundice by an impacted shrapnel splinter in the common bile duct (CBD) 23 years after a combat injury. To our knowledge, this is the first case report of this type in Iranian literature, although there are a few reports of combat related injuries in other countries. This diagnosis should be considered in the assessment of any patient with jaundice and abdominal pain who has experienced a previous combat injury.

Archives of Iranian Medicine, Volume 13, Number 1, 2010: 53 – 56.

Keywords: Common bile duct • foreign body • obstructive jaundice

Introduction

The importance of foreign bodies in the biliary tract receives little attention because they are rare causes of obstructive jaundice. Such foreign bodies include: fish bones,¹ dormia baskets,² vessel clips,³ cherry stalks,⁴ T-tube remnants,⁵ peel of greens, balls of thread,⁶ surgical gauzes,⁷ phytobezoars,⁸ bullets and shrapnel splinters.^{9,10}

This report describes the case of a 42-year-old man who presented with obstructive jaundice caused by an impacted shrapnel splinter in the biliary tract 23 years after the initial injury. This appears to be the first report of this type documented in Iranian literature.

Case Report

A 42-year-old male presented with a one month history of abdominal pain and jaundice. He was injured 23 years ago in the war between Iran and Iraq with multiple shrapnel splinters in his chest and upper right upper quadrant (RUQ) of the

abdomen. At that time he underwent a laparotomic repairing procedure to for a ruptured liver. Afterwards, he had no significant problem except fistulation from the surgery site to the skin which was healed by antibiotics and conservative therapy. One month before admission to our hospital he had experienced intermittent abdominal pain in the RUQ and epigastrium which radiated to the back. In spite of anti-dyspeptic drug administration in the outpatient clinic, his pain was not relieved and after a few days, he developed progressive icterus without nausea, vomiting, fever or weight loss. Physical examination on admission was significant for icterus, tenderness to deep palpation of the RUQ and an old laparotomy incision scar in the abdominal wall. Positive laboratory findings included: total bilirubin 5.35 mg/dL; direct bilirubin 3.5 mg/dL; aspartate aminotransferase 83 IU/L; alanine aminotransferase 210 IU/L; erythrocyte sedimentation rate 43 mm/hr; blood sugar 129 mg/dL; serum alkaline phosphatase 1390 U/L; and cancer antigen (CA) 19.9 from 100.9 U/mL.

A plain chest X-ray showed multiple shrapnel splinters resting in the right upper quadrant and the right part of the chest. Abdominal ultrasonography revealed a normal gallbladder, normal caliber of intrahepatic ducts and choledoch but mild dilatation of the common bile duct (6.7 mm). Spiral computed tomography (CT) scan reported a normal sized gallbladder, intrahepatic and extrahepatic ducts but multiple shrapnel splinters in the lower lobe of the right lung, right upper lobe

Authors' affiliation: *Liver and Gastrointestinal Disease Research Center (LGDRC), Tabriz University of Medical Science, Tabriz, Iran.

Corresponding author and reprints: Mohammad Hossein Somi MD, Liver and Gastrointestinal Diseases Research Center (LGDRC), Imam Hospital, Tabriz University of Medical Science, University Ave., 5166614756 Tabriz, Iran.

Tel: +98-411-336-7473, Fax: +98-411-336-7499

E-mail: mhosseinsina@yahoo.com

Accepted for publication: 8 December 2008

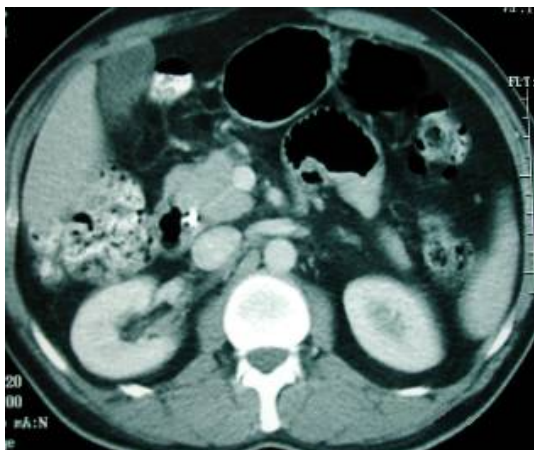

Figure 1. Spiral computed tomography (CT) scan showing a shrapnel splinter (right arrow) in the periampullary area near the head of the pancreas

of the liver, right kidney, subcutaneous tissue, and one in the periampullary area near the head of the pancreas (Figure 1). The latter one was presumed to be the probable cause of the patient's symptoms, thus the patient underwent a diagnostic endoscopic retrograde cholangiopancreatography (ERCP). There was a narrow segment dilatation in the common bile duct (CBD) and a filling defect in the CBD portion, which suggested a foreign body with a size of 5×7 mm (Figure 2). Subsequently, a sphincterotomy was performed and the foreign body, which was similar to shrapnel splinter, was pulled from the duct with a basket (Figures 3 and 4). The patient was assessed in the outpatient clinic two weeks later and found to be in good condition without evidence of jaundice or abdominal pain. Laboratory tests were within normal limits.

Discussion

Foreign bodies in the biliary tree are rare causes

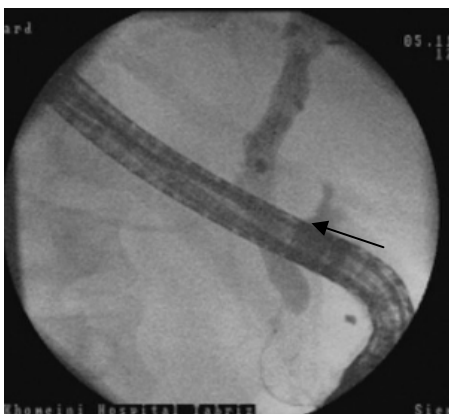

Figure 2. Endoscopic retrograde cholangiopancreatography imaging window showing a foreign body (black arrow) in the CBD before sphincterotomy

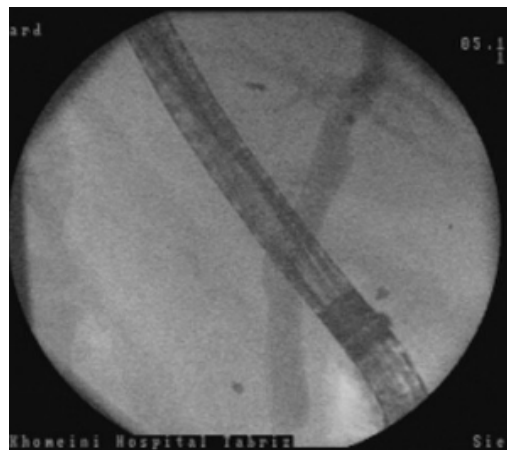


Figure 3. Endoscopic retrograde cholangiopancreatography imaging window after extraction of the foreign body following sphincterotomy

of obstructive jaundice.¹¹ Ban et al., in a review of 63 patients with foreign bodies in their biliary tracts during the past 75 years, report the most frequently encountered foreign bodies to be residuals from previous operations such as suture materials and endoclips (30 patients) and foreign bodies due to penetrating injuries which have been found in 12 patients. They place foreign bodies into three main categories: operative residuals, ingested objects and missiles.¹²

In patients who have experienced penetrating abdominal trauma by missiles, the liver and biliary systems are the most frequently damaged organs.¹³ Based on the velocity of the missiles, they are classified into two types: low velocity and high velocity. The high-velocity missile such as a bullet destroys the liver and biliary systems, while a low-velocity missile such as a shrapnel splinter can cause a crushing injury to the liver and biliary tree.¹³ Obstructive jaundice, induced by the shrapnel splinter, can occur by direct penetration of

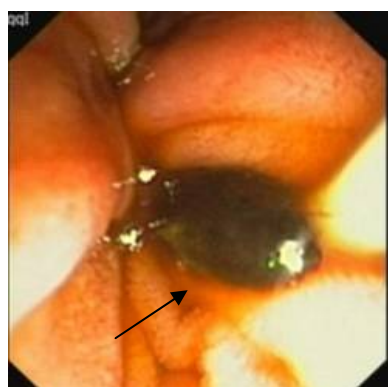


Figure 4. The shell splinter as a foreign body (black arrow) in the common bile duct as seen in the endoscopic retrograde cholangiopancreatography imaging window

Table 1. Characteristics of the reported cases of missiles in the biliary tree from combat injury

Reference	Age(yr)/gender	Type of foreign body	Positive symptoms and signs on admission	Original injury	Site of migration	Latent period
Kamona ¹⁴	14/M	Bullet	Abdominal pain	Liver parenchyma	CBD ¹	4 mo
Rescorla ¹⁵	8/F	Bullet	Abdominal pain in RUQ ² , Scleral icterus	Left lobe of the liver	CHD ³	22 mo
Maheshwari ¹⁶	22/M	Bullet	Jaundice, clay colored stool, hepatomegaly, palpable gallbladder	RUQ	CHD	32 mo
Klein ¹⁰	44/M	Shell splinter	Jaundice, abdominal pain	Foramen of Winslow	direct penetration to CBD	9 yr
Hussain ¹⁷	26/M	Bullet	Jaundice, right hypochondrial pain, vomiting, fever, weakness, fatigue and weight loss	Right lobe of the liver	CHD	9 yr
Kamona ¹⁴	44/M	Shrapnel	Fever, nausea, vomiting, jaundice, abdominal pain	Liver parenchyma	CHD	13 yr
Krontiris ¹⁸	36/M	Cap of a bullet	Fever, jaundice, acholic stool, anorexia, malaise, and weakness, abdominal pain in RUQ	Right lower thorax	CBD	13 yr
Eghuchi ¹³	60/M	Shrapnel splinter	Icterus, pruritus	Right thoracic cavity	CBD	36 yr
Mitchell ¹¹	64/M	Shrapnel splinter	Fever, weight loss, nausea, vomiting, abdominal pain, icteric sclera	RUQ	CBD	44 yr
Gottschalk ¹⁹	69/M	Shell splinter	Abdominal pain and tenderness in RUQ, jaundice	—	CBD	49 yr
Silvermann ²⁰	75/M	Shrapnel	Icterus, fever, abdominal pain	RUQ	CBD	Initial injury in World War 2
Present case	42/M	Shrapnel splinter	Jaundice, abdominal pain in RUQ	RUQ and right thorax	CBD	23 yr

¹CBD=common bile duct; ²RUQ=right upper quadrant; ³CHD=common hepatic duct

the bile duct, slow migration from the parenchymal surface or erosion through the diaphragm months and years after the initial injury. A review of the literature has shown that slow migration of the missile from the RUQ of the abdomen to be the most reported mechanism of migration (Table 1); while in two patients the initial site of injury was in the right thoracic cavity. Additionally in one patient, the missile lodged in the CBD by direct penetration.

Furthermore, in all reports the possible mechanism of the long time interval between initial injury and manifestation of obstructive jaundice (4 months to 49 years; Table 1) was believed to be slow migration of such foreign bodies into the biliary ducts as an attempt of the

body to exteriorize the foreign material.¹⁷ In this report, there was no evidence of the original site of the injury due to multiple impacted shrapnel splinters in the chest and RUQ but we presumed that the most probable mechanism for the presence of the shrapnel splinter in the CBD was slow migration from the parenchymal tissue of the liver because of the long time interval (23 years) between initial injury and appearance of the symptoms, and no significant formation of fibrosis tissue around the lodged foreign body that indicated direct invasion from the wall of the CBD.

Diagnostic assessment prior to the availability of the ERCP and CT scanning was limited. With development of therapeutic biliary procedures, such as ERCP, most foreign bodies can be

removed endoscopically.¹¹

Our case illustrates a common bile duct obstruction caused by a shrapnel splinter with a long latent period. It has been diagnosed and treated by ERCP. Although this case is a rare one, the possibility of splinter migration should be considered in the evaluation of any patient with jaundice and abdominal pain who has experienced a previous combat injury.

Acknowledgment

The authors thank Dr. Sara Farhang, general practitioner at the Liver and Gastrointestinal Disease Research Center (LGDRC), Tabriz University of Medical Science, for her assistance in preparing this paper.

References

- 1 Kim YH, Kim YJ, Park WK, Lee SK, Kwon JH, Woo SK. Fish bone as a nidus for stone formation in the common bile duct: Report of two cases. *Korean J Radiol.* 2004; **5**: 210 – 213.
- 2 Schutz SM, China C, Friedrichs P. Successful endoscopic removal of a severed, impacted Dormia basket. *Am J Gastroenterol.* 1997; **92**: 679 – 681.
- 3 Davis M, Hart B, Kleinman R. Obstructive jaundice from open vessel clip. *Gastrointest Radiol.* 1988; **13**: 259 – 260.
- 4 Kelly MD, Hugh TB. Cherry stalk in the common bile duct. *Aust N Z J Surg.* 1993; **63**: 571 – 574.
- 5 Rozario A, Thomas PG, Pais A, Ravindra KV, Rao V. Asymptomatic T-tube remnant in common bile duct. *Indian J Gastroenterol.* 1999; **18**: 180 – 181.
- 6 Zinsser E, Bosseckert H, Koppe P. Foreign bodies in the bile ducts and their endoscopic removal. *Gastroenterol J.* 1991; **51**: 12 – 14.
- 7 Cimsit B, Keskin M, Ozden I, Alper A. Obstructive jaundice due to a textiloma mimicking a common bile duct stone. *J Hepatobiliary Pancreat Surg.* 2006; **13**: 172 – 173.
- 8 Cetta F, Lombardo F, Rossi S. Large foreign body as a nidus for a common duct stone in a patient without spontaneous biliary enteric fistula or previous abdominal surgery. *HPB Surg.* 1993; **6**: 235 – 242.
- 9 Simmons TC, Essilfie W, Fleming A. Obstructive jaundice occurring 40 months after gunshot wound to the left thoraco-abdomen. *Gastrointest Endosc.* 1998; **48**: 423 – 425.
- 10 Klein E, Schneebaum S, Feuchtwanger MM, Strauss S, Ben-Ari G. Shell splinter in the common bile duct: a rare cause of obstructive jaundice. *Am J Surg.* 1981; **141**: 376 – 377.
- 11 Mitchell R, Kerr R, Barton J, Schmidt A. Biliary obstruction secondary to shrapnel. *Am J Gastroenterol.* 1991; **86**: 1531 – 1534.
- 12 Ban JL, Hirose FM, Benfield JR. Foreign bodies of the biliary tract: report of two patients and a review of the literature. *Ann Surg.* 1972; **176**: 102 – 107.
- 13 Eguchi S, Matsuo S, Hidaka M, Azuma T, Yamaguchi S, Kanematsu T. Impaction of a shrapnel splinter in the common bile duct after migrating from the right thoracic cavity: report of a case. *Surgery Today.* 2002; **32**: 383 – 385.
- 14 Kamona A, Mansour A, Qandeel M, Al-Eshaiker M. Biliary obstruction secondary to combat-related foreign bodies: report of two cases. *Abdom Imaging.* 2005; **30**: 748 – 749.
- 15 Rescorla FJ, Schlatter M, Hawes RH, Grosfeld JL. Delayed presentation of a penetrating biliary tract injury in a child. *J Trauma.* 1996; **40**: 157 – 158.
- 16 Maheshwari M, Chawla A, Dalvi A, Thapar P, Raut A. Bullet in the common hepatic duct: a cause of obstructive jaundice. *Clin Radiol.* 2003; **58**: 334 – 335.
- 17 Hussain SM, Zulqurnain S, Saleem O. Delayed obstructive jaundice secondary to bullet in common hepatic duct. *J Coll Physicians Surg Pak.* 2007; **17**: 232 – 233.
- 18 Kronriris A, Tsmonis A. Common duct obstruction by a bullet compression cap: a rare case. *Ann Surg.* 1962; **156**: 303 – 306.
- 19 Gottschalk U, Weber B, Felfe R. Obstructive jaundice after grenade splinter injury 49 years ago. *Z Gastroenterol.* 1993; **31**: 201 – 204.
- 20 Silverman WB. Sclerosing cholangitis caused by old shrapnel injury. *Gastrointest Endosc.* 2003; **58**: 420.