

---

## Case Report

---

# Carpal Tunnel Syndrome due to Lipofibromatous Hamartoma of the Median Nerve

Ahmadreza Afshar MD<sup>\*</sup>\*

---

**This report describes a rare case of secondary carpal tunnel syndrome due to a lipofibromatous hamartoma of the median nerve. Excision of the fibrofatty tissue between the nerve fascicles without risking damage to the fascicles was impossible. The transverse carpal ligament was incised and an epineurotomy was performed. Within six months, the 25-year-old female patient's symptoms were much improved.**

*Archives of Iranian Medicine, Volume 13, Number 1, 2010: 45 – 47.*

---

**Keywords:** Carpal tunnel syndrome • lipofibromatous hamartoma • tumor of the median nerve

### Introduction

**L**ipofibromatous hamartoma is a very uncommon, benign slow-growing peripheral nerve tumor<sup>1-6</sup> first reported by Mason in 1953.<sup>7</sup> Macroscopically, the tumor appears as a fleshy yellow mass composed of the nerve with fibrofatty strands invading the epineurium. Microscopically fibrofatty elements of the tumor invade the peri- and endoneurium, separating the individual nerve fibers or groups of fibers. The tumor is probably a hamartoma since the fibrous, fatty and neural elements are essentially mature.<sup>2-4</sup> This tumor is most often found in the median nerve with a predilection for the carpal tunnel.<sup>6</sup>

This report describes a rare case of secondary carpal tunnel syndrome due to a lipofibromatous hamartoma of the median nerve.

### Case Report

The 25-year-old female patient who was diagnosed with carpal tunnel syndrome experi-

enced numbness in her right middle finger for a few weeks prior to her admission. For several years, she had right wrist pain, nocturnal paresthesia, and paresthesia in the median nerve territory. Both the Tinel's sign and Phalen test were positive. Additionally, the right thumb and thenar prominence were abnormally enlarged. According to the patient, the thumb macrodactyly had a constant volume for several years. There was no visible swelling at the wrist and distal forearm. Ultrasonography of the carpal tunnel did not provide a diagnostic clue, however, an electrophysiological study confirmed severe carpal tunnel syndrome. There was no café-au-lait spot or other signs of neurofibromatosis.

Under regional block, the patient underwent an open carpal tunnel release. After dividing the palmar fascia, there was a bulging of fatty tissue at the distal edge of the transverse carpal ligament. Following division of the transverse carpal ligament, an enormously enlarged median nerve infiltrated by fatty tissue was observed. The skin incision continued above the wrist crease. The abnormal tumoral appearance of the median nerve was located about five centimeters proximal to the wrist and extended to the beginning of the digital branches (Figure 1). The tumoral fat was without an obvious capsule and infiltrated into the nerve. There was a thick epineurium that surrounded the nerve. An epineurotomy was performed which revealed a severely infiltrated fatty tissue and

---

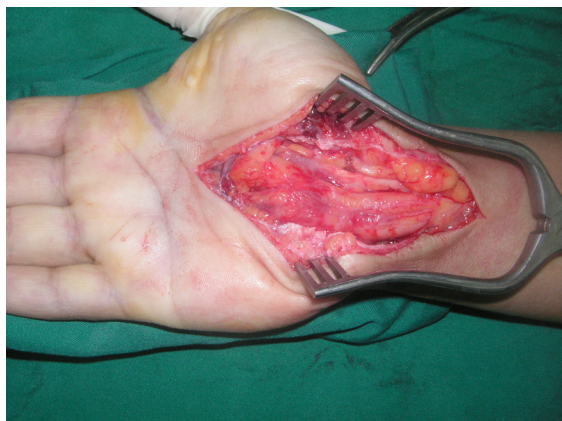**Author's affiliation:** \*Department of Orthopedics, Urmia University of Medical Sciences, Urmia, Iran.

**•Corresponding author and reprints:** Ahmadreza Afshar MD, Department of Orthopedics, Imam Khomeini Hospital, Modarres St., Ershad Blvd., Urmia, Iran

Tel: +98-912-313-1556, Fax: +98-441-346-9939

E-mail: afshar@umsu.ac.ir; Afshar\_ah@yahoo.com

Accepted for publication: 29 January 2009

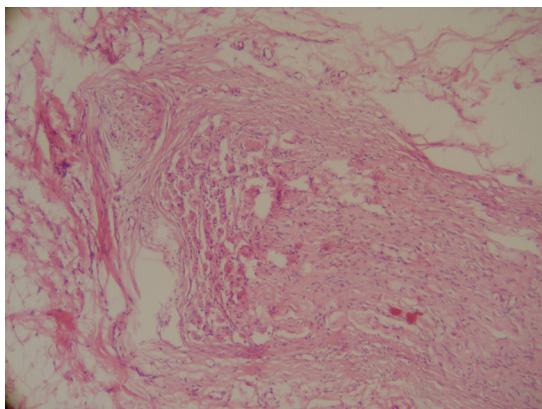


**Figure 1.** The intra-operative view of the lipofibromatous hamartoma of the right hand's median nerve of the patient

fibroses between the nerve fascicles. Excision of the fatty tissue between the nerve fascicles was impossible without the risk of incurring damage to them. Therefore, the tumor was left intact, and the operation was limited to a transverse carpal ligament release and epineurotomy. A small piece of the tissue was removed for histological examination; which showed fibrofatty elements of a tumor with an indefinite lobular pattern separating the nerve fascicles and fibers (Figure 2). Six months after surgery, the patient had marked improvement in her symptoms and there was no increase in tumor size. The term lipofibromatous hamartoma best describes the nature of this tumor.

## Discussion

Lipofibromatous hamartoma differs from a true lipoma of the median nerve; which is a soft encapsulated tumor that is easily shelled out from the surrounding tissue and contains no neural elements.<sup>2</sup>



**Figure 2.** The histopathological view of lipofibromatous hamartoma of the right hand's median nerve (H&E, ×100)

The cause of lipofibromatous hamartoma is unknown, however, a congenital or developmental origin is likely since a majority of the tumors are present and manifest at a young age.<sup>4</sup> In a majority of cases the median nerve is involved. The strong predilection for the median nerve is unexplained.<sup>1</sup> Usually the first symptoms are paresthesia and carpal tunnel syndrome. MRI imaging is an important tool for pre-operative evaluation and findings are characteristic to provide a diagnosis.<sup>8-10</sup> Lipofibromatous hamartoma of the median nerve is commonly associated with macrodactyly.<sup>1,2</sup>

There are two broad categories of tumors that can compress a peripheral nerve including the median nerve at the carpal tunnel: tumors with a neural sheath origin and those that have a non-neural sheath origin. Those tumors originating from the non-neural sheath include some rare benign and malignant tumors such as ganglions, hemangiomas, and lipomas, to name a few. The treatment of this type of lesion is usually straightforward and its complete excision can provide a cure. However, complete excision of an intra-neural tumor may not be feasible and can give rise to a neurological deficit.<sup>11</sup>

The treatment of lipofibromatous hamartoma is highly controversial. Given the absence of symptoms and lack of major deformity, a wait and see approach is recommended.<sup>9</sup>

Infiltration of fibrofatty tissue between the nerve fascicles excludes complete excision of the abnormal tissue. Resection of the involved portion of the nerve results in various degrees of neural deficit and seems to be unnecessary.<sup>4</sup> Therefore, complete excision of the tumor can be achieved at the cost of sacrificing the nerve and is usually contraindicated.<sup>9</sup>

Louis et al. observed slow but progressive loss of nerve function in a long-term follow-up of four patients.<sup>3</sup> Houpt et al. advocated complete excision along with nerve grafting in children and an immediate tendon transfer in adults.<sup>12</sup> Some authors had a satisfactory outcome after decompression of the median nerve by dividing the transverse carpal ligament.<sup>1,2</sup>

This case is presented because of its rarity.

Awareness of the existence of such a rare tumor and the development of carpal tunnel syndrome may lead to better evaluation, management and understanding of similar soft tissue lesions.

## Conflict of interest statement

There is no conflict of interest of any kind in

preparing this manuscript.

## References

- 1 Al-Qattan MM. Lipofibromatous hamartoma of the median nerve and its associated conditions. *J Hand Surg Br.* 2001; **26**: 368 – 372.
- 2 Camilleri IG, Milner RH. Intraneural lipofibroma of the median nerve. *J Hand Surg Br.* 1998; **23**: 120 – 122.
- 3 Louis DS, Hankin FD, Greene TL, Dick HM. Lipofibromatous of the median nerve: Long-term follow-up of four cases. *J Hand Surg Am.* 1985; **10**: 403 – 408.
- 4 Patel ME, Silver JW, Lipton DE, Pearlman HS. Lipofibroma of the median nerve in the palm and digits of the hand. *J Bone Joint Surg Am.* 1979; **61**: 393 – 397.
- 5 Yeoman PM. Fatty infiltration of the median nerve. *J Bone Joint Surg Br.* 1964; **46**: 737 – 739.
- 6 Johnson RJ, Bonfiglio M. Lipofibromatous hamartoma of the median nerve. *J Bone Joint Surg Am.* 1969; **51**: 984 – 990.
- 7 Mason ML. Proceedings of American Society for Surgery of the Hand: presentation of cases. *J Bone Joint Surg.* 1953; **35A**: 273 – 275.
- 8 Nardella D, Sohawon S, Carlier A. Lipofibromatous hamartoma of the median nerve. Three case reports. *J Plast Reconstr Aesthet Surg.* 2009; **62**: e314 – e317.
- 9 Nouira K, Belhiba H, Baccar S, Miaaoui A, Ben Messaoud M, Turki I, et al. Fibrolipoma of the median nerve. *Joint Bone Spine.* 2007; **74**: 98 – 99.
- 10 Taddie KL, Fallat LM. Lipofibromatous hamartoma of nerve. *J Foot Ankle Surg.* 2007; **46**: 116 – 119.
- 11 Flores LP, Carneiro JZ. Peripheral nerve compression secondary to adjacent lipomas. *Surg Neurol.* 2007; **67**: 258 – 263.
- 12 Houpt P, Storm van Leeuwen JB, van den Bergen HA. Intraneural lipofibroma of the median nerve. *J Hand Surg Am.* 1989; **14**: 706 – 709.