

Case Report

Isolated Third Nerve Palsy from Mild Closed Head Trauma

Mohammad Reza Najafi MD¹, Noushin Mehrbod MD²**Abstract**

Head injury is a common occurrence in motor vehicle accidents. There are numerous causes for cranial nerve injury that include head trauma or other lesions. Few studies regarding cranial nerve injury following mild head trauma (GCS: 14 – 15) exist in the literature.¹ The oculomotor nerve is a somatic and visceral motor nerve. When it is completely injured the result is ptosis, pupils that are non-reactive to light and a lack of eye movement. We report the case of a completely isolated oculomotor nerve palsy associated with minor head injury.

Keywords: Head trauma, mild, third never palsy

Cite this article as: Najafi MR, Mehrbod N. Isolated third nerve palsy from mild closed head trauma. *Arch Iran Med.* 2012; **15(9)**: 583 – 584.

Case Report

A 40-year-old man was transported to the Emergency Department (Alzahra Hospital) following a motor vehicle accident in February 2011. At the time of the accident the patient was riding a motorcycle. Following the accident, the patient experienced a decreased level of consciousness for several hours after which he became alert, but had symptoms of dizziness, headache, diplopia, and retrograde amnesia.

The patient's past medical history was negative for diabetes, hypertension, hyperlipidemia or smoking. He denied any drug or substance abuse. There was no history of a previous head injury, or any other neurologic or metabolic disorders.

On examination, his vital signs were stable. There was no raccoon eye, Battle's sign, rhinorrhea or otorrhea noted. There were abrasive wounds on his right frontal region, complete ptosis of the right eye with lateral deviation of the eye ball and a dilated non-reactive pupil that measured 6 mm (Figure 1). Ophthalmological consult ruled out direct trauma to the globe.

His left eye had normal range of movement with a normal size reactive pupil. No other abnormality was noted in the neurological exam. Brain CT, brain MRI and MRA were normal (Figures 2 and 3). No significant abnormality was seen in the orbital CT. *Single-photon emission computed tomography* SPECT could denote the histochemical nature of the lesion, however unfortunately it was not performed at that time. A four-vessel angiography was normal one week following the head trauma.

Discussion

The oculomotor nerve innervates the extraocular muscles: the superior, inferior, and medial rectus; inferior oblique; levator palpebral; and iris sphincter. Complete unilateral oculomotor nerve palsy causes ptosis and pupillary dilation, with limited infraduction and abduction of the eye ball.² Oculomotor nerve palsy could be caused by cerebrovascular accidents, infiltration, tumor and severe

head injury. Isolated oculomotor nerve palsy due to closed minor head trauma is relatively rare, with an incidence of 0%-15%.³⁻⁷

Two similar cases have been previously reported in the setting of minor head trauma.⁸⁻¹⁰ In a ten case series reported by Tokuno et al., 71% had traumatic *Subarachnoid hemorrhage* (SAH) and 57% had evidence of skull fractures, both of which seemed to be the cause for third nerve palsy.¹¹ Nagseki et al. have identified six patients with internal ophthalmology internal ophthalmoplegia out of 929 patients admitted with head injuries. Only one patient had isolated oculomotor nerve palsy and normal imaging.⁹

Post-traumatic third cranial nerve injury can occur via either a direct or indirect mechanism. Direct oculomotor nerve injury may be the result of extreme distraction of the nerve, rootlet avulsion, distal fascicular damage or a decrease in blood supply. Third nerve avulsion and damage to surrounding structures has been noted to be the most important mechanism.^{12,13} Indirect injury can cause compression, displacement of the deformity as result of aneurysm or other lesion.¹⁰ The third nerve fascicle may be damaged due to posterior petroclinoid ligament stretching.² A brain MRI performed for our case did not show any lesion, therefore there was insufficient evidence of any abnormal changes related to this injury (Figure 2).

Prognosis of traumatic oculomotor palsy is poor and full recovery is uncommon.² Follow up of this case showed that after six months, there was partial recovery of the third nerve palsy, which was similarly reported in the ten case series by Tokuno et al.¹¹

In conclusion, the current case had minor head trauma with pure isolated third nerve palsy and a non-reactive dilated pupil, with no abnormal findings on brain CT and MRI, MRA and angiography.

As this appears to be a rare case, additional information is necessary to clarify the mechanism in general or specific to this case.

References

1. Coello Af. Cranial nerve injury after minor head trauma. *J neurosurg.* 2010; **113(3)**: 547 – 555.
2. Chen CC, Pai YM, Wang RF, Wang TL, Chong CF. Isolated oculomotor nerve palsy from minor head trauma. *BJ Sport Med.* 2005; **39**: 34.
3. Tiffin P, MacEwen CJ, Craig EA. Acquired palsy of the oculomotor, trochlear and abducens -nerve. *Eye.* 1996; **10**: 377 – 384.
4. Solmons NB, Solomons DJ, DeVilliers JC. Direct Traumatic third nerve palsy. *S Afr Med J.* 1980; **58**: 109 – 111.
5. Memon MY, Paine KWE. Direct injury of the oculomotor nerve in craniocerebral trauma. *J Neurosurg.* 1971; **35**: 461 – 464.

Authors' Affiliations: ¹Neurology Department, Alzahra Hospital, Isfahan University of Medical Sciences, Isfahan, Iran, ²Isfahan Neuroscience Research Center, Isfahan University of Medical Sciences, Isfahan, Iran.

Corresponding author and reprints: Mohammad Reza Najafi MD, Department of neurology, Alzahra Hospital, IUMS. E-mail: Najafi@med.mui.ac.ir

Accepted for publication: 22 February 2012

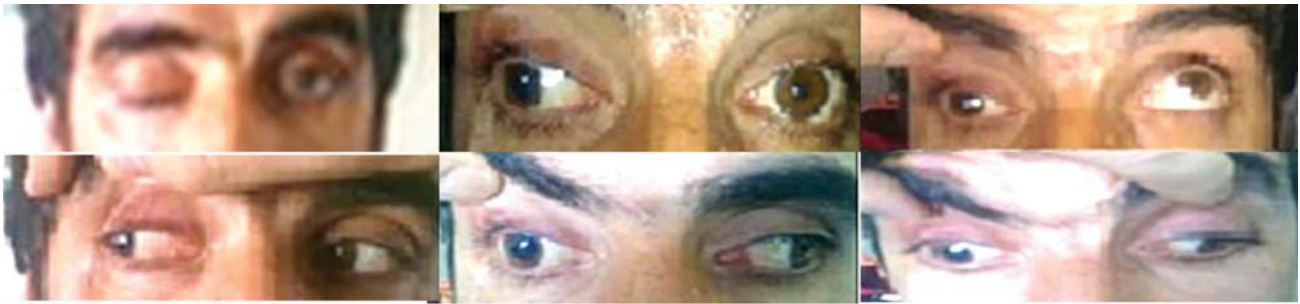

Figure 1. Eye movements in the patient showing right 3rd nerve palsy

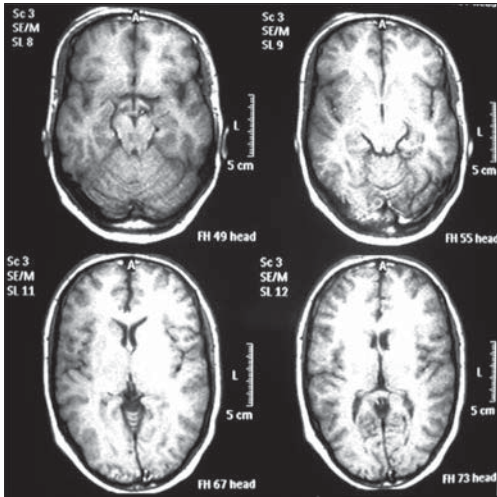


Figure 2. Normal brain MRI

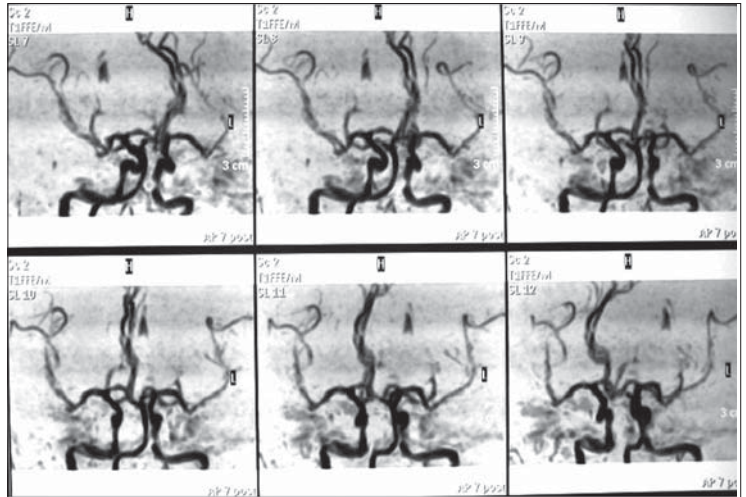


Figure 3. Normal brain MRA

6. Eyster EF, Hoyt WF, Wilson CB. Oculomotor palsy from minor head trauma. *JAMA*. 1972; **220**: 1083 – 1086.
7. Elston JS. Traumatic third nerve palsy. *Br Ophthalmologia . Acta Neurohir*. 1984; **68**: 528 – 543.
8. MuthuP, Pritty P. Mild head injury with isolated third nerve palsy. *Emerg Med J*. 2001; **18**: 310 – 311.
9. Nagaseki Y, Shimizu T, Kakizawa T. Primary internal opthalmoplagia due to head injury. *Acta Neurochir*. 1989; **97**: 117 – 122.
10. Heinz J. Cranial nerve avulsion and other neural injuries. *Med J Aust*. 1969; **2**:1246 – 1249.
11. Tokuno T, Nakazawa K, Yoshida S, Matsumto S, Shingu T, Sato S, et al. Primary oculomotor nerve palsy due to head injury: analysis of 10 cases. *No Shinkei Geka*. 1995; **23**: 497 – 501.
12. Liu YT, Lee YC. Isolated Oculomotor Nerve Palsy Due to Head Injury. *Journal of the Chinese Medical Association (JCMA)*. 2004; **67(3)**: 149 – 151.
13. Bianchi-Marzoli S, Brancato R. Third, fourth, and sixth cranial nerve palsies. *Curr Opin Ophtalmol*. 1997; **8**: 45 – 51.