

## Case Report

# Rib Plasmacytoma and IgA Multiple Myeloma with Hyperviscosity Syndrome

Vitorino Modesto dos Santos MD PhD<sup>1,3</sup>, Eduardo Flávio Oliveira Brito MD<sup>2</sup>, Bruno César Silva Paz MD<sup>3</sup>, Cristina Tavares Leal MD<sup>3</sup>

## Abstract

Solitary bone plasmacytoma (SPB) can progress to generalized myeloma if not treated early. The elderly population is increasing and delays in diagnosis of plasma cell malignancies are frequent among them. Hyperglobulinemia of multiple myeloma (MM) plays a role in hyperviscosity syndrome (HVS).

A 65-year-old woman with hypertension and diabetes mellitus was admitted due to loss of appetite, muscle weakness, breathlessness and discrete expectoration, without fever. Chest X-ray showed an abnormal shadow projection on the right lung field, while computed tomography (CT) revealed an osteolytic mass at the sixth rib. There were more than 50% of plasma cells in the bone marrow samples and high IgA levels according to serum electrophoresis.

Rib plasmacytoma and overt IgA-producing myeloma with HVS were diagnosed, but treatment was unsuccessful.

Case studies may enhance the awareness about this ominous condition, which may develop unnoticed, particularly in elderly patients with renal insufficiency, and can pose difficulties with diagnosis in primary care settings.

**Keywords:** Chest wall, myeloma, plasmacytoma, solitary rib tumor

**Cite this article as:** Santos VM, Brito EFO, Paz BCS, Leal CT. Rib Plasmacytoma and IgA Multiple Myeloma with Hyperviscosity Syndrome. *Arch Iran Med.* 2012; **15(8)**: 517 – 519.

## Introduction

Solitary plasmacytomas are characterized by a bone or soft-tissue mass, less than 5% of plasma cells in the bone marrow, and the absence of anemia, hypercalcemia, or renal dysfunction.<sup>1</sup> These rare tumors can mimic primary chest wall tumors. Solitary plasmacytoma of the bone (SPB) has a good outcome if treated early with surgery or radiotherapy. Unrecognized SBP can progress to multiple myeloma (MM).<sup>1</sup> In patients with MM, hyperglobulinemia and cell aggregation can be a source of hyperviscosity syndrome (HVS), which can develop unrecognized and may be mistaken as concomitant renal insufficiency.<sup>2,3</sup>

## Case Report

A 65-year-old woman with arterial hypertension and diabetes mellitus presented to the Emergency Department with muscular weakness and loss of appetite, associated with dyspnea on physical exertion of one-month duration. She had productive cough with hyaline expectoration, but denied any fever. There were palpitation episodes, mental disorientation, and inversion of the sleep pattern. Her hypertension and diabetes were controlled with atenolol 50 mg (bid), losartan 50 mg (qd), diamicron 30 mg (qd), and metformin 850 mg (bid). She denied tobacco smoking, alcoholism or illicit drug use. Previous chest radiography showed an opacity pro-

jection in the right lung field (Figures 1A and 1B) for which she received a course of levofloxacin, without improvement. Physical examination was remarkable for pale skin, muffled heart sounds and bilateral lung crackles. The BMI was 26.5 kg/m<sup>2</sup>, and she had an abdominal circumference of 90 cm, blood pressure of 130×80 mmHg, and heart rate of 78 bpm. There was no organ enlargement or edema.

Laboratory data are shown in Table 1. The high pro-BNP level was indicative of congestive heart insufficiency and diuretic administration affected her renal function. Hemodialysis was began (3×/week) with improvement in renal function. Insulin and erythropoietin were also administered. The remainder of the laboratory analysis revealed normal fibrinogen with a highly elevated erythrocyte sedimentation rate. Except for the presence of 51% plasma cells (normal: 3%–6%), with binucleated cells and blasts, the bone marrow aspirate was unremarkable (Figure 1D). Table 2 shows results from the electrophoresis of the serum proteins and immunoglobulins. Monoclonal IgA/kappa was characterized by immunofixation.

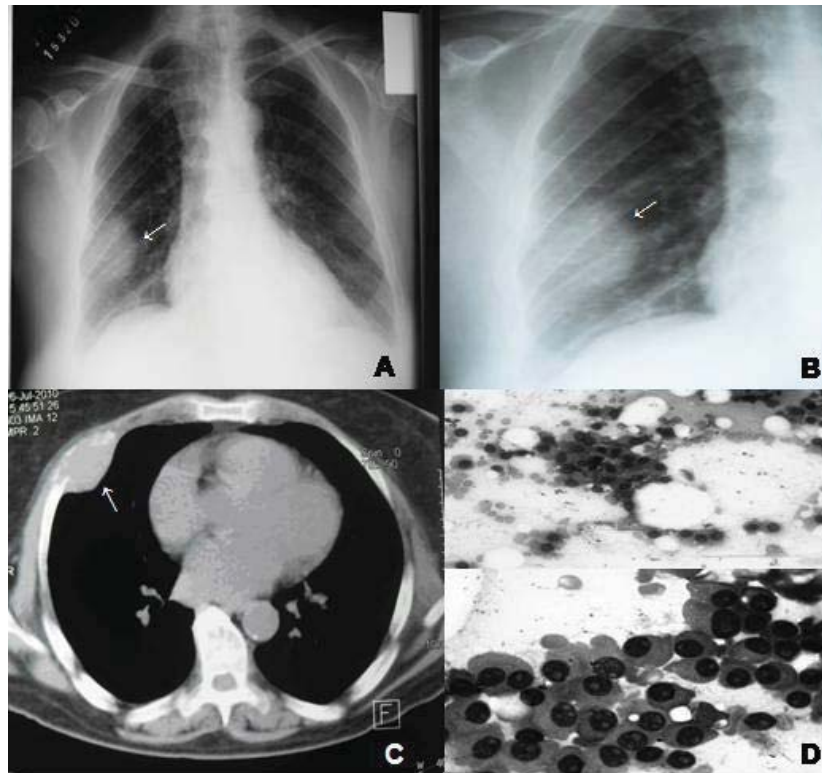
Echocardiogram showed myocardial relaxation changes with an ejection fraction of 65%. During hospitalization, she complained of lumbar pains with progressive deterioration in her level of consciousness. Thorax computed tomography (CT) revealed an osteolytic mass (4.8×4.1 cm) on the right fourth costal arch (Figure 1C). The findings of lumbar spine and brain CT studies were unremarkable, and the fundoscopic examination was notable for Grade II hypertensive retinopathy (Keith-Wagener). Therefore, malignancy associated with HVS was strongly considered. A diagnosis of stage III IgA-MM according to the International Staging System was established.<sup>4</sup>

Her consciousness level did not improve with cycles of dexamethasone. She was transferred to a specialized service where three

**Authors' affiliations:** <sup>1</sup>Catholic University of Brasília, Brasília-DF, Brazil. <sup>2</sup>Hematology Division of Armed Forces Hospital (HFA), Brasília-DF, Brazil. <sup>3</sup>Medicine Department of HFA, Brasília-DF, Brazil.

**Corresponding author and reprints:** Vitorino Modesto dos Santos PhD, Armed Forces Hospital. Estrada do Contorno do Bosque s/n, Cruzeiro Novo, 70630-900, Brasília-DF, Brazil. Tel: +55-61-32330812, Fax: +55-61-32331599, E-mail: vitorinomodesto@gmail.com.

Accepted for publication: 1 February 2012



**Figure 1. A and B)** Chest X-ray showing an image projected in the right lung field, first interpreted as an inflammatory or infectious pulmonary change (arrows). **C)** Chest CT demonstrating an osteolytic lesion on the right fourth rib (arrow). **D)** Bone biopsy/sternum aspiration showing a group of cells with plasma cell features (basophilic cytoplasm, eccentric nucleus, and conspicuous nucleolus). Global count revealed 51% of plasma cells in the bone marrow. (Magnification: 400× and 1000×)

**Table 1.** Routine laboratory data of a 65-year-old woman with rib plasmacytoma and IgA-producing myeloma with hyperviscosity syndrome (HVS).

Parameters	Day 1	Day 9	Day 14	Day 16	Day 22	Day 43	Normal range
Erythrocytes	<b>1.81</b>	<b>2.91</b>	<b>3.08</b>	<b>2.26</b>	<b>2.02</b>	<b>2.32</b>	4.4–6.0 ×10 <sup>12</sup> /mm <sup>3</sup>
Hemoglobin	<b>5.9</b>	<b>9.5</b>	<b>9.7</b>	<b>7.7</b>	<b>6.6</b>	<b>8.9</b>	11.1–16.1 g/dL
Hematocrit	<b>17.8</b>	<b>28.3</b>	<b>30.1</b>	<b>22.0</b>	<b>19.8</b>	<b>25.7</b>	39–53%
MCV	98	97	98	97	98	94	80–100 fl
Leukocytes	7.2	5.9	6.2	4.9	4.9	6.6	4.0–11.0 ×10 <sup>3</sup> /mm <sup>3</sup>
Platelets	301	213	197	<b>132</b>	<b>96</b>	<b>134</b>	150–450 ×10 <sup>3</sup> /mm <sup>3</sup>
ESR	ND	ND	<b>134</b>	ND	ND	ND	≤ 15 mm/hr
Pro-BNP	<b>17,311</b>	<b>14,134</b>	ND	ND	ND	ND	< 125 pg/mL
β2-m	ND	ND	<b>41.8</b>	ND	ND	<b>35.2</b>	0.7–1.8 mg/L
Sodium	133	138	140	143	137	<b>130</b>	135–145 mmol/L
Potassium	4.3	4.2	4.0	4.5	3.5	3.6	3.5–5.2 mmol/L
Calcium	<b>1.45</b>	<b>1.56</b>	<b>1.56</b>	<b>1.53</b>	<b>1.55</b>	1.32	1.16–1.32 mmol/L
Phosphorus	4.1	4.3	4.5	<b>7.2</b>	<b>6.1</b>	3.9	2.3–4.7 mg/dL
Magnesium	2.3	2.1	2.5	<b>3.0</b>	2.3	2.4	1.6–2.6 mg/dL
iPTH	<b>8.6</b>	ND	ND	ND	ND	ND	11–67 pg/mL
Ferritin	<b>9,145</b>	ND	ND	ND	ND	ND	13–150 ng/mL
Urea	<b>136.5</b>	<b>77.5</b>	<b>120.5</b>	<b>129.0</b>	<b>111.0</b>	<b>64.4</b>	10–50 mg/dL
Creatinine	<b>4.2</b>	<b>3.1</b>	<b>4.9</b>	<b>5.6</b>	<b>2.2</b>	<b>3.9</b>	0.7–1.3 mg/dL
Glucose	<b>248</b>	<b>145</b>	100	96	<b>122</b>	100	70–100 mg/dL

MCV = medium corpuscular volume; ESR = erythrocyte sedimentation rate; Pro-BNP = pro-brain natriuretic peptide; β2-m = β-2 microglobulin; iPTH = intact parathyroid hormone; ND = not done. Abnormal data are in bold.

sessions of plasmapheresis were performed. Hemodynamic tolerance was initially good, but there was irreversible pulmonary acute edema after the third session.

## Discussion

This elderly woman had chronic renal failure, respiratory disturbance, and heart failure. Blood tests showed severe anemia with elevated levels of calcium, ferritin, pro-BNP and β2-microglobulin (β2-m), and low intact parathyroid hormone (iPTH). Clinical man-

agement focused on the improvement of heart and renal functions. Thorax CT was suggestive of rib malignancy. During hospitalization, she complained of visual disturbance and lumbar pain, with fluctuating level of conscience and daily somnolence. Complementary data strengthened the hypothesis of HVS associated with malignancy.<sup>2,3,5</sup> Differential diagnoses of stroke, brain metastases, and intracranial hypertension were eliminated.

As with the present case, the classical triad of HVS may be incomplete,<sup>2,3</sup> and mild or atypical clinical signs and symptoms of HVS may develop unnoticed.<sup>3</sup> This often occurs in patients with

**Table 2.** Electrophoresis of serum proteins and immunoglobulins of a 65-year-old woman with rib plasmacytoma and IgA-producing myeloma with hyperviscosity syndrome (HVS).

Serum proteins	Levels (normal range)	Immunoglobulins	Levels (normal range)
Total proteins	12.6 (6.4–8.3) g/dL	IgG	204.3 (952–1538) mg/dL
Albumin	19.4 (55.8–66.1) %	IgA	8917 (153–359) mg/dL
Alfa 1 globulin	2.4 (2.9–4.9) %	IgM	0.0 (73–171) mg/dL
Alfa 2 globulin	5.1 (7.1–11.8) %	Kappa	2990 (625–1668) mg/dL
Beta 1 globulin	2.5 (4.7–7.2) %	Lambda	39.7 (368–803) mg/dL
Beta 2 globulin	1.9 (3.2–6.5) %		
Gama globulin	70.6 (11.1–18.8) %		

chronic renal failure. Asymptomatic hyperviscosity-related retinal changes have been described in a Japanese woman with MM and renal failure associated with HVS.<sup>5</sup> Nevertheless, we strongly believe that arterial hypertension caused the fundoscopic changes seen in our patient.

Monoclonal hypergammaglobulinemia of MM is a main cause of HVS, which is due to changes in size, shape and polymerization of the immunoglobulin molecules.<sup>2,3,5-7</sup> The relationship between HVS and high serum levels of IgA has been studied in patients with MM, and serum viscosity depends more on the high amounts of paraprotein than on the ratio between monomeric and dimeric IgA.<sup>6</sup> This patient presented with neurologic, ocular and cardiovascular symptoms as seen in 2%–6% of patients with MM and HVS. If the paraprotein is IgA, respective serum levels are usually more than 6 g/dL.<sup>7</sup>

Primary chest wall tumors can mimic pulmonary conditions on plain chest radiography.<sup>8</sup> The differential diagnosis of costal plasmacytoma includes chondrosarcoma, lymphoma, metastases, osteosarcoma, fibrosarcoma, neurectodermal tumor, Ewing sarcoma, histiocytoma, chondroma, chondromixoid fibroma, chondroblastoma, giant cell tumor, fibrous dysplasia, lipoma, and bone infarction.<sup>8</sup>

In this case, the diagnosis of rib plasmacytoma and MM was established by CT image,  $\beta_2$ -m, and histopathology data.<sup>4,9,10</sup> After diagnosis, the debilitated patient who had renal failure and HVS was treated with dexamethasone and plasmapheresis,<sup>2,3,5</sup> without success. Plasmapheresis was the treatment of choice because each session has been shown to reduce hyperviscosity in 20%–30% for session, and usually a maximum of three sessions are necessary.<sup>9</sup>

Of note was the unsuspected development of MM with the hypothetical origin in a solitary costal arch mass, which was mistaken by a pulmonary affection. Unrecognized development of MM is not uncommon.<sup>10</sup> SPB may precede the development of generalized myeloma, and could be predictive of an ominous progression.<sup>1</sup>

The aim is to emphasize the possibility of unnoticed evolution

of a solitary rib plasmacytoma to overt IgA MM associated with HVS. We believe that case reports may enhance the suspicion index about this condition in primary care settings.

**Financial disclosure:** There was no grant support for this study.

**Disclosure of potential conflicts of interest:** The authors had full freedom of manuscript preparation and there were no potential conflicts of interest.

## References

- Shih LY, Dunn P, Leung WM, Chen WJ, Wang PN. Localised plasmacytomas in Taiwan: comparison between extramedullary plasmacytoma and solitary plasmacytoma of bone. *Brit J Cancer*. 1995; **71**: 128–133.
- Adams BD, Baker R, Lopes JA, Spencer S. Myeloproliferative disorders and the hyperviscosity syndrome. *Hematol Oncol Clin North Am*. 2010; **24**: 585–602.
- Kwaan HC. Role of plasma proteins in whole blood viscosity: a brief clinical review. *Clin Hemorheol Microcirc*. 2010; **44**: 167–176.
- Bladé J, Teresa Cibeira M, Fernández de Larrea C, Rosiñol L. Multiple myeloma. *Ann Oncol*. 2010; **21**: 313–319.
- Noda S, Tsunemi Y, Ichimura Y, Miyamoto A, Tamaki Z, Takekoshi T, et al. Hyperviscosity syndrome associated with systemic plasmacytosis. *Clin Exp Dermatol*. 2011; **36**: 273–276.
- Alkner U, Hansson UB, Lindström FD. Factors affecting IgA related hyperviscosity. *Clin Exp Immunol*. 1983; **51**: 617–623.
- Mehta J, Singhal S. Hyperviscosity syndrome in plasma cell dyscrasias. *Semin Thromb Hemost*. 2003; **29**: 467–471.
- Santos VM, Paula FH, Sousa FP, Lima ELB, Barbosa NWP, Amarante RC. Precordial pain: an unusual primary presentation of chondrosarcoma. *Cancer Ther*. 2008; **6**: 321–326.
- Ballestri M, Ferrari F, Magistroni R, Mariano M, Ceccherelli GB, Milanti G, et al. Plasma exchange in acute and chronic hyperviscosity syndrome: a rheological approach and guidelines study. *Ann Ist Super Sanita*. 2007; **43**: 171–175.
- Santos VM, Castro RA, Marques Junior HVCF, Paula FH. Unsuspected multiple myeloma: a growing challenge? *Brasilia Med*. 2007; **44**: 138–141.