

Original Article

Scaffold-free Adipose-derived Stem Cells (ASCs) Improve Experimentally Induced Osteoarthritis in Rabbits

Fatemehsadat Toghraie DVM², Mahboobeh Razmkhah PhD¹, Mohammad Ali Gholipour DVM², Zahra Faghih MSc¹, Nooshafarin Chenari BSc¹, Simin Torabi Nezhad MD³, Seifollah Nazhvani Dehghani PhD², Abbas Ghaderi PhD^{2,4}

Abstract

Background: Osteoarthritis (OA) is the most common form of arthritis seen clinically. Current treatments for OA are limited to decreasing associated pain, maintaining or improving joint function, and minimizing disability. However, these treatments have no effect on the regeneration of hyaline cartilage. Since mesenchymal stem cells (MSCs) have been described as promising cell sources for cartilage repair, the present study was designed to examine whether intra-articular injection of scaffold-free adipose-derived stem cells (ASCs) obtained from subcutaneous adipose tissue could restore the matrix of arthritic knee joints in mature animals.

Methods: OA was induced in adult white New Zealand rabbits by unilateral anterior cruciate ligament transection (ACLT); the contralateral knee was considered the sham-operated group. At 12 weeks following surgery, the ASCs treated group was injected intra-articularly with a single dose of 1×10^6 cells suspended in 1 mL of medium. The control group received 1 mL of medium without cells and the sham-operated group received no treatment. All rabbits were sacrificed at 16 and 20 weeks after surgery. OA progression was evaluated radiologically, grossly, and histologically using hematoxylin and eosin, Safranin-O, and toluidine blue staining.

Results: At 12 weeks after surgery all knees subjected to ACLT showed radiological signs of OA. The findings showed significant differences in the quality of cartilage between ASCs-injected group compared to control group, particularly at 20 weeks after surgery.

Conclusion: This study suggests that ASCs obtained from subcutaneous adipose tissue could be a viable approach for treating OA.

Keywords: Adipose tissue, anterior cruciate ligament, hyaline cartilage, mesenchymal stem cells, osteoarthritis

Cite the article as: Toghraie F, Razmkhah M, Gholipour MA, Faghih Z, Chenari N, Torabi Nezhad S, Nazhvani Dehghani S, Ghaderi A. Scaffold-free Adipose-derived Stem Cells (ASCs) Improve Experimentally Induced Osteoarthritis in Rabbits. *Arch Iran Med.* 2012; **15**(8): 495 – 499.

Introduction

Degenerative joint disease (DJD) or osteoarthritis (OA) is the most common form of arthritis characterized by progressive deterioration of cartilage resulting in damage to underlying bone, loss of mobility and pain. It remains a great challenge to enhance the regeneration potential of hyaline cartilage tissue because of its avascularity and low cellular mitotic activity.^{1,2} Tissue degeneration activities initiated after major injury or due to age-related processes override the generally limited self-renewal capacity of cartilage.³ Recent investigations have focused on studying mesenchymal stem cells (MSCs) for cartilage tissue engineering.³ Our understanding of the biology of stem cells reveals that these cell populations play a critical role in homeostasis and repair of tissues. MSCs have the capacity to develop into various cells including chondrocytes, osteoblasts, and myocytes.^{4,5} Although MSCs have typically been derived from bone marrow, it has become clear that they may be isolated from various tissues, including skeletal muscle, fat, and synovial membrane.^{5,6} Recent evidence suggests that

adipose tissues can be a good candidate for isolation of MSCs. It has been shown that adipose-derived stem cells (ASCs) express the potential to differentiate into multiple tissue lineages such as osteogenic and chondrogenic phenotypes.⁵⁻⁷

In this study we investigated the regenerative potential of subcutaneous ASCs in a rabbit model of OA. Scaffold-free ASCs obtained from subcutaneous adipose tissue were injected intra-articularly and the therapeutic outcome of this strategy was evaluated.

Materials and Methods

Animals

Adult New Zealand white rabbits that weighed 2.5–3.5 kg and had closed epiphyses were used in this study. Animals were obtained from the Laboratory Animal Department at Razi Vaccine and Serum Research Institute (Tehran, Iran). The Research Animal Care and Use Committee of the School of Veterinary Medicine at Shiraz University, Shiraz Iran approved this study.

Isolation and culture of adipose-derived stem cells (ASCs)

A sterile surgical procedure was used to obtain subcutaneous adipose tissue from an adult New Zealand white rabbit that weighed 2.8 kg. Tissues were washed three to four times with phosphate buffered saline (PBS), minced in small pieces and digested with 0.2% collagenase type I at 37°C on a shaker for 2 hr. The resultant soup was centrifuged and the pellet that contained adherent stromal cells was carefully placed on Ficoll solution (Biosera)

Authors' affiliations: ¹Shiraz Institute for Cancer Research, School of Medicine, Shiraz University of Medical Sciences, Shiraz, Iran. ²Department of Veterinary Medicine, Shiraz University, Shiraz, Iran. ³Department of Pathology, Shiraz University of Medical Sciences, Shiraz, Iran. ⁴Department of Immunology, Shiraz University of Medical Sciences, Shiraz, Iran.

Corresponding author and reprints: Abbas Ghaderi PhD, Shiraz Institute for Cancer Research, Shiraz University of Medical Sciences, Shiraz, Iran.

Tel: +98-711-230-3687, Fax: +98-711-230-4952,

E-mail: ghaderia@sums.ac.ir

Accepted for publication: 14 March 2012

Table 1. Summary of osteoarthritis (OA) scores at 12, 16, and 20 weeks.

Group	Cases (n)	Radiological score*		Radiological score*	
		12 weeks	16 weeks	12 weeks	20 weeks
ACLT	5	3	3	3	3
		3	4	3	4
		3	4	2	4
		2	3	3	4
		3	4	2	3
ASCs-treated	5	2	2	3	1
		3	3	3	1
		3	1	2	2
		3	2	4	1
Sham-operated	4	4	3	3	2
		0	0	0	0
		0	0	0	0
		0	0	0	0

ACLT = anterior cruciate ligament transected group treated with medium (without cells); ASCs-treated = adipose-derived stem cell-treated group; Sham-operated = sham operated group. *Based on the grading system proposed by Kellgren et al.,⁸ OA has been divided into five grades: 0 (none), 1 (doubtful), 2 (minimal), 3 (moderate), and 4 (severe).

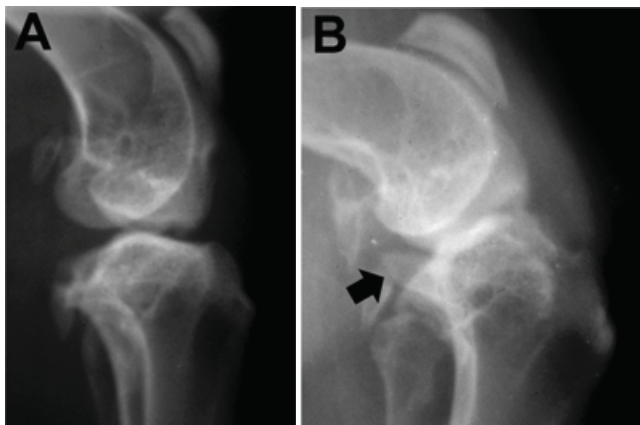


Figure 1. X-ray (lateral view) of stifle joint in a control group rabbit at 12 weeks (A) and 20 weeks after surgery (B). Severe arthritic changes including large osteophyte (black arrow) and deformity of articular surface are visible, especially at 20 weeks.

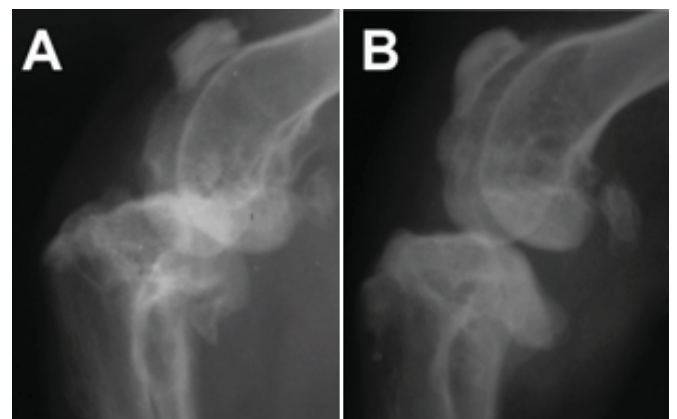


Figure 2. Radiographs (lateral view) of stifle joint in a rabbit from the ASCs-treated group at 12 weeks (A) and 20 weeks (B) after surgery. Radiological signs of osteoarthritis (OA) including subchondral bone sclerosis, osteophytosis and deformities of the bone ends are evident in the 12th week. These features clearly decreased at 20 weeks.

and centrifuged again. The second layer, stromal vascular fraction (SVF), was transferred into a tube and washed with PBS. The SVF pellet was resuspended in DMEM culture medium (Gibco) that contained 10% fetal bovine serum (Gibco) and 1% penicillin/streptomycin (Biosera). Non-adherent cells were discarded after culture for 24 hr. The adherent cells were cultured by changing the medium every four days and harvested at passage 3 after approximately 30 days of culture.

Surgical induction of OA

We performed anterior cruciate ligament transection (ACLT) on 20 adult New Zealand white rabbits. Under anesthesia induced by intramuscular administration of 50 mg/kg of ketamine (Alfasan; Woerden, Holland) and 10 mg/kg of xylazine (Rompun, Bayer AG, Leverkusen), the left leg was shaved, disinfected, and a paramedial surgical approach used. The patella was dislocated laterally and the knee placed in full flexion, after which the ACL was exposed and the ligament cut. The joint capsule and subcutaneous tissue were closed using a 4-0 polydioxanone suture (PDS*II,

Ethicon, Inc.). The skin was closed with 2-0 silk (Supa, Iran). We performed arthrotomy on the right knees of the rabbits, but not transection of the ACL. During the first 3 days after surgery, rabbits received analgesic (Flunixin, Razak Laboratories, Tehran, Iran) and antibiotic (penicillin, Zakaria Laboratory, Tabriz, Iran). All animals were individually maintained in separate cages and allowed to be freely active for 12 weeks.

Transplantation of ASCs

After 12 weeks, rabbits were randomly divided into the following three groups according to the subsequent intra-articular injections which they received. Rabbits in the cell-treated group (10 rabbits) were injected intra-articularly in the ACLT knee with approximately 1×10^6 cells suspended in 1 mL of medium. Rabbits in the control group (10 rabbits) were injected on the same schedule with 1 mL of medium without cells. The sham-operated group (8 rabbits) received no treatment. Intra-articular injections were performed under sterile conditions into the medial compartment of the operated joints. All rabbits were returned to their cages and al-

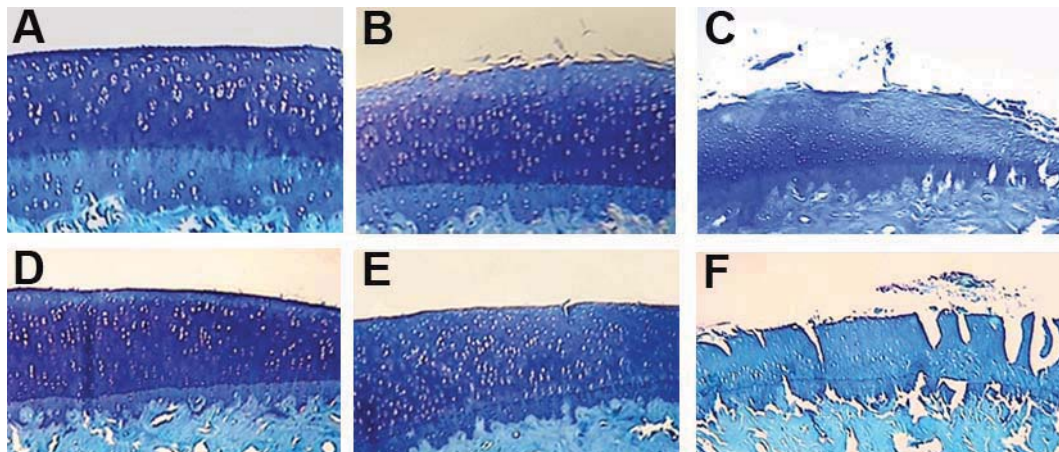


Figure 3. Histopathological evaluation of articular cartilage at 16 (A-C) and 20 (D-F) weeks after surgery (toluidine blue staining, magnification: 40×). (A, D) Sham operated group with normal cartilage. (B, E) ASCs-treated group. The quality of cartilage improves over time in the experiment. The tissue has better structure, thickness, and surface regularity compared to the untreated cartilages. Cartilage matrix consistently well-stained with toluidine blue. (C, F) ACLT group. Tissues clearly show loss of cartilage, with cleft extending to the middle and deep zones, and chondrocyte hypocellularity.

lowed unrestricted cage activity until sacrificed. Animals were euthanized at 16 weeks (5 rabbits in each group) and at 20 weeks (5 rabbits in each group) after surgery. For the sham group, samples were randomly taken from the untreated right knees of the rabbits in both groups: two from the cell-treated group and two from the control group at weeks 16 and 20 after surgery. Animals were sacrificed by an intravenous lethal dose of thiopentone (Nesdonal; Specia Rhône-Poulenc, Paris, France).

Radiological evaluation

Anteroposterior and lateral radiographs of the knee joints were obtained at weeks 12, 16, and 20 after surgery. Radiographs were performed in the Department of Diagnostic Radiology at the School of Veterinary Medicine, Shiraz University. The X-ray device used had the following characteristics: Toshiba DC.12m Japan, 42 kV, 250 mA, 32 ms, and 80 cm film-focus distance. The radiographs were scored according to a grading system proposed previously by Kellgren et al.⁸ This system was based on radiological features that included narrowing of the joint space, presence of osteophytes, sclerosis of the subchondral bone, and deformity of the bone ends. According to the results of the radiographs, we classified OA into five grades of: 0 (none), 1 (doubtful), 2 (minimal), 3 (moderate), and 4 (severe). The radiographs were scored by two independent readers blinded to all data regarding the rabbits.

Histological examination

After rabbits were sacrificed, their joint surfaces were grossly examined. Distal femurs and proximal tibias were excised, with the knee joints intact. After fixation and decalcification, the specimens were cut into four pieces. All pieces were embedded in paraffin, microtomed for 5 μ L thickness and stained with hematoxylin and eosin, toluidine blue, and Safranin-O. Twelve slices for the distal femora and 12 slices for the proximal tibia plateau were analyzed. The severity of OA was graded as described by Mankin et al.⁹ In this system, a higher score indicates more severe damage.

Statistical analysis

All data were presented as mean \pm SD. Statistical analysis was performed using SPSS software version 15. The Kruskal-Wallis test was used to test for significant differences among groups and

pairwise comparison was performed using the Mann-Whitney test with Bonferroni correction. Differences were considered significant at $P < 0.016$.

Results

Radiographic findings

The data in Table 1 show radiological results at weeks 12, 16, and 20 after surgery. At 12 weeks after surgery OA changes that included marginal osteophytes, narrowing of the joint space, and subchondral bone sclerosis were observed in all joints subjected to ACLT. After 16 weeks, the OA score reduced slightly in three of the five cell-treated groups. The remaining two cell-treated joints remained unchanged compared with 12 weeks. In the control group, the OA score progressed during the follow-up period.

At 20 weeks in the ASC-treated group, the radiological score for OA clearly decreased compared with the results from 12 weeks. However, the scores for the control knees increased (Figures 1A, 1B, 2A, and 2B).

Gross findings

In the control group all knees exhibited typical changes of OA with marginal osteophytes, erosion and fibrillation of the articular cartilage, particularly in the medial femoral condyles. There were more extensive lesions noted at 20 weeks compared with 16 weeks. In the cell-treated group, the articular cartilage exhibited a good gross appearance particularly at 20 weeks. Articular cartilage in the sham operated group was grossly normal with a glistening, consistent, and smooth surface.

Histology findings

Articular cartilage in the control group showed varying degrees of degenerative changes. Pathological changes of OA that included irregularity of the articular surface, superficial fissures which extended to the middle and deep layers, and loss of proteoglycan staining were clearly visible in all joints at 16 and 20 weeks after surgery. Obvious hypocellularity was noted, especially at 20 weeks (Figures 3C and F). At 16 weeks after surgery cartilage tissue in the ASC-treated group showed mild surface irregularity, diffuse hypercellularity and clustering with moderate reduction in metachro-

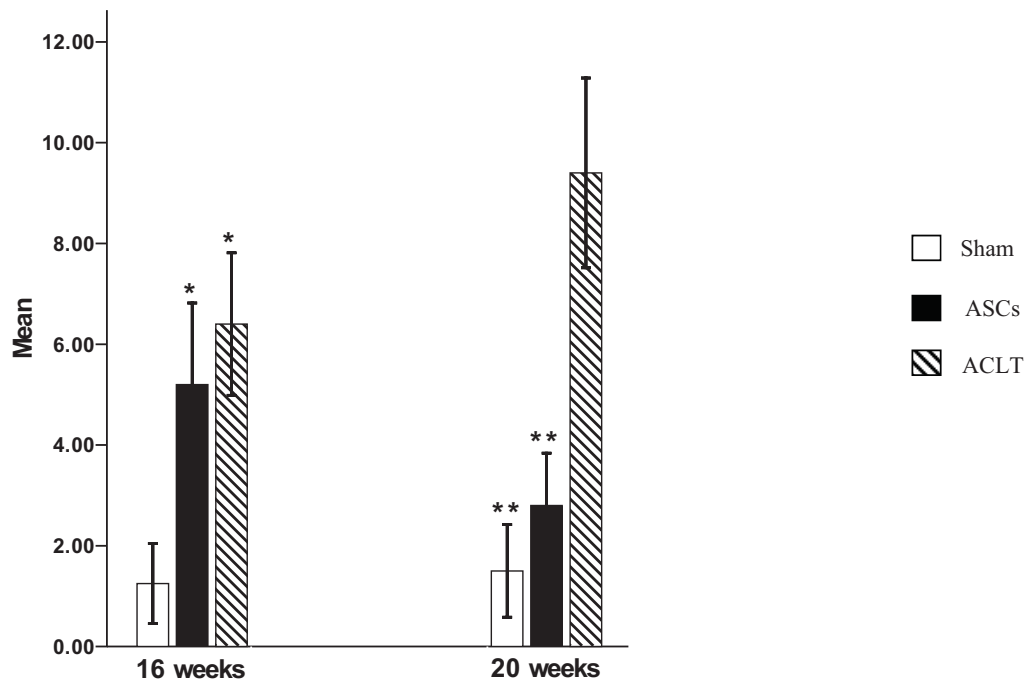


Figure 4. Results of histologic quantification according to the Mankin scale. Data are based on mean \pm SD. * $P < 0.016$ compared to the sham group. ** $P < 0.016$ compared to the OA group.

matic staining (Figure 3B). At 20 weeks, articular cartilage in the cell-treated group showed better condition when compared with 16 weeks (Figure 3E). Articular cartilage in the sham-operated group had a normal histological appearance at 16 and 20 weeks (Figures 3A and D).

Histological quantification by the Mankin scoring system is shown in Figure 4. At 16 weeks after surgery significant differences were found between the sham (1.25 ± 0.50) and both the control (6.4 ± 1.14 , $P = 0.01$) and cell-treated groups (5.2 ± 1.30 , $P = 0.01$), however, there was no significant difference between the cell-treated and control groups. At 20 weeks after surgery, the Mankin score for the ASC-treated group (2.8 ± 0.83) was significantly lower than the control group (9.4 ± 1.51 , $P = 0.008$) but did not differ significantly from the sham group (1.5 ± 0.57). A significant difference was observed between the sham and control groups ($P = 0.01$).

Discussion

OA is the major chronic disease leading to musculoskeletal morbidity and functional loss.¹⁰ The etiology of OA is not completely understood; however, trauma, age, and genetics have been considered as risk factors.¹¹ Numerous animal models of OA have been used to provide the nearest model comparable to human OA. The ACLT model is a surgically induced animal model that has been extensively used to study OA and its treatment.^{12–19} Previous studies have proven that 8–12 weeks after ACLT, the knee joint shows all signs of OA with cartilaginous damage and osteophytes in rabbits.^{12,14,20}

Radiology is one of the most commonly used methods for evaluation of clinical modifications in the musculoskeletal system.²¹ In the current study, radiological assessments have also confirmed OA changes that included subchondral bone remodeling, loss of joint space, and marginal osteophytosis in all joints subjected to

ACLT 12 weeks after surgery.

Conventional therapy for OA includes medication, nutritional supplements, and total surgical replacement of damaged cartilage.^{22–27} In recent years following the isolation of MSCs and access to a sufficient quantity of these clinically potential cells for regenerative medicine, more options have been added to the treatment of several human chronic degenerative diseases, in particular OA.^{11,28,29}

ASCs can be isolated from any organ that has a limited amount of adipose tissue, and is easy to be cultured and expanded. Therefore obtaining ASCs compared to those derived from bone marrow is a less aggressive procedure that is quantitatively advantageous.^{30–32} The plasticity of MSCs, particularly those isolated from adipose tissue, bone, cartilage, and even hepatocytes have been shown.^{5,33}

In the present study we used scaffold-free allograft ASCs in a rabbit model of OA. Our results indicated that injection of allogeneic ASCs were highly tolerated by the recipient rabbits with no signs of immunological reaction, which was possibly due to the low immunogenicity³⁴ and anti-inflammatory characteristics of ASCs.³⁵ The immunosuppressive effects of ASCs have been reported to be mediated through the secretion of soluble factors such as interleukin (IL)-10, indoleamine 2,3-dioxygenase (IDO), hepatocyte growth factor, TGF- β , prostaglandins, and nitric oxide. These characteristics and their differentiation potential introduce MSCs as a promising cell-based strategy for tissue engineering in autoimmune diseases.³⁶ Here the injection of ASCs have shown clear evidence of reduction in the clinical signs of OA, particularly at 20 weeks after surgery. Radiological, morphological, and histological analyses have shown that results progressively improved during that time.

It has been demonstrated that synthetic scaffolds may increase the capacity of injected MSCs in their clinical applications, however, at the same time successful treatment of patients with scaffold-free MSCs have been reported in this and other studies.^{37,38}

In conclusion, this study provides *in vivo* experimental evidence indicating that intra-articular administration of ASCs obtained from subcutaneous adipose tissue can improve OA lesions. We note that studies with larger numbers of animals conducted over longer periods of time can provide more evidence of the effectiveness of this approach for future strategies for cartilage repair in OA. Because adipose tissue is highly abundant and easy to harvest, they may be considered a more promising alternative to bone marrow as a source of MSCs.³⁹

Acknowledgments

The authors would like to thank Dr. Maryam Ansari for statistical evaluation. This work was supported by a grant from Shiraz Institute for Cancer Research (Grant No. ICR:100-504) and in part by Shiraz University.

References

- Fan H, Hu Y, Zhang C, Li X, Lv R, Qin L, et al. Cartilage regeneration using mesenchymal stem cells and PLGA-gelatin/chondroitin/ hyaluronate hybrid scaffold. *Biomaterials*. 2006; **27**: 4573 – 4580.
- Wakitani S, Goto T, Pineda SJ, Young RG, Mansour JM, Caplan AI, et al. Mesenchymal cell-based repair of large, full-thickness defects of articular cartilage. *J Bone Joint Surg Am*. 1994; **76**: 579 – 592.
- Kruegel Miosge N, Koelling S. The Role of progenitor cells in osteoarthritis. *Curr Rheumatol Rev*. 2008; **4**: 210 – 213.
- Luyten PA. Mesenchymal stem cells in osteoarthritis. *Curr Opin Rheumatol*. 2004; **16**: 599 – 603.
- Pountos I, Jones E, Tzioupis C, McGonagle D, Giannoudis PV. Growing bone and cartilage. The role of mesenchymal stem cells. *J Bone Joint Surg Br*. 2006; **88**: 421 – 426.
- Helder MN, Knippenberg M, Klein-Nulend J, Wuisman PI. Stem cells from adipose tissue allow challenging new concepts for regenerative medicine. *Tissue Eng*. 2007; **13**: 1799 – 1808.
- Strem BM, Hicok KC, Zhu M, Wulur I, Alfonso Z, Schreiber RE, et al. Multipotential differentiation of adipose tissue-derived stem cells. *Keio J Med*. 2005; **54**: 132 – 141.
- Kellgren JH, Lawrence JS. Radiological assessment of rheumatoid arthritis. *Ann Rheum Dis*. 1957; **16**: 485 – 493.
- Mankin HJ, Dorfman H, Lippiello L, Zarins A. Biochemical and metabolic abnormalities in articular cartilage from osteoarthritic human hips. II Correlation of morphology with biochemical and metabolic data. *J Bone Joint Surg*. 1971; **53**: 523 – 537.
- Burnett BP, Levy R, Cole BJ. Metabolic mechanisms in the pathogenesis of osteoarthritis. *J Knee Surg*. 2006; **19**: 191 – 197.
- Chen FH, Tuan RS. Mesenchymal stem cells in arthritic diseases. *Arthritis Res Ther*. 2008; **10**: 223 – 234.
- Grigolo B, Lisignoli G, Desando G, Cavallo C, Marconi E, Tschon M, et al. Osteoarthritis treated with mesenchymal stem cells on hyaluronan-based scaffold in rabbit. *Tissue Eng Part C Methods*. 2009; **15**: 647 – 658.
- Bilgili H, Atay OA, Captug O, Korkusuz P, Doral MN. Treatment of osteoarthritis with sodium hyaluronate: an experimental study on rabbits. *Medycyna Wet*. 2008; **64**: 175 – 178.
- Jean YH, Wen ZH, Chang YC, Lee HS, Hsieh SP, Wu CT, et al. Hyaluronic acid attenuates osteoarthritis development in the anterior cruciate ligament-transected knee: association with excitatory amino acid release in the joint dialysate. *J Orthop Res*. 2006; **24**: 1052 – 1061.
- Shikhman AR, Amiel D, D'Lima D, Hwang SB, Hu C, Xu A, et al. Chondroprotective activity of N acetylglucosamine in rabbits with experimental osteoarthritis. *Ann Rheum Dis*. 2005; **64**: 89 – 94.
- Batiste DL, Kirkley A, Laverty S, Thain LM, Spouge AR, Holdsworth DW. *Ex vivo* characterization of articular cartilage and bone lesions in a rabbit ACL transection model of osteoarthritis using MRI and micro-CT. *Osteoarthritis Cartilage*. 2004; **12**: 986 – 996.
- Batiste DL, Kirkley A, Laverty S, Thain LM, Spouge AR, Gati JS, et al. High-resolution MRI and micro-CT in an *ex vivo* rabbit anterior cruciate ligament transection model of osteoarthritis. *Osteoarthritis Cartilage*. 2004; **12**: 614 – 626.
- Papaioannou N, Krallis N, Triantafillopoulos I, Khaldi L, Dontas I, Lyritis G. Optimal timing of research after anterior cruciate ligament resection in rabbits. *Contemp Top Lab Anim Sci*. 2004; **43**: 22 – 27.
- Hongbin W, Jingyuan D, Linyun C, Yuming D. Carboxymethylated chitin reduces MMP-1 expression in rabbit ACLT osteoarthritic cartilage. *Ann Rheum Dis*. 2004; **63**: 369 – 372.
- Hefli FL, Kress A, Fasel J, Morscher EW. Healing of the transected anterior cruciate ligament in the rabbit. *J Bone Joint Surg Am*. 1991; **73**: 373 – 383.
- Torelli SR, Rahal SC, Volpi RS, Yamashita S, Mamprim MJ, Crocci AJ. Radiography, computed tomography, and magnetic resonance imaging at 0.5 Tesla of mechanically induced osteoarthritis in rabbit knees. *Braz J Med Biol Res*. 2004; **37**: 493 – 501.
- Creamer P, Hunt M, Dieppe P. Pain mechanisms in osteoarthritis of the knee: effect of intraarticular anesthetic. *J Rheumatol*. 1996; **23**: 1031 – 1036.
- Levy AS, Lohnes J, Sculley S, LeCroy M, Garrett W. Chondral delamination of the knee in soccer players. *Am J Sports Med*. 1996; **24**: 634 – 639.
- Najm WI, Reinsch S, Hoehler F, Tobis JS, Harvey PW. S-adenosyl methionine (SAME) versus celecoxib for the treatment of osteoarthritis symptoms: a double-blind cross-over trial. *BMC Musculoskelet Disord*. 2004; **5**: 6.
- Shikhman AR, Amiel D, D'Lima D, Hwang SB, Hu C, Xu A, et al. Chondroprotective activity of N-acetylglucosamine in rabbits with experimental osteoarthritis. *Ann Rheum Dis*. 2005; **64**: 89 – 94.
- Park YS, Lim SW, Lee IH, Lee TJ, Kim JS, Han JS. Intra-articular injection of a nutritive mixture solution protects articular cartilage from osteoarthritic progression induced by anterior cruciate ligament transection in mature rabbits: a randomized controlled trial. *Arthritis Res Ther*. 2007; **9**: R8.
- Waikakul S, Vanadurongwan V, Bintachitt P. The effects of patellar resurfacing in total knee arthroplasty on position sense: a prospective randomized study. *J Med Assoc Thai*. 2000; **83**: 975 – 982.
- Caplan AI, Dennis JE. Mesenchymal stem cells as trophic mediators. *J Cell Biochem*. 2006; **98**: 1076 – 1084.
- Ringe J, Sittinger M. Tissue engineering in the rheumatic diseases. *Arthritis Res Ther*. 2009; **11**: 211.
- Muschler GF, Nitto H, Boehm CA, Easley KA. Age- and gender-related changes in the cellularity of human bone marrow and the prevalence of osteoblastic progenitors. *J Orthop Res*. 2001; **19**: 117 – 125.
- Banfi A, Bianchi G, Galotto M, Cancedda R, Quarto R. Bone marrow stromal damage after chemo/radiotherapy: occurrence, consequences and possibilities of treatment. *Leuk Lymphoma*. 2001; **42**: 863 – 870.
- Banfi A, Podesta M, Fazzuoli L, Sertoli MR, Venturini M, Santini G, et al. High-dose chemotherapy shows a dose-dependent toxicity to bone marrow osteoprogenitors: a mechanism for post-bone marrow transplantation osteopenia. *Cancer*. 2001; **92**: 2419 – 2428.
- Liu W, Cui L, Cao Y. Recent advances in tissue engineering of cartilage, bone, and tendon. *Curr Opin Orthop*. 2004; **15**: 364 – 368.
- Le Blanc K, Ringden O. Immunomodulation by mesenchymal stem cells and clinical experience. *J Intern Med*. 2007; **262**: 509 – 525.
- Uccelli A, Pistoia V, Moretta L. Mesenchymal stem cells: a new strategy for immunosuppression? *Trends Immunol*. 2007; **28**: 219 – 226.
- Dazzi F, van Laar JM, Cope A, Tyndall A. Cell therapy for autoimmune diseases. *Arthritis Res Ther*. 2007; **9**: 206.
- Lee KB, Hui JH, Song IC, Ardany L, Lee EH. Injectable mesenchymal stem cell therapy for large cartilage defects—A Porcine Model. *Stem Cells*. 2007; **25**: 2964 – 2971.
- Murphy JM, Fink DJ, Hunziker EB, Barry FP. Stem cell therapy in a caprine model of osteoarthritis. *Arthritis Rheum*. 2003; **48**: 3464 – 3474.
- Zuk PA, Zhu M, Ashjian P, De Ugarte DA, Huang JI, Mizuno H, et al. Human adipose tissue is a source of multipotent stem cells. *Mol Biol Cell*. 2002; **13**: 4279 – 4295.