

## Case Report

# Mid-trimester Hyperechogenic Bowel in a Fetus of Turkish Origin Carrying a Rarely seen Mutation of Cystic Fibrosis

Mert Kazandi MD<sup>1</sup>, Volkan Turan MD<sup>•1</sup>, Gülsah Selvi Demirtas MD<sup>1</sup>, Fuat Akercan MD<sup>1</sup>, Ayca Aykut MD<sup>2</sup>, Ferda Ozkinay MD<sup>2</sup>

## Abstract

Cystic fibrosis (CF) is one of the most common severe autosomal recessive genetic disorders, characterized primarily by chronic obstructive lung disease and maldigestion disorder. The disease is caused by mutations in the CF transmembrane conductance regulator (CFTR) gene. Here we present a case of a fetus with hyperechogenic bowel, in which compound heterozygosity was established for the mutations p.Ile1000fsX1001 and p.Asp110His subsequent to amniocentesis. The mutations were most likely disease-causing, and pregnancy was terminated.

**Keywords:** Amniocentesis, cystic fibrosis, hyperechogenic bowel

**Cite this article as:** Kazandi M, Turan V, Demirtas GS, Akercan F, Aykut A, Ozkinay F. Mid-trimester hyperechogenic bowel in a fetus of Turkish origin carrying a rarely seen mutation of cystic fibrosis. *Arch Iran Med.* 2012; **15**(7): 449 – 451.

## Introduction

Fetal hyperechogenic bowel refers to the increased echogenicity or brightness of the fetal bowel noted on second trimester sonographic examination. First identified by Nyberg and Persutte in 1990,<sup>1,2</sup> it is a relatively common finding with uncertain clinical significance. Echogenic bowel is diagnosed in 0.2% to 1.8% of all second-trimester ultrasounds.<sup>3,4</sup> It is associated with normal fetuses, those with aneuploidy, intrauterine growth retardation (IUGR), congenital viral infections, and cystic fibrosis (CF). The association of echogenic bowel with aneuploidy, especially trisomy 21, has been demonstrated in several studies.<sup>5,6</sup> A detailed ultrasound of the fetus should be performed, and an amniocentesis for karyotype, evidence of cytomegalovirus (CMV), toxoplasmosis, and parvovirus infections should be recommended. Additionally, maternal serologic testing (IgG and IgM) of recent CMV and toxoplasmosis should also be performed.

Hyperechogenic fetal bowel is also considered to be suggestive of CF. The risk for CF in fetuses with echogenic bowel has been extensively studied.<sup>7-9</sup> Given the increased risk of CF in a hyperechogenic fetal bowel, the analysis of common CF mutations is routinely offered to parents. The most prevalent mutation is *delta* F508, which occurs in 70% of patients with CF.<sup>7</sup> New mutations are routinely published, with over 1200 currently in the CF database. The incidence rate of CF in fetuses with mid-trimester hyperechogenic bowel is 5%. Once the most frequent mutations have been accounted for, rarer mutations should be investigated.<sup>10</sup>

In this study we present a fetus with hyperechogenic bowel carrying a rarely seen compound heterozygous mutation of p.Ile1000fsX1001 and p.Asp110His in the CFTR gene.

## Case Report

A 29-year-old gravida 2 para 1 female with no previous medical history was referred to our unit at 18 weeks of gestation for second trimester screening. Isolated hyperechogenic bowel was detected by ultrasonography (Figure 1). Maternal serum screening for infections were normal; fetal karyotype analysis and fetal DNA-analysis for CFTR-mutations were offered. The fetal karyotype was 46,XY. After all coding regions of the CFTR gene were sequenced, DNA analysis revealed compound heterozygosity for the mutation p.Ile1000fsX1001 where the c.3130delA mutation was identified in exon 17 of the CFTR gene in the heterozygous state, which caused a frameshift that resulted in a premature stop codon on position 1001. Also p.Asp110His mutation was identified where the c.460G > C mutation was seen in exon 4 of the CFTR gene in the heterozygous state and altered aspartic acid into a histidine on amino acid position 110 of the resulting protein in the CFTR gene. Both mutations have previously been described in CF patients postnatally, therefore the fetus was considered to be affected. Per medical recommendation, the pregnancy was terminated. After a year, she became pregnant again. Amniocentesis was performed at the 16<sup>th</sup> week of gestation. The result was consistent with Asp110His heterozygous mutation. The fetus was a carrier in terms of genotype, but the phenotype was normal. At the 38<sup>th</sup> week of gestation an elective cesarean section was performed and a 2750 g healthy male was delivered.

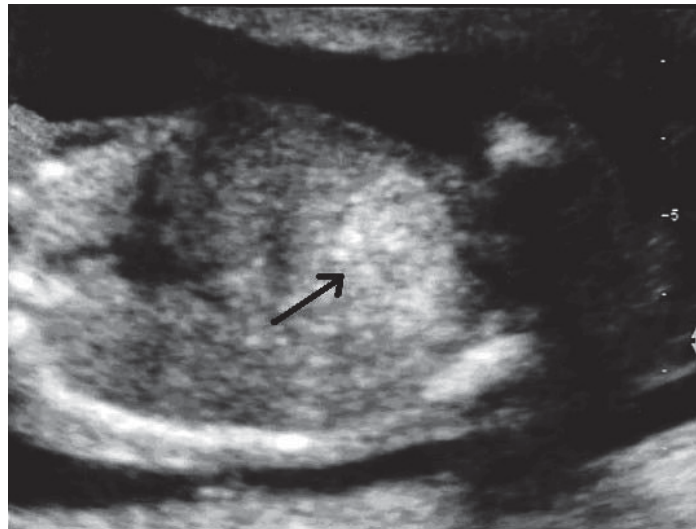
## Discussion

Prenatal diagnosis of CF should include consideration of ultrasonographic findings and DNA mutation analysis. Hyperechogenic fetal bowel in the second or third trimester of pregnancy is a weak marker for various underlying conditions that can be benign or pathological. In previous reports, the incidence of CF in fetuses with hyperechogenic fetal bowel varies between 0% – 60%.<sup>11,12</sup> The recommended management strategies of isolated hyperechogenic bowel are summarized in Table 1.

**Authors' Affiliations:** <sup>1</sup>Department of Obstetrics and Gynecology, Ege University Faculty of Medicine, Izmir, Turkey, <sup>2</sup>Department of Genetics, Ege University Faculty of Medicine, Izmir, Turkey.

**Corresponding author and reprints:** Volkan Turan MD, Department of Gynecology and Obstetrics, Ege University, Izmir, Postal code: 35100, Bornova, Turkey. Tel: 905059113736, E-mail: volkanturan@yahoo.com.

Accepted for publication: 21 December 2011



**Figure 1.** Ultrasonographic view of hyperechogenic fetal bowel (black arrow).

**Table 1.** Management of isolated hyperechogenic bowel.

History of bleeding.
Calculate new risk for Down Syndrome.
If increased risk (1: 250) offer amniocentesis. If performed, save fluid for microbiological analysis (PCR and culture).
Test maternal blood for common prenatal infections.
Cystic fibrosis (CF) risk. Consider genetic counseling and offer parental testing. If parents are carriers, offer amniocentesis for DNA.
IUGR risk: Offer growth scan at approximately 28–32 weeks gestation.

With the increasing demand for prenatal screening of pregnancies from the general population, an increasing number of CF patients are diagnosed in utero in the absence of a family history of CF, either after preconceptional genetic screening of the parents or after routine fetal ultrasound results of CF-associated findings such as fetal bowel hyperechogenicity. Fetal bowel hyperechogenicity is defined as an echogenicity of a fetal bowel loop similar to or greater than the fetal iliac crest hyperechogenicity.<sup>13</sup> Fetal hyperechogenic bowel originates from either the bowel wall or from the intraluminal content. It remains a matter of debate and is often a challenge for genetic counseling, particularly if found after 18 weeks of gestation. In a study of 209 pregnancies with fetal bowel hyperechogenicity, 68% had a subsequent normal outcome and 3.3% had CF. The other cases had chromosomal abnormalities (5%), gastrointestinal malformations (8%), fetal infections (4%), or unexplained fetal death (13%).<sup>11,14</sup> A French study reported similar data (3%) in terms of CF after reviewing 662 cases of hyperechogenic bowel.<sup>5</sup>

The risk for CF in fetuses with echogenic bowels has been extensively studied. CFTR protein multifunctioning leads to the dehydration of mucus secretions that become viscous, obstruct the bowel lumen, and cause meconium ileus.<sup>7</sup> More than a thousand other mutations have also been discovered in the CFTR gene. These mutations in the CFTR gene make it impossible to detect all mutations by simple routine screening. Extended CFTR gene analysis should be performed using sequence analysis of all coding regions and intron-exon boundaries of the CFTR gene.

Both mutations in this case report have been previously described in CF patients with a broad spectrum of disease severity and are thus most likely-disease-causing mutations. The cases that have previously reported the p.Asp110His mutation were prone to severe

salt loss upon exposure to heat or exercise, were overweight and had normal lung function.<sup>15</sup> There have been several reports about a mild CF phenotype of isolated hypotonic dehydration associated with specific CFTR mutations, including p.Asp110His.<sup>16–18</sup> An Iranian study on males with congenital bilateral absence of the vas deferens (CVDA) showed the c.3130delA mutation with a frequency of 2.9%.<sup>19</sup>

In the present study, following termination of pregnancy, paternal and maternal mutations were detected in molecular studies. A paternal c.3130delA mutation in exon 17A of the CFTR gene in the heterozygous state and a maternal c.460G > C mutation in exon 4 of the CFTR gene, which was also in the heterozygous state were shown (both were carriers).

Management of fetal hyperechogenic bowel includes establishing other markers of chromosome abnormalities and fetal biometry. If there are any other markers of chromosome abnormality it is important to suspect possible chromosome abnormalities such as trisomy 21.

In conclusion, we have identified the mutations in the CFTR gene associated with CF prenatally. Although hyperechogenic fetal bowel in the second or third trimester of pregnancy is a weak marker for various underlying conditions, the clinician should be cautious in terms of CF or chromosome abnormalities.

**Conflict of Interest:** There is no conflict of interest declared in this study.

## References

1. Nyberg DA, Resta RG, Luthy DA, Hickok DE, Mahony BS, Hirsch JH. Prenatal sonographic findings of Down syndrome: review of 94 cases. *Obstet Gynecol.* 1990; **76**: 370–377.

2. Persutte WH. Second trimester hyperechogenicity in the lower abdomen of two fetuses with trisomy 21: is there a correlation? *J Clin Ultrasound*. 1990; **18**: 425 – 428.
3. Dicke JM, Crane JP. Sonographically detected hyperechoic fetal bowel: significance and implications for pregnancy management. *Obstet Gynecol*. 1992; **80(5)**: 778 – 782.
4. Jackson CR, Orford J, Minutillo C, Dickinson JE. Dilated and echogenic fetal bowel and postnatal outcomes: a surgical perspective. Case series and literature review. *Eur J Pediatr Surg*. 2010; **20(3)**: 191 – 193.
5. Simon-Bouy B, Satre V, Ferec C, Malinge MC, Girodon E, Denamur E, et al. Hyperechogenic fetal bowel: a large French collaborative study of 682 cases. *Am J Med Genet A*. 2003; **121**: 209 – 213.
6. Marcus-Soekarman D, Offermans J, Van den Ouweland AM, Mulder AL, Muntjewerff N, Vossen M, et al. Hyperechogenic fetal bowel: counseling difficulties. *Eur J Med Genet*. 2005; **48**: 421 – 425.
7. Sepulveda W, Leung KY, Robertson ME, Kay E, Mayall ES, Fisk NM. Prevalence of cystic fibrosis mutations in pregnancies with fetal echogenic bowel. *Obstet Gynecol*. 1996; **87**: 103 – 106.
8. Scotet V, Duguéperoux I, Audrézet MP, Blayau M, Boisseau P, Journel H, et al. Prenatal diagnosis of cystic fibrosis: the 18-year experience of Brittany (western France). *Prenat Diagn*. 2008; **28(3)**: 197 – 202.
9. Scotet V, Duguéperoux I, Audrézet MP, Audebert-Bellanger S, Muller M, Blayau M, et al. Focus on cystic fibrosis and other disorders evidenced in fetuses with sonographic finding of echogenic bowel: 16-year report from Brittany, France. *Am J Obstet Gynecol*. 2010; **203**: 592.
10. Yamamoto M, Molina-Gomes D, Girodon-Boulant E, Moulis M, Leroy B, Simon-Bouy B, et al. Mid-trimester hyperechogenic bowel in a fetus of Japanese origin carrying a new mutation of CFTR gene (L548Q). *Prenat Diagn*. 2006; **26(1)**: 6 – 8.
11. Muller F, Dommergues M, Aubry MC, Simon-Bouy B, Gautier E, Oury JF, et al. Hyperechogenic fetal bowel: an ultrasonographic marker for adverse fetal and neonatal outcome. *Am J Obstet Gynecol*. 1995; **173(2)**: 508 – 513.
12. Boue A, Muller F, Nezelov C, et al. Prenatal diagnosis in 200 pregnancies with a 1-in-4 risk of cystic fibrosis. *Human Genet*. 1986; **74(3)**: 288 – 297.
13. Slotnick RN, Abuhamad AZ. Prognostic implications of fetal echogenic bowel. *Lancet*. 1996; **347**: 85 – 87.
14. Muller F, Dommergues M, Simon-Bouy B, Ferec C, Oury JF, Aubry MC, et al. Cystic fibrosis screening: a fetus with hyperechogenic bowel may be the index case. *J Med Genet*. 1998; **35(8)**: 657 – 660.
15. Stanke F, Ballmann M, Bronsveld I, Dörk T, Gallati S, Laabs U, et al. Diversity of the basic defect of homozygous CFTR mutation genotypes in humans. *J Med Genet*. 2008; **45(1)**: 47 – 54.
16. Leoni GB, Pitzalis S, Podda R, et al. A specific cystic fibrosis mutation (T338I) associated with the phenotype of isolated hypotonic dehydration. *J Pediatr*. 1995; **127(2)**: 281 – 283.
17. Padoan R, Bassotti A, Seia M, et al. A novel missense mutation (D110E) in exon 4 of CFTR (ABCC7) in a CF infant presenting with hypochloremic metabolic alkalosis. *Human Mutat*. 2000; **15(5)**: 485.
18. Weller F, Wiebicke W, Tummeler B. Turkish infant with hyponatremia and metabolic alkalosis as the sole manifestations of a mild form of cystic fibrosis (mutation D110H). *Klin Padiatr*. 2000; **212**: 41 – 43.
19. Alibakhshi R, Kianishirazi R, Cassiman JJ, Zamani M, Cuppens H. Analysis of the CFTR gene in Iranian cystic fibrosis patients: identification of eight novel mutations. *J Cyst Fibros*. 2008; **7(2)**: 102 – 109.