

## Photoclinic

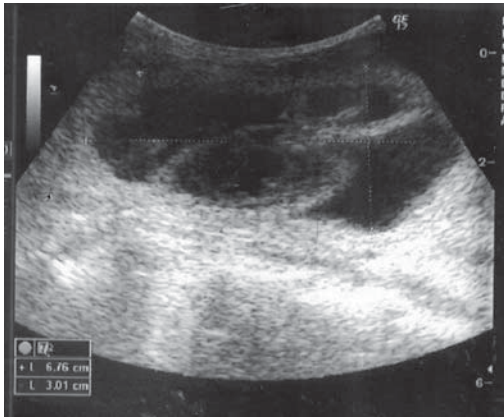


Figure 1a

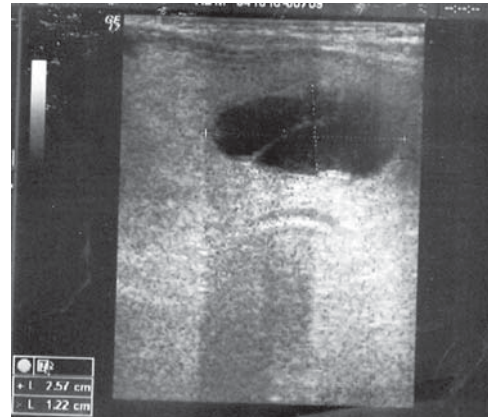


Figure 1b

Figure 1a and 1b) Sonography of the neck mass.



Figure 2. Macroscopic view of the thyroidectomy specimen.

Cite the article as: Geramizadeh B, Akbarzadeh E, Nikeghbalian S. Photoclinic. *Arch Iran Med.* 2012; **15(6)**: 389 – 390.

A 49-year-old man with chronic renal failure on hemodialysis for four years presented with a large, rapidly growing neck mass that was associated with dysphagia and hoarseness. Laboratory investigation was notable for elevated blood urea nitrogen (BUN) and creatinine, and normal thyroid function.

Sonography of the neck mass showed an enlarged thyroid with

multiple hypoechoic mass lesions in both lobes (Figures 1a and 1b).

The patient underwent a subtotal thyroidectomy. The resected thyroid was markedly enlarged. According to the pathology analysis, the right lobe showed a large cystic mass (5 × 5 cm); the left lobe had narrow cystic spaces with intervening tan and solid areas (Figure 2).

**Bitá Geramizadeh MD<sup>1,2</sup>, Elahe Akbarzadeh MD<sup>2</sup>, Saman Nikeghbalian MD<sup>3</sup>**

**Authors' affiliations:** <sup>1</sup>Transplant Research Center, Shiraz University of Medical Sciences, Shiraz, Iran, <sup>2</sup>Department of Pathology, Shiraz University of Medical Sciences, Shiraz, Iran, <sup>3</sup>Department of Surgery, Shiraz University of Medical Sciences, Shiraz, Iran.

**Corresponding author and reprints:** Bitá Geramizadeh MD, Department of Pathology, Transplant Research Center, Shiraz University of Medical Sciences, P.O. Box 71345-1864, Shiraz, Iran. Telefax: +98-711-647-3105, E-mail: geramib@sums.ac.ir

Accepted for publication: 23 November 2011

**What is your Diagnosis?**  
See the next page for diagnosis

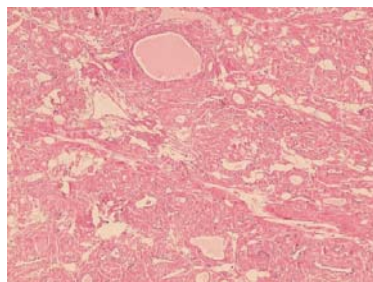


Figure 3a

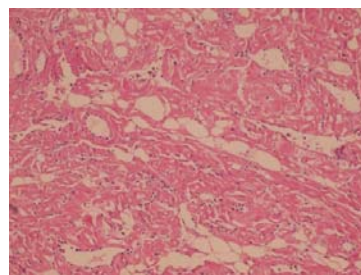
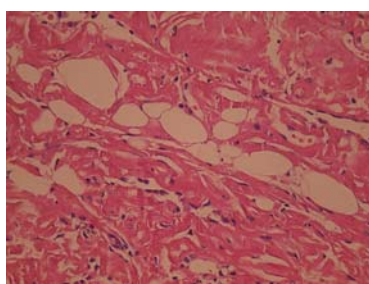


Figure 3b

**Figure 3.** Sections from the thyroid mass show marked deposition of hyalinized material in the inter- and perifollicular areas (a: H&E, 100 $\times$ , b: H&E, 250 $\times$ ).



**Figure 4.** Fat deposit in the amyloid goiter (H&E, 400 $\times$ ).

Microscopic sections from the thyroid showed eosinophilic amorphous deposits in the inter- and perifollicular areas, causing displacement and compression of the thyroid follicles (Figures 3a and 3b). Rare foci of mature adipose tissue were seen admixed with the above-mentioned material and thyroid follicles (Figure 4). The deposits were intensely stained with Congo-red and apple-green under polarized light.

All investigations, including endoscopy, colonoscopy, and other imaging studies failed to show any additional organ involvement. The patient had an uneventful postoperative period and left the hospital in good health, to be dialyzed according to his previous schedule.

Amyloid goiter may be associated with either primary or secondary amyloidosis.<sup>1</sup> This entity has been identified in 0.04% of patients with secondary amyloidosis due to chronic infection and other chronic inflammatory processes, such as tuberculosis, rheumatic diseases, Crohn's disease, and familial Mediterranean fever.<sup>2</sup>

Although amyloid deposition can be found in many organs, the clinically apparent enlargement of the thyroid gland due to a widespread amyloid deposit is rare.<sup>3</sup> In patients with amyloid goiter, the enlargement of the gland is usually relatively rapid and occurs over weeks or months.<sup>1</sup> It is occasionally associated with pressure symptoms such as hoarseness, dysphagia, and dysphonia.<sup>4</sup> Most have normal thyroid function tests.<sup>5</sup> Our case also presented with dysphagia and hoarseness secondary to a markedly enlarged thyroid. Definitive diagnosis requires histologic evaluation of the resected thyroid gland, thus a thyroidectomy is the method of choice

for both diagnosis and treatment.<sup>6</sup> Histologic findings include loss of thyroid follicles and an eosinophilic amorphous substance deposited in the intervening hyalinized stroma. Some reports also have shown diffuse fatty infiltration.<sup>7</sup> In our case focal fat deposition was noted.

In conclusion, the diagnosis of amyloid goiter should be considered in any patient with a chronic underlying disease and an enlarging thyroid. It can be the first and only manifestation of systemic amyloidosis, such as in our case, which had chronic renal failure on dialysis that initially manifested with a markedly enlarged thyroid.

## References

- Villamil CF, Massini G, D'Avella J, Cole SR. Amyloid goiter with parathyroid involvement. A case report and review of the literature. *Arch Pathol Lab Medicine*. 2000; **12**: 281 – 283.
- Vanguri VK, Nose V. Transthyretin amyloid goiter in a renal allograft recipient. *Endocr Pathol*. 2008; **19**: 66 – 73.
- Ozdemir BH, Uyar P, Ozdemir FN. Diagnosing amyloid goitre with thyroid aspiration biopsy. *Cytopathology*. 2006; **17**: 262 – 266.
- Kapadia HC, Desai R, Desai I, Parikh N. Amyloid goiter- A case Report. *Indian J Pathol Microbiol*. 2001; **44**: 147 – 148.
- Shai A, Wechsler B, Leenhardt L, Beaufils H, Hoang C, Menegaux F, et al. Amyloid goiter as the initial manifestation of systemic amyloidosis due to FMF with homozygous MEFV mutation. *Thyroid*. 2001; **11**: 394 – 400.
- Siddiqui M, Gertz M, Dean D. Amyloid goiter as a manifestation of primary systemic amyloidosis. *Thyroid*. 2007; **17**: 77 – 80.
- Himmetoglu C, Yamak S, Tazel GG. Diffuse fatty infiltration in amyloid goiter. *Pathol Internat*. 2007; **57**: 449 – 453