

## Case Report

# Tuberous Sclerosis Presented With Polycystic Kidney Disease and Acute Renal Failure

Ahmet Engin Atay MD<sup>1</sup>, Suleyman Ozupekce MD<sup>2</sup>, Halit Akbas PhD<sup>3</sup>, Murat Acar MD<sup>1</sup>, Semir Pasa MD<sup>4</sup>, Memduh Oruc MD<sup>5</sup>

## Abstract

Tuberous sclerosis complex (TSC) is an autosomal dominant disorder characterized by hamartomatous involvement of multiple organs such as the skin, central nervous system, kidneys, lungs, and heart. A linkage has been found with a locus on the long arm of chromosome 9 (9q34) and with a locus on the short arm of chromosome 16 (16p13). TSC has a birth incidence of 1/6000. Children with TSC are almost universally born with normal kidneys, but cystic disease and angiomyolipomas develop with increasing age. Angiomyolipomas, renal cysts, and renal cell carcinoma are classical features of renal involvement in TSC. Renal complications are the most common cause of death in adult TSC patients, thus renal involvement has a crucial importance on the course of this disease. We present a 27-year-old patient previously diagnosed as tuberous sclerosis complex and referred with acute renal failure and polycystic kidney disease.

**Keywords:** Acute renal failure, polycystic kidney disease, tuberous sclerosis

**Cite the article as:** Atay AE, Ozupekce S, Akbas H, Acar M, Pasa S, Oruc M. Tuberous Sclerosis Presented With Polycystic Kidney Disease and Acute Renal Failure. *Arch Iran Med.* 2012; 15(6): 384 – 386.

## Introduction

Tuberous sclerosis complex (TSC), a genetic tumor predisposition syndrome, has a birth incidence of 1/6000 with wide-ranging organ system involvement that includes central nervous system, skin, renal, and lung manifestations.<sup>1</sup> Patients with TSC almost entirely experience renal complications in different stages of the disease and at different severities. Renal angiomyolipomas, cysts, and less frequently renal cell carcinoma are typical features of renal involvement in TSC. Adjacent TSC and PKD1 genes are associated with severe and early onset polycystic phenotype, and account for 2% of TSC patients.<sup>2</sup>

We report the case of a young male with tuberous sclerosis complex who referred to our outpatient clinic with acute renal failure due to dehydration and possible antiepileptic medication-related renal cell injury.

## Case Report

A 27-year-old male patient referred to our outpatient clinic with complaints of nausea, vomiting, fatigue, and intermittent left flank pain. The diagnosis of tuberous sclerosis had been confirmed by clinical and genetic examinations at the age of three years. Molecular analysis revealed a mutation in the TSC-2 gene that localized on the short arm of chromosome 16 (16p13). The presenting symptom was a seizure, and thus antiepileptic therapy was initiated. He had a history of three seizures, all at different ages. Although no epileptic attack had been observed since the age of ten, the

patient continued with prophylactic anticonvulsant therapy. He had characteristic facial angiofibromas and a shagreen patch (Figure 1). Previous ultrasonographic examinations indicated multiple angiomyolipomas, less than 2 cm in diameter in both kidneys.

Nausea and vomiting persisted for two days and gradually increased. He was apparently hypotensive (blood pressure: 70/40 mmHg) and tachycardic (pulse: 116/minute). A mild increase in serum urea and creatinine levels were determined and supportive therapy was initiated. Biochemical abnormalities resolved and symptoms improved on the second day of hospitalization.

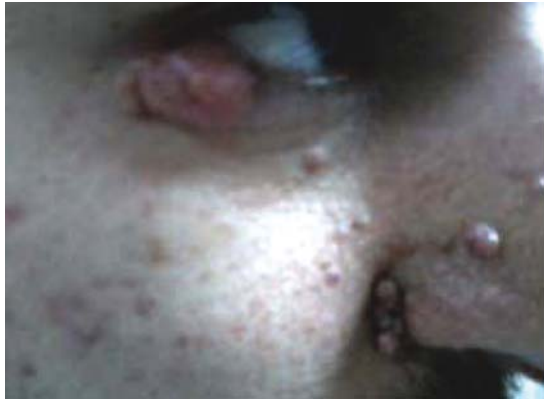The patient underwent a detailed multidisciplinary clinical assessment, however, no apparent abnormality was observed during the respiratory function test, echocardiographic, and thorax tomographic examinations. The glomerular filtration rate was estimated by 24-hour urine creatinine clearance and Cockcroft and Gault formula. A cranial MR imaging study indicated a tuberous formation in the left supratentorial area (Figure 2). Abdominal ultrasonographic examination pointed out renal angiomyolipoma and cyst formation. Both were confirmed by abdominal tomographic examination. Cysts smaller than 1 cm in size, undetectable by ultrasonography, were also observed (Figure 3 and 4). Regular, frequent follow-ups of at least three month intervals were suggested to determine the complications of the disease in its earlier stages. Other family members underwent to molecular and clinical evaluations for the possible presence of TSC.

## Discussion

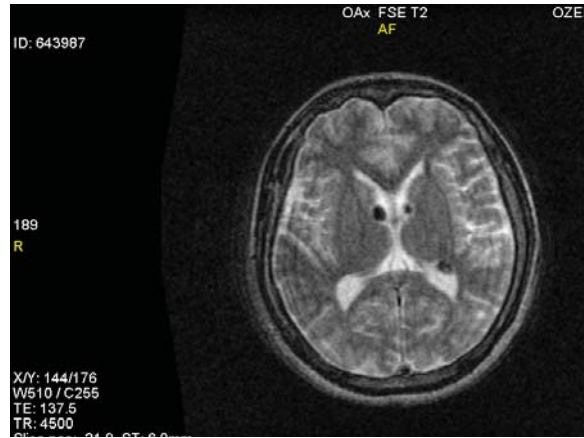
Renal involvement has a vital importance on the course of TSC because of the relentless progression of chronic kidney disease (CKD). Patients with TSC also are at risk for acute kidney injury that can include the use of anticonvulsant and nonsteroidal anti-inflammatory medications as well as rhabdomyolysis and hypoxia, which is induced by prolonged seizures.<sup>3</sup> More than half of the kidney function must be lost before a rise in serum creatinine is detectable.<sup>1</sup> Renal causes of death were second only to the central

**Authors' affiliations:** <sup>1</sup>Department of Internal Medicine, Family Medical Center, Diyarbakir, Turkey. <sup>2</sup>Department of Urology, Family Medical Center, Diyarbakir, Turkey. <sup>3</sup>Department of Medical Biology and Genetics, Medical School of Haran University, Sanliurfa, Turkey. <sup>4</sup>Department of Internal Medicine, Diyarbakir Training Hospital, Diyarbakir, Turkey. <sup>5</sup>Department of Chest Surgery, Diyarbakir Training Hospital, Diyarbakir, Turkey.

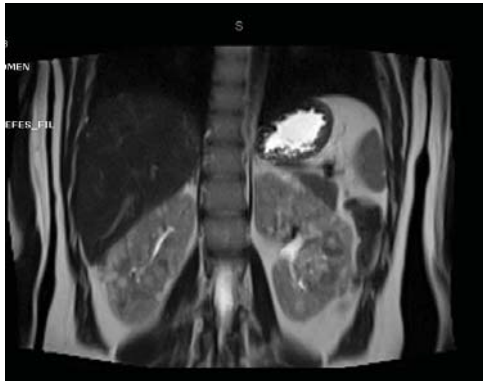
**•Corresponding author and reprints:** Ahmet Engin Atay MD, Family Medical Center, 5 Nisan Mh. Nukhet Coskun Cad. Baglar PTT Yani, Diyarbakir, Turkey, Tel: +90-412-233-0417, Gsm: +90-532-653-6736, E-mail: aeatay@hotmail.com. Accepted for publication: 15 December 2011



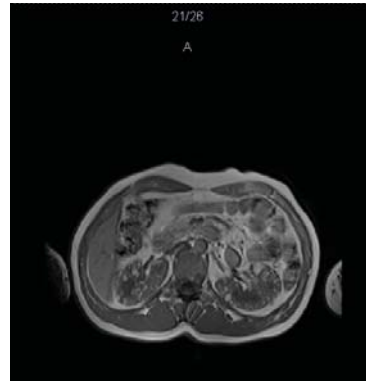
**Figure 1.** Characteristic facial angiofibromas.



**Figure 2.** Tuberosity formation in tuberous sclerosis (TSC).



**Figure 3.** Renal involvement in tuberous sclerosis (TSC).



**Figure 4.** Renal angiomyolipomas seen in tomographic examination.

nervous system, however recently renal complications have been considered as the leading causes of death in patients with TSC.<sup>4,5</sup>

Angiomyolipomas are the prototype of a family of lesions called perivascular epithelioid cell tumors (PEComas). These lesions generally exhibit immunoreactivity for both melanocytic markers as detected by HMB-45 and smooth-muscle markers such as actin and desmin.<sup>1</sup> Angiomyolipomas significantly affect the outcome of TSC because they can invade adjacent normal renal parenchyma, leading to chronic kidney disease. In addition, they can cause aneurysms that may rupture.<sup>6</sup> The risk of hemorrhage from renal angiomyolipomas in patients with TSC varies between 25% and 50% and is related to aneurysm size, with the greatest risk being in aneurysms > 5 mm.<sup>7,8</sup> Ultrasound has been the predominant imaging modality to screen for angiomyolipomas. Currently no imaging methods distinguish between fat-poor angiomyolipomas and carcinomas. Recently the growth rate has been introduced as a possible method to distinguish renal cell carcinoma (RCC) from fat-poor lesions and diagnostic markers for angiomyolipoma.<sup>9</sup> HMB-45 and melanin A are beneficial for differentiating RCC from angiomyolipoma. The incidence of RCC in patients with TSC is similar to that in the general population, with a lifetime risk of 2% to 3%; however, cancer is diagnosed at a younger age in patients with TSC.<sup>10</sup>

The responsible locus of TSC2 and PKD1 lie adjacent to each other at chromosome 16p13.3, suggesting a role for PKD1 in the etiology of renal cystic disease in TSC. Radiologically cystic diseases resemble autosomal dominant polycystic kidney disease (ADPKD).<sup>11</sup> Renal cystic disease can also be microcystic and un-

detectable by imaging studies.<sup>12</sup> Patients with renal cystic disease have a significant risk for nephrolithiasis related to distal tubular dysfunction. This leads to hypocitraturia and hypertension, which responds very well to angiotensin-converting enzyme inhibitors and angiotensin receptor blockers.<sup>6</sup>

Rakowski et al reported that percentages of renal manifestations observed in patients with tuberous sclerosis complex are as follows; angiomyolipomas are 85.4%, cysts are 44.8%, and renal cell carcinomas are 4.2%.<sup>13</sup> Both angiomyolipomas and cysts were significantly more common and more numerous in TSC2 than in TSC1. AML was significantly more common in females than in males.<sup>13</sup> The frequency and number of renal lesions positively correlated with age,<sup>4,14</sup> with an average age at onset of AML of 7.2 years; the age of onset for cysts is 9 years.<sup>15,16</sup> However, they may be present as early as the first year of life or even at birth.<sup>15</sup>

Although optimal surveillance protocols for renal imaging in TSC are not established, Rakowski et al. have recommended a baseline renal ultrasound (USG) before 5 years of age and a repeat every 2–3 years, if results are normal. They recommended yearly ultrasound follow-ups, if angiomyolipomas or cysts were observed. If RCC was suspected, an MRI for re-evaluation and follow-up imaging at six-month intervals was required.<sup>13</sup> The TSC Consensus Conference of 1998 recommended renal ultrasonography every 1–3 years to assess the development or progression of angiomyolipomas.<sup>17</sup> The purpose of serial imaging was to lower the renal complications of TSC, such as aneurysm, rupture, and hemorrhage.<sup>18</sup> Regular follow-up and appropriate therapy are essential to determine renal complications of TSC in the earlier stages and

to overcome the preventable complications including acute renal failure.

## References

1. Siroky BJ, Yin H, Bissler JJ. Clinical and Molecular Insights into Tuberous Sclerosis Complex Renal Disease. *Pediatr Nephrol.* 2010; **467**: 1689 – 1695.
2. Brook-Carter PT, Peral B, Ward CJ, Thompson P, Hughes J, Maheshwar MM, et al. Deletion of the TSC2 and PKD1 genes associated with severe infantile polycystic kidney disease—a contiguous gene syndrome. *Nat Genes.* 1994; **8**: 328 – 332.
3. deChadarevian JP, Legido A, Miles DK, Katsetos CD. Epilepsy, atherosclerosis, myocardial infarction and carbamazepine. *J Child Neurol.* 2003; **18**: 150 – 151.
4. Jozwiak S, Migone N, Ruggieri M. The tuberous sclerosis complex: phakomatoses and hamartoneoplastic syndromes. In: Ruggieri M, Pascual Castroviejo I, Di Rocco C, eds. *Neurocutaneous Disorders*. Vienna: Springer; 2008: 181 – 227.
5. Shepherd CW, Gomez MR, Lie JT. Causes of death in patients with tuberous sclerosis. *Mayo Clin Proc.* 1991; **66**: 792-796.
6. Dixon BP, Hubert JC, Bissler JJ. Tuberous Sclerosis Complex Renal Disease. *Nephron Exp Nephrol.* 2011; **118**: 15 – 20.
7. Kesler OJ, Gillon G, Neuman M, Engelstein D, Winkler H, Baniel j. Management of renal angiomyolipoma: analysis of 15 cases. *Eur Urol.* 1998; **33**: 572 – 575.
8. Yamakada K, Tanaka N, Nakagawa T, Kobayashi S, Yanagawa M, Takeda K. Renal angiomyolipoma: relationships between tumor size, aneurysm formation, and rupture. *Radiology.* 2002; **225**: 78 – 82.
9. Patel U, Simpson E, Kingswood JC, Sagar-Malik AK. Tuberous sclerosis complex. Analysis of growth rates aids differentiation of renal cell carcinoma from atypical or minimal-fat-containing angiomyolipoma. *Clin Radiol.* 2005; **60**: 665 – 673.
10. Crino PB, Nathanson KL, Henske EP. The tuberous sclerosis complex. *N Engl J Med.* 2006; **355**: 1345 – 1356.
11. Torres VE, King BF, Holley KE, Blute ML, Gomez MR. The kidney in tuberous sclerosis. *Adv Nephrol.* 1994; **23**: 43 – 70.
12. Bissler JJ, Siroky BJ, Yin H. Glomerulocystic kidney disease. *Pediatr Nephrol.* 2010; **25**: 2049 – 2059.
13. Rakowski SK, Winterkorn EB, Paul E, Steele DJR, Halpern EF, Thiele EA. Renal manifestations of tuberous sclerosis complex: incidence, prognosis, and predictive factors. *Kidney Int.* 2006; **70**: 1777 – 1782.
14. Cheadle JP, Reeve MP, Sampson JR, Kwiatkowski DJ. Molecular genetic advances in tuberous sclerosis. *Hum Genet.* 2000; **107**: 97 – 114.
15. Ewalt DH, Sheffield E, Sparagena SP. Renal lesion growth in children with tuberous sclerosis complex. *J Urol.* 1998; **160**: 141 – 145.
16. Casper KA, Donnelly LF, Chen B. Tuberous sclerosis complex: renal imaging findings. *Radiology.* 2002; **225**: 451 – 456.
17. Yates JRW. Tuberous sclerosis. *Eur J Hum Genet.* 2006; **14**: 1065 – 1073.
18. Franz DN, Bissler JJ, McCormack FX. Tuberous Sclerosis Complex: neurological, renal and pulmonary manifestations. *Neuropediatrics.* 2010; **41**: 199 – 208.



Sunrise, Taleqan, near Tehran (Photo by M.H. Azizi MD, 2011)