

Case Report

A Rare Case of Perforated Meckel's Diverticulum Presenting as a Gastrointestinal Stromal Tumor

Selim Sozen MD¹, Ömer Tuna MD¹

Abstract

Meckel's diverticulum is located on the antimesenteric border of the ileum, approximately 45 to 60 cm proximal to the ileocecal valve, and results from incomplete closure of the omphalomesenteric or viteline duct. Common complications presenting in adults include bleeding, obstruction, diverticulitis, and perforation. Tumors within Meckel's diverticulum are a rare, but recognized complication.

A 62-year-old woman presented with peri-umbilical pain that had localized to the right iliac fossa. On examination, she was tender in the right iliac fossa, with localized peritonism. At surgery, a perforated Meckel's diverticulum was found that was associated with free intra-abdominal fluid and hemorrhage. A 25 mm nodule was found at the apex of Meckel's diverticulum. We resected 100 mm of the small bowel and a primary anastomosis was performed. Histopathological examination of the resected lesion revealed a mesenchymal tumor categorized as a gastrointestinal stromal tumor (GISTs).

GISTs arising from Meckel's diverticulum are an extremely rare, but recognized complication. Surgery is considered the standard treatment for non-metastatic GISTs with en bloc resection and clear margins.

Keywords: Complications, gastrointestinal stromal tumor, Meckel's diverticulum

Cite this article as: Sozen S, Tuna O. A Rare Case of Perforated Meckel's Diverticulum Presenting as a Gastrointestinal Stromal Tumor. *Arch Iran Med.* 2012; **15(5):** 325 – 327.

Introduction

Meckel's diverticulum is located on the antimesenteric border of the ileum, approximately 45 to 60 cm proximal to the ileocecal valve, and results from incomplete closure of the omphalomesenteric or viteline duct.¹ Common complications presenting in adults include bleeding, obstruction, diverticulitis, and perforation. Tumors within a Meckel's diverticulum are a rare but recognized complication. Meckel's diverticulum is surgically removed only when a complication arises or a neoplasia develops. The tumors are infrequent and observed only in 0.5% – 3.2% of the Meckel's diverticula. Of these tumors, 12% are gastrointestinal stromal tumors (GISTs).²

GISTs occur predominantly in adults at a median age of 58 years. The majority of GISTs (60% to 70%) have been reported to arise in the stomach, whereas 20% to 30% originate in the small intestine, and less than 10% in the esophagus, colon, and rectum. GISTs also occur in the extra-intestinal abdominal/pelvic sites such as the omentum, mesentery, and retroperitoneum.^{3,4} GISTs arising from Meckel's diverticulum are extremely rare.⁵

Case Report

A 62-year-old woman presented with peri-umbilical pain that had localized to the right iliac fossa. On examination, she was tender in the right iliac fossa with localized peritonism. Hematologic tests showed decreased hematocrit (Ht: 22%) and a platelet (PLT) count

of 114000/mL. Her hemoglobin white cell count was 15.2×10^9 (neutrophils 12.1×10^9). On physical examination, there was abdominal tenderness, rebound, and increased bowel sounds in all quadrants. Plain abdominal X-rays were first obtained when the patient had acute symptoms, which revealed air-fluid levels that suggested intestinal obstruction (Figure 1). A palpable mass in the right lower quadrant was present. The patient underwent surgery with a diagnosis of plastrone appendicitis. A McBurney incision in the abdomen was made; the appendix was normal. During surgery, a perforated Meckel's diverticulum was found, which was associated with free intra-abdominal fluid and hemorrhage (Figure 2). A 25 mm nodule was found at the apex of Meckel's diverticulum. The perforation of the diverticulum was also not associated with the tumor nodule. At the subsequent laparotomy, 100 mm of small bowel was resected and primary anastomosis performed. Histology confirmed a Meckel's diverticulum with a 12 mm area of perforation. The histopathological examination of the resected lesion revealed a mesenchymal tumor which was categorized as a GIST tumor. The stromal tumor demonstrated whirling sheets of spindle cells with a moderate level of pleomorphism and mitotic activity (6 – 7 mitoses/50 HPF; H&E stain). No necrosis was observed. Immunohistochemical staining for CD117, a-smooth-muscle actin (SMA), and S-100 protein was positive, whereas staining for desmin and CD34 was negative (Figure 3). The labeling index for MIB-1, determined by counting positively stained nuclei, was about 5%. The postoperative period was unremarkable and she was discharged in good general condition.

Discussion

Meckel's diverticulum is the most commonly encountered congenital anomaly of the small intestine, occurring in approximately

Authors' Affiliations: ¹Kayseri Training and Research Hospital, Department of General Surgery.

Corresponding author and reprints: Selim Sozen MD, Kayseri Training and Research Hospital Department of General Surgery, Kayseri /Turkey.
E-mail: selimsozen63@yahoo.com.

Accepted for publication: 14 September 2011

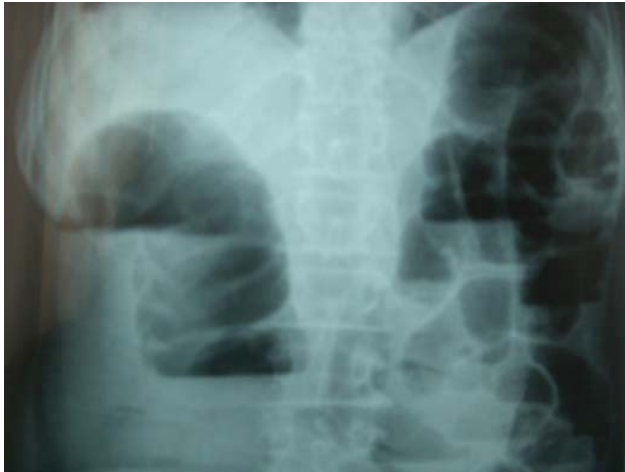

Figure 1. Plain abdominal X-rays were first obtained in patient with acute symptoms, which revealed air-fluid levels suggestive of intestinal obstruction.

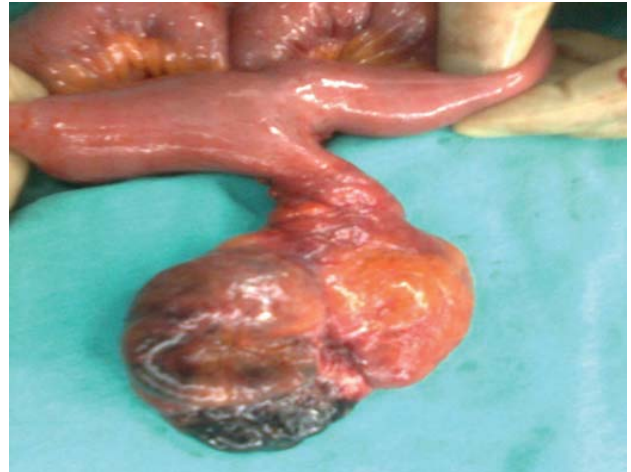

Figure 2. A 25 mm nodule was found at the apex of Meckel's diverticulum.

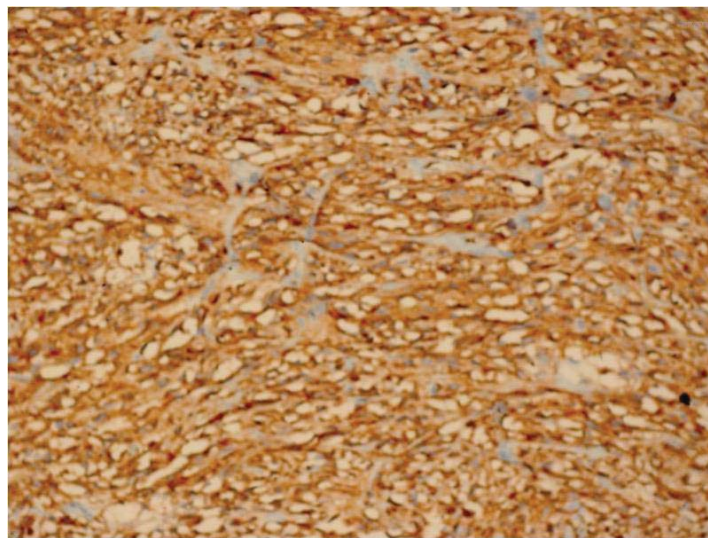


Figure 3. Immunohistochemical staining for CD117, a-smooth-muscle actin (SMA), and S-100 protein was positive, whereas staining for desmin and CD34 was negative.

2% of the population.^{6,7} GISTs, which arise primarily in the gut wall, are uncommon mesenchymal, malignant, or potentially malignant tumors affecting the gastrointestinal tract. GISTs are the most common non-epithelial tumors of the digestive tract, accounting for only 1% of all gastrointestinal malignancies.^{8,9} Primary GISTs may occur anywhere along the gastrointestinal tract from the esophagus to the anus.¹⁰ The most frequent site is the stomach (55%), followed by the duodenum and small intestine (30%), esophagus (5%), rectum (5%), colon (2%), and rare other locations. The incidence of tumors within Meckel's diverticulum is 0.5% to 3.2%.² Most are commonly benign tumors such as leiomyomas, angiomas, and lipomas. Malignant neoplasms include adenocarcinoma (which commonly originate from the gastric mucosa), sarcoma, carcinoid tumor, and GISTs.

The most common presentation of GISTs is acute or chronic gastrointestinal bleeding. They often present with nausea, vomiting, abdominal pain, metastatic disease, and bowel obstruction. In our case, the patient presented with bowel obstruction and perforation.

In a large series of 1476 cases at the Mayo Clinic, Park et al. have reported the most common presentations of symptomatic Meckel's

diverticula in adults to be bleeding (38%), obstruction (34%), diverticulitis (28%) and perforation (10%).¹¹ GISTs arise from the interstitial cells of Cajal, the pacemaker cells of the gastrointestinal tract.⁸ GISTs strongly express the KIT (CD 117) protein and may harbor mutations of the type III tyrosine kinase receptor gene (either KIT or PDGFRA).¹² For many patients, detection of GISTs may be an incidental finding during evaluation of nonspecific symptoms. Symptoms tend to arise only when tumors reach a large size or are in a critical anatomic location. Most symptomatic patients present with tumors larger than 5 cm in maximal dimension. Symptoms at presentation may include abdominal pain, abdominal mass, nausea, vomiting, anorexia, and weight loss. There are little prognostic data regarding GISTs and current prognostic indicators are based on consensus guidelines. The most important adverse factors are thought to be a tumor diameter of greater than 5 cm and a high mitotic count exceeding 5 mitotic figures per 50 high powered fields on light microscopy.^{12,13} Other suggested factors indicative of poor prognosis include tumor perforation, tumor necrosis, high cellularity, and marked pleiomorphism.¹²

Surgery is considered the standard treatment for non-metastatic

GISTs with en bloc resection and clear margins. The treatment of choice is the complete resection of the tumour. The surgeon's approach in an actual case depends on factors such as: the exact anatomical site of the GISTs, the characteristics of the individual patient's particular situation, and the specific location of the tumour relative to the blood supply of the involved organ. There is little evidence to support local/regional lymphadenectomy as GISTs rarely metastasize to lymph nodes.¹² Targeted therapy with imatinib, a KIT tyrosine kinase inhibitor, is considered the standard treatment for metastatic GISTs.¹² In our case, the outcome has shown that the location is very important in determining the prognosis. Patients with a small bowel localization do worse than those with stomach GISTs as reported by DeMatteo et al.¹⁴ In a case of a MD (Meckel diverticulum) localization, treatment with imatinib mesylate has been reported by Khoury et al.,¹⁵ but the impact on the clinical behavior of the disease has not been described. The case reported by us has a low risk of recurrence based on characteristics of a maximum diameter of 2.5 cm, a low mitotic count of less than one mitotic figure in 10×40 high powered fields, and no evidence of necrosis. Importantly, the perforation of the diverticulum was also not associated with the tumor nodule.

Conclusion

GISTs arising from Meckel's diverticulum are an extremely rare but recognized complication.⁵ Surgery is considered the standard treatment for non-metastatic GISTs with en bloc resection and clear margins.

References

1. Dumper J, Mackenzie S, Mitchell P, Sutherland F, Quan ML, Mew D. Complications of Meckel's diverticula in adults. *Can J Surg.* 2006; **49**: 353 – 357.
2. Yahchouchy E, Marano A, Etienne J, Fingerhut A. Meckel's diverticulum. *J Am Coll Surg.* 2001; **192**: 658 – 662.
3. DeMatteo RP, Lewis JJ, Leung D, Mudan SS, Woodruff JM, Brennan MF. Two hundred gastrointestinal stromal tumors: Recurrence patterns and prognostic factors for survival. *Ann Surg.* 2000; **231**: 51 – 58.
4. Miettinen M, Lacosta J. Gastrointestinal stromal tumors definition, clinical, histological, immunohistochemical and molecular genetic features and differential diagnosis. *Arch Pathol Lab Med.* 2006; **130**: 1466 – 1478.
5. Hager M, Maier H, Eberwein M, Klingler P, Kolbitsch C, Tiefenthaler W, et al. Perforated Meckel's diverticulum presenting as a gastrointestinal stromal tumor: A case report. *J Gastrointest Surg.* 2005; **9**: 809 – 811.
6. Haber JJ. Meckel's diverticulum. *Am J Surg.* 1947; **73**: 468 – 485.
7. Harkins HN. Intussusception due to invaginated Meckel's diverticulum. *Ann Surg.* 1933; **98**: 1070 – 1095.
8. Nowain A, Bhakta H, Pais S, Kanel G, Verma S. Gastrointestinal stromal tumors: Clinical profile, pathogenesis, treatment strategies and prognosis. *J Gastroenterol Hepatol.* 2005; **20**: 818 – 824.
9. Eisenberg BL, Judson I. Surgery and imatinib in the management of GIST: Emerging approaches to adjuvant and neoadjuvant therapy. *Ann Surg Oncol.* 2004; **11**: 465 – 475.
10. Judson I. Gastrointestinal stromal tumors (GIST): Biology and treatment. *Ann Oncol.* 2002; **13**: 4287 – 4289.
11. Park J, Wolff B, Tollefson M, Walsh E, Larson D. Meckel diverticulum. The Mayo Clinic experience with 1476 patients (1950 – 2002). *Ann Surg.* 2005; **241**: 529 – 533.
12. Joensuu H. Gastrointestinal stromal tumor (GIST). *Ann Oncol.* 2006; **10**: 280 – 286.
13. Chang M, Choe G, Kim W, Kim Y. Small intestine stromal tumors: A clinicopathological study of 31 tumors. *Pathol Int.* 1998; **48**: 341 – 347.
14. DeMatteo RP, Gold JS, Saran L, Gönen M, Liao KH, Maki RG, et al. Tumour mitotic rate, size, and location independently predict recurrence after resection of primary gastrointestinal stromal tumor (GIST). *Cancer.* 2008; **112**(3): 608 – 615.
15. Khoury MG, Alicino MR. Gastrointestinal stromal tumor (GIST) presenting in a Meckel's diverticulum. *Abdom Imaging.* 2007; **32**: 78 – 80.