

Original Article

Impact of Exploration of Sensory Branches of Saphenous Nerve in Anterior Cruciate Ligament Reconstructive Surgery

Fardin Mirzatooei MD¹, Karim Pisoodeh MD²

Abstract

Background: Post-operative sensory disturbances following anterior cruciate ligament (ACL) reconstruction using the quadruple hamstring tendon is a prevalent complication. This study evaluates the impact of exploration and salvage of superficial branches of the saphenous nerve on the incidence of post-operative sensory loss.

Methods: In a prospective descriptive study, 98 out of 120 patients with ACL reconstruction operated by the transfix method were followed 2 weeks and 6 months post-surgery. Hamstring tendon autograft was harvested through a 2–3 cm anteromedial oblique incision just over the pes anserinus. Meticulous dissection was done to find and save the superficial sensory branches of the saphenous nerve through the incision. Sensory changes were evaluated by physical examination for light touch; patients were requested to complete a specific diagram to evaluate sensory loss.

Results: In 44 patients at least one nerve was located and saved. The rate of hypoesthesia in this group of patients was 20.5%. In 54 patients we were unable to locate the nerve. The rate of hyposthesia in this group was 72%, which was statistically significant ($P < 0.005$). The overall rate of sensory disturbance in 98 patients was 48.9%. A total of 10 patients developed hyposthesia over the anteromedial part of the Mid-leg.

Conclusion: Exploration and salvage of the sensory branches of the saphenous nerve has a tremendous effect on the rate of sensory deficit.

Keywords: Anterior cruciate ligament, hamstring tendons, reconstruction

Cite the article as: Mirzatooei F, Pisoodeh K. Impact of Exploration of Sensory Branches of Saphenous Nerve in Anterior Cruciate Ligament Reconstructive Surgery. *Arch Iran Med.* 2012; **15**(4): 219 – 222.

Introduction

With improvements in surgical techniques for anterior cruciate ligament (ACL) reconstruction, patients' expectations regarding surgical outcomes have increased, and more attention is paid to minor complications. The results and complications of ACL reconstruction using a hamstring tendon graft have been well described.¹⁻⁴

One of the less discussed, yet more common complications of this surgery is damage to the infrapatellar branch of the saphenous nerve (IPSN). This iatrogenic damage occurs during graft removal and its incidence has been reported to be 50%–77%.⁵⁻⁷ In order to decrease the incidence of this complication some attempts, including decreasing the incision size and changing its obliquity from vertical to a more horizontal incision have been performed. Oblique rather than vertical incisions for the site of graft harvesting have reduced the incidence of altered sensation, however, the problem still remains.⁸ Concerns about damage to the main trunk of the saphenous nerve have emerged.⁹

There is no study that has determined whether exploration of the infrapatellar branch of the femoral nerve could decrease the inci-

dence of sensory disturbances. We hypothesize that exploration of sensory branches of the saphenous nerve is possible through the incision for graft removal and exploration of these sensory branches could decrease post-operative hyposthesia. This randomized clinical trial study has been conducted to evaluate our thesis.

Materials and Methods

A total of 120 patients (118 males and 2 females) underwent ACL reconstruction over an 18 month period (July 2007 to January 2009). The study protocol was approved by the Ethics Committee of Urmia University of Medical Sciences, Urmia, Iran. The study was conducted in accordance with the Declaration of Helsinki and registered with the Iranian Registry of Clinical Trials as identifier number 5257. All participants received oral and written information about the purpose and procedures of the study and provided written informed consents.

The average age of the patients was 29 years (18 to 42 years). The first visit was 2 weeks after surgery. To be included in the study, patients must have completed their 6 month follow up. Indication for surgery was a young active patient with an ACL rupture who desired to increase his or her level of activity. All surgeries were performed by one surgeon who used the hamstring quadruple autograft technique. All patients had no histories of previous knee surgeries and revision cases were not included. Patients with scar tissue around the knee were also excluded. For all

Authors' affiliation: ¹Department of Orthopedic Surgery, Urmia University of Medical Sciences, Urmia, Iran. ²Orthopedic Ward, Urmia University of Medical Sciences, Urmia, Iran.

Corresponding author and reprints: Fardin Mirzatooei MD, Department of orthopedic surgery, Urmia University of Medical Sciences, Urmia, Iran. Tel: +98-914-143-5104, Email: fardin_tolouei@yahoo.com.

Accepted article for publication: 24 August 2011

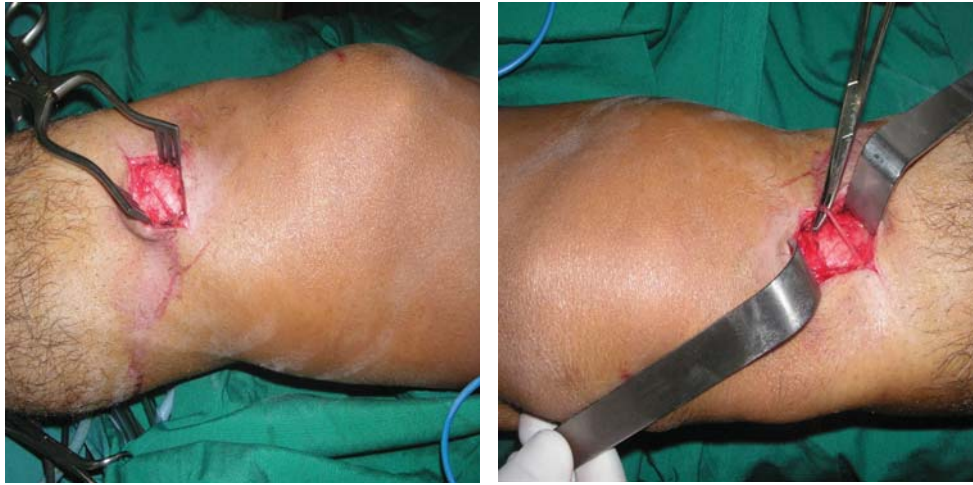


Figure 1. Sensory branch of the saphenous nerve.

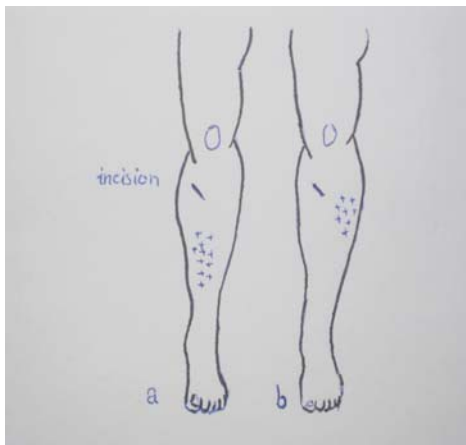


Figure 2. Two distinct patterns of hyposthesia over a) anterolateral and b) anteromedial aspects of the leg.

patients, the cross pin fixation technique (Arthrex Inc., Naples, Florida, USA) was used.

Surgical technique

The tourniquet used for all cases was inflated to 300 mmHg and deflated in less than 1.5 hours. Arthroscopy was performed through the standard anterolateral porta. Meniscal injuries were treated by partial meniscectomy or repair using a totally inside technique for meniscal repair. There were no extra incisions for meniscus surgeries. A 3 cm incision was made from the superomedial to inferolateral on the proximal medial portion of the leg. The landmark for the incision's starting point was 3 centimeters distal to the junction of the joint line with the anterior border of the medial collateral ligament. The obliquity of the incision was 45 degrees. After cutting the skin, any superficial nerve in the operating field was explored with meticulous dissection (Figure 1). This dissection was not extended beyond the boundaries of the surgical field. Using a rubber band, the located nerve was spared during surgery. At times when no nerves were located, surgery continued as usual after a 5 minute exploratory period. Nerve exploration was performed with the naked eye; no loupes or microscope were used by the surgeon. Then, the sartorius fascia was cut and semitendinosus and gracilis tendons were harvested using an open tendon stripper. Special attention was paid not to damage the explored nerves during graft harvest. The nerves also were kept

away from the field when the tibial tunnel was performed. Following tibial and femoral tunnel preparation, the Arthrex femoral guide C-ring was positioned and the tibial tunnel was fashioned through the same skin incision. With a small stab incision made through the skin of the proximal lateral femoral condyle, the transfix pin was advanced into the femur. The quadrupled hamstring graft was then fixed into the tibia using Arthrex bioscrews. No supplementary fixation device was used on the tibia. Finally, the skin was closed by nylon sutures without fascia or subcutaneous approximation.

Post-operatively, at 2 weeks and 6 months, patients returned to the clinic for the study visits. At follow up, patients were requested to complete a questionnaire with a specifically designed diagram. In the Diagram 1, the shape of the right and left leg were copied in a sheath in both antero-posterior and lateral views. All data were collected by a well-trained nurse who had no relation to the study. Three different color pens were available for patients to mark the areas of altered sensation as follows: i) the red pen depicted severe paresthesia or anesthesia, ii) blue indicated moderate paresthesia, and iii) green was mild paresthesia.

For descriptive purposes we reported the qualitative factors in terms of rates and the quantitative variables in terms of means. Comparison of means between the groups was performed by the Mann-Whitney rank sum test. The Chi square and Fisher's exact tests were used to compare differences in proportions. Signifi-

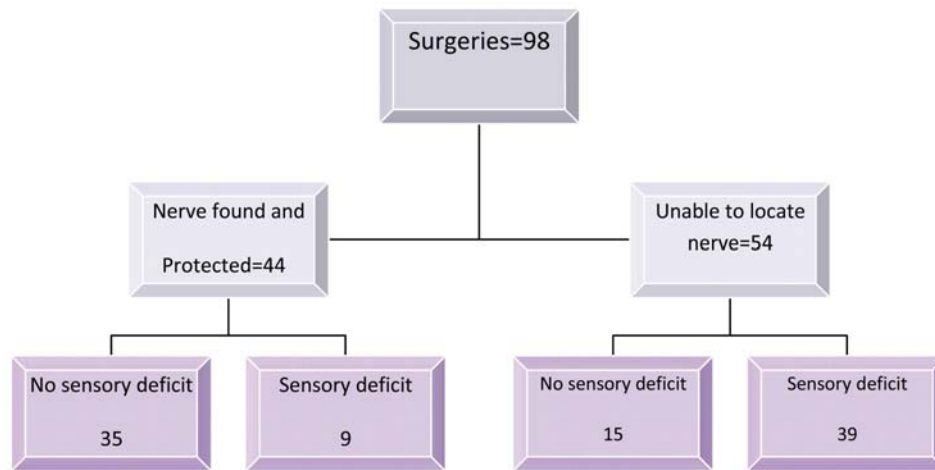


Diagram 1. Rate of sensory loss in patients with and without explored nerves.

cance was set at 0.05. Geographical distribution of the sensory disturbance was described.

Results

All patients were visited at 2 weeks post-surgery and 98 patients (82%) completed their 6 month follow up. Twenty-two patients missed their further follow ups. In 18, the superficial nerve could be explored of which 17 had normal sensation. The average incision size was 32 mm. There was no premature graft failure or infection. In 44 out of 98 patients at least 1 superficial sensory branch was found and kept intact until the end of surgery. A total of 35 out of these 44 patients (79.5%) had normal sensation at the end of 6 months. In the remaining 54 patients no nerves were located after a 5 minute attempt at nerve exploration or the located nerves (2 cases) ruptured during surgery. In this group, 39 patients had some degree of sensory disturbance (72%). Totally, 48 out of 98 patients (48.9%) had sensory deficit (Figure 2). The Chi square test showed that the difference between the proportion of sensory disturbance in both groups (located nerve vs. no nerve) was significant ($P < 0.0001$).

The sensory deficit was in the range of mild paresthesia to complete anesthesia. According to the diagrams, post-operative sensory changes occurred in two areas (Figure 2). In 38 patients it was over the superior and anterolateral aspect of the leg. This area of sensory deficit was approximately 2–3 cm distal and lateral to the incision and was circular in configuration. In 10 patients it was on the anteromedial and distal part of the leg, and was oval in shape. The colors used by the patients to demonstrate the severity of hyposthesia were mainly blue and green in the first pattern and red in the second pattern.

Three patients recovered from sensory damage between the 2 follow-ups of 2 weeks and 6 months. All of these patients had mild sensory deficits at the first follow up, which were been represented by blue and green marks. All were in the proximal-antero-lateral part of the leg.

Discussion

Findings of this study revealed that exploration and salvage of

superficial sensory branches of the saphenous nerve significantly reduced post-operative sensory loss after ACL reconstruction with the hamstring tendon graft. Approximately 80% of those patients whose sensory nerves could be explored had normal sensation post-operatively. The question may be raised as to the location of the nerves that we could not find. They were present but we were unable to locate them because of anatomical variation in their distribution. In fact, our aim in conducting this study was not to locate these nerves but to save them if they were in the way of the dissection with the intent to see if any change occurred on the rate of post-operative sensory disturbance. Further anatomical studies are needed to clarify the exact distribution and landmarks of saphenous nerve branches. Previous studies have shown a much higher incidence of sensory loss with a similar technique but without nerve exploration. Other studies report a rate of post-operative hyposthesia at between 30% to 60%.^{11–13} Figueroa evaluated 22 knees with ACL reconstruction using the electrophysiological method and found a 77% rate of nerve injury.⁷ In one study, a change in the direction of the incision from vertical to oblique reduced the incidence of post-operative hyposthesia from 39.7% to 14.9%.¹⁴ We should mention that despite the significant decrease in the incidence of sensory disturbances in our patients in whom the nerve could be found, the overall rate of sensory loss was 48.9%. This high rate of hyposthesia was partially affected by the number of patients who had hyposthesia over the skin of the distal and medial sides of the leg. This model of sensory disturbance could not be the result of damage to the IPSN but instead to saphenous nerve main trunk. This injury may occur during tendon stripping with the use of various tendon strippers. The saphenous nerve is the longest branch of the femoral nerve.¹⁰ It's anterior branches innervate the anteromedial aspect of the leg and tibial crest. The posterior half of the calf is innervated by posterior branches of this nerve and the most distal branches innervate the medial aspect of the foot. In the literature, damage to the IPSN has been introduced as a major cause of sensory loss after hamstring tendon graft harvesting surgeries.^{11–15} The anatomical position of the IPSN has been studied in many cadaver dissections.^{16,17,18} In 98.5% of cases it is located between the distal pole of the patella and tibial tubercle. This is not the location for hamstring graft harvesting incisions. In fact, the concept of injury to the IPSN in

arthroscopic ACL surgeries comes from the era when the patellar tendon graft was the dominant choice for graft selection and the IPSN was vulnerable to injury during graft removal. In our study, none of the patients complained of hyposthesia lateral to the patellar tendon. Instead, the hyposthesias were over the proximal-anterolateral part of the leg. Sensory branches of the saphenous nerve other than IPSN should be responsible for the sensory loss at this area. We were unable to find a sensory nerve branch with a specific name in illustrated textbooks or the literature to relate the existed hyposthesia over the proximal-anterolateral part of the leg. For this reason we considered the explored sensory branches of the surgical field as IPSN.

Another finding in our study was the skin sensory loss over the sartorial branch of the saphenous nerve innervations zone, which occurred in a subset of patients. Ten patients (9.8%) developed hyposthesia in the medial aspect of their legs just right to the tibial crest. This is not a new finding as it has been reported previously by other authors.^{7,9} As it may be expected, the rate of this complication did not change by our nerve exploration, strengthening the assumption that it was developed during tendon stripping. The saphenous nerve is closely intimated with the gracilis tendon and may be injured during gracilis tendon harvesting. Another location where this nerve could be injured is where the side pin exits the bone and pierces the skin. Further studies are needed to clarify the exact pathophysiology of this complication.

Preserving the sensory branches of the saphenous nerve during hamstring graft harvesting could decrease the rate of post-operative sensory disturbances. Despite the relatively constant incision mode sensory branches were not located in all cases, which represented the variation in anatomical distribution of these branches. We have recommended performing an oblique incision with meticulous dissection to locate and preserve any sensory branches at the surgical field. Despite the efforts for decreasing the incidence of sensory damage by this method, injury to the main trunk of the saphenous nerve occurs during graft stripping.

References

- Shelbourne KD, Gray T. Minimum 10-year results after anterior cruciate ligament reconstruction: How the loss of normal knee motion compounds other factors related to the development of osteoarthritis after surgery. *Am J Sports Med.* 2009; **37**: 471 – 480.
- Rue JP, Lewis PB, Parameswaran AD, Bach BR. Single-bundle anterior cruciate ligament reconstruction: technique overview and comprehensive review of results. *J Bone Joint Surg [Am].* 2008; **90**: 67 – 74.
- Jarvela T, Moisala AS, Sihvonen R, Jarvela S, Kannus P, Jarvinen M. Double-bundle anterior cruciate ligament reconstruction using hamstring autografts and bioabsorbable interference screw fixation: Prospective, randomized, clinical study with 2-year results. *Am J Sports Med.* 2008; **36**: 290 – 297.
- Xu Y, Ao YF, Yu JK, An H, Liu XP. Compare the clinical results of double-bundle with single-bundle anterior cruciate ligament reconstruction. *Zhonghua Wai Ke Za Zhi.* 2008; **46**: 274 – 276.
- Sgaglione NA, Warren RF, Wickiewicz TL, Gold DA, Panariello RA. Primary repair with semitendinosus tendon augmentation of acute anterior cruciate ligament injuries. *Am J Sports Med.* 1990; **18**: 64 – 73.
- Aglietti P, Giron F, Buzzi R, Biddau F, Sasso F. Anterior cruciate ligament reconstruction: bone–patellar tendon–bone compared with double semitendinosus and gracilis tendon grafts. A prospective, randomized clinical trial. *J Bone Joint Surg.* 2004; **86**: 2143 – 2155.
- Figueroa D, Calvo R, Vaisman A, Campero M, Moraga C. Injury to the infrapatellar branch of the saphenous nerve in ACL reconstruction with the hamstrings technique: clinical and electrophysiological study. *The Knee.* 2008; **15**: 360 – 363.
- Portland GH, Martin D, Keene G, Menz T. Injury to the infrapatellar branch of the saphenous nerve in anterior cruciate ligament reconstruction: comparison of horizontal versus vertical harvest site incisions. *Arthroscopy.* 2005; **21**: 281 – 285.
- Jameson S, Emmerson K. Altered sensation over the lower leg following hamstring anterior cruciate ligament reconstruction with transverse femoral fixation. *The Knee.* 2007; **14**: 314 – 320.
- Pendergrass TL, Moor JH. Saphenous neuropathy following medial knee trauma. *J Orthop Sports Phys Ther.* 2004; **34**: 328 – 334.
- Kartus J, Movin T, Karlsson J. Donor-site morbidity and anterior knee problems after anterior cruciate ligament reconstruction using autografts. *Arthroscopy.* 2001; **17**: 971 – 978.
- Ejerhed L, Kartus J, Sernert N, Köhler K, Karlsson J. Patellar tendon or semitendinosus tendon autografts for anterior cruciate ligament reconstruction? A prospective randomized study with a two-year follow-up. *Am J Sports Med.* 2003; **31**: 19 – 25.
- Wagner M, Kääh MJ, Schallock J, Haas NP, Weiler A. Hamstring tendon versus patellar tendon anterior cruciate ligament reconstruction using biodegradable interference fit fixation: a prospective matched-group analysis. *Am J Sports Med.* 2005; **33**: 1327 – 1336.
- Papasteriou SG, Voulgaropoulos H, Mikalef P, Ziogas E, Pappis G, Giannakopoulos I. Injuries to the infrapatellar branch(es) of the saphenous nerve in anterior cruciate ligament reconstruction with four-strand hamstring tendon autograft: Vertical versus horizontal incision for harvest. *Knee Surg Sport Traumatol Arthrosc.* 2006; **14**: 789 – 793.
- Maeda A, Shino K, Horibe S, Nakata K, Buccafusca G. Anterior cruciate ligament reconstruction with multistranded autogenous semitendinosus tendon. *Am J Sports Med.* 1996; **24**: 504 – 509.
- Sanders B, Rolf R, McClelland W, Xerogeane J. Prevalence of saphenous nerve injury after autogenous hamstring harvest: an anatomic and clinical study of sartorial branch. *Arthroscopy.* 2007; **23**: 956 – 963.
- Kartus J, Ejerhed L, Eriksson BI. The localization of the infrapatellar nerves in the anterior knee region with special emphasis on central third patellar tendon harvest: a dissection study on cadaver and amputated specimens. *Arthroscopy.* 1999; **15**: 577 – 586.
- Ebraheim NA, Mekhail AO. The infrapatellar branch of the saphenous nerve: An anatomic study. *J Orthop Trauma.* 1997; **11**: 195 – 199.