

Photoclinic

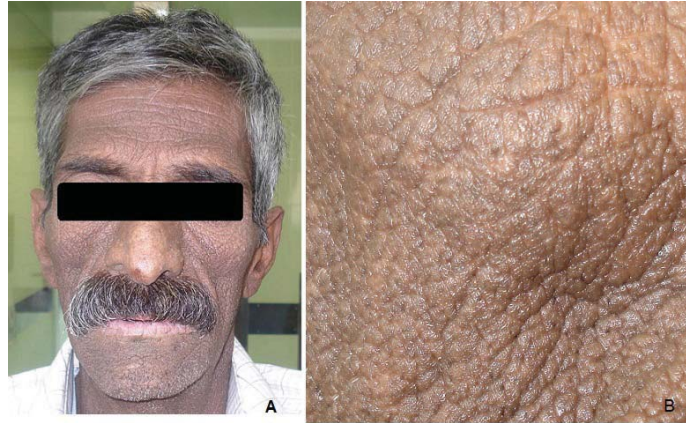

Figure 1. Generalized pigmentation (A) Head and neck; (B) closed view.

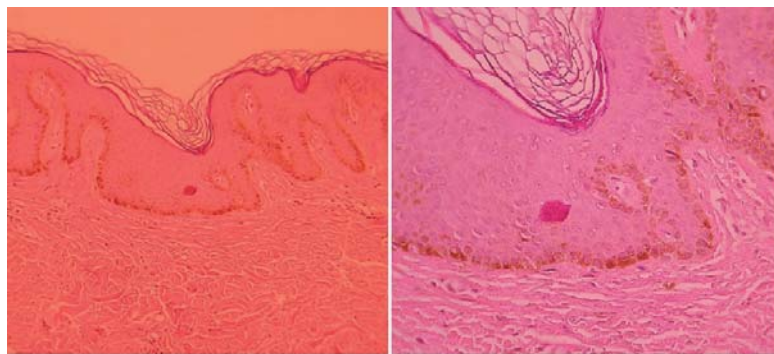


Figure 2. Microscopic view of abdominal skin which shows hyperkeratosis, mild focal papillomatosis, moderate irregular acanthosis, and hyperpigmentation of the basal layer of the epidermis (H&E, Left: 40 \times , right: 100 \times).

Cite the article as: Khorgami Z, Anbara T, Mohammadnejad A, Mahmoodzadeh H. Photoclinic. *Arch Iran Med.* 2012; **15**(4): 257 – 258.

A 54-year-old man with sudden onset of rapid progressive generalized skin hyperpigmentation (Figure 1) referred to the Gastroenterology Department of Shariati Hospital, Tehran, Iran in August 2009. He had been assessed for Addison's disease in the Endocrinology Department 3 months prior because of generalized hyperpigmentation and malaise, but discharged with no certain diagnosis. Later, the patient developed diet intolerance with nausea and vomiting, which resulted in a loss of over 14 Kg during 6 months. He underwent upper gastrointestinal tract endoscopy, which revealed decreased distensibility of the stomach with diffused antral mucosal edema. Multiple biopsies were taken, which

showed chronic gastritis, crypt abscess formations, and hypertrophy.

Laboratory findings included: hypernatremia, hypokalemia, and elevated serum cortisol (28.3 mcg/dL, NL: 5–26 mcg/dL). Other biochemical parameters were within normal ranges. Abdominal and pelvic CT scan revealed a distended stomach with irregularity in the pyloric region and fundus of the stomach. Therefore, the patient was referred to the Surgical Department for exploratory laparotomy, which revealed advanced gastric cancer with gastric outlet obstruction, and multiple small liver and peritoneal metastases. Biopsy and gastrojejunostomy anastomosis was performed. Histopathological evaluation of the stomach, liver, and peritoneal biopsies showed moderately differentiated mucinous type adenocarcinoma. Pathologic evaluation of the abdominal skin biopsy showed hyperkeratosis, papillomatosis, and hyperpigmentation of the basal layer (Figure 2).

Zhamak Khorgami MD¹, Taha Anbara MD¹, Atefeh Mohammadnejad MD¹, Habibollah Mahmoodzadeh MD²

Authors' affiliations: ¹Shariati Hospital, Tehran University of Medical Sciences, ²Cancer Institute, Tehran University of Medical Sciences, Tehran, Iran.

Corresponding author and reprints: Zhamak Khorgami MD, Surgery Department of Shariati Hospital, North Kargar Ave., Tehran, Iran.

Tel: +98-218-490-2450, Fax: +98-218-863-3039

E-mail: khorgami@gmail.com.

Accepted for publication: 27 July 2011

**What is your diagnosis?
See the next page for diagnosis.**

Acanthosis nigricans (AN) lesions are focal symmetric, velvety hyperkeratotic discoloratic plaques that develop usually on skin folds, particularly the axilla, flexures, nipple, navel, and anogenital region.^{1,2} Benign types of AN may run in families with no evidence of endocrinological disturbances or internal malignancy, but can be associated with endocrine problems such as Addison's disease. It has also been reported in obese, dark-skinned people, and those known for insulin resistance and diabetes.³

Sudden and/or late onset, and extensive rapid marked thickening with mucous membrane, nail, hair, palms, and involvement of the soles are important differentiating pointers in malignant AN, which almost always indicate the presence of internal malignancy.⁴ AN occurrence in adults is closely related with internal malignancy, most often gastrointestinal and respiratory tract cancers, which are common in many countries.⁵ Generalized AN (GAN) is a rare paraneoplastic syndrome, which has been reported in patients with advanced and inoperable cancers, such as gastric or cervix uteri carcinoma. There is a belief that growth stimulating factors derived from tumor cells are probable causes of GAN.^{6,7} However, this sign is non-specific and usually develops too late for any curative procedures.⁸

Treatment of AN is difficult because it needs management of the underlying neoplasm. Skin lesions may improve by surgical excision of the tumor, but may also worsen subsequently with re-

currence or metastases of the primary neoplasm. Thus, complete treatment of AN is often unsatisfactory.⁵

Overall, more attention should be paid to AN, especially the generalized form, in order to consider underlying malignancies before they become widespread.

References

1. Matono S, Fujita H, Tanaka T, Tanaka Y, Sueyoshi S, Tsubuku T. Malignant acanthosis nigricans with esophageal cancer. *Esophagus*. 2009; **6**: 127 – 131.
2. Kamińska-Winciorek G, Brzezińska-Wcisło L, Lis-Święty A, Krauze E. Paraneoplastic type of acanthosis nigricans in patient with hepatocellular carcinoma. *Adv Med Sci*. 2007; **52**: 254 – 256.
3. Matsuoka L, Wortsman J, Gavin J, Goldman J. Spectrum of endocrine abnormalities associated with acanthosis nigricans. *Am J Med*. 1987; **83**: 719 – 725.
4. Schwartz R. Acanthosis nigricans. *J Am Acad Dermatol*. 1994; **31**: 1 – 19.
5. Weismann K. Skin disorders as markers of internal disease. Paraneoplastic dermatoses. *Ugeskr Laeger*. 2000; **162**: 6834 – 6839.
6. Andreev V, Boyanov L, Tsankov N. Generalized acanthosis nigricans. *Dermatologica*. 1981; **163**: 19 – 24.
7. Mikhail G, Fachnie D, Drukker B, Farah R, Allen H. Generalized malignant acanthosis nigricans. *Arch Dermatol*. 1979; **115**: 201 – 202.
8. Mori S. Useful cutaneous markers of internal malignancy in the early stage [in Japanese]. *Gan To Kagaku Ryoho*. 1988; **15**: 1564 – 1568.