

## Original Article

# Augmentation Rhinoplasty with Combined use of Medpor Graft and Irradiated Homograft Rib Cartilage in Saddle Nose Deformity

Ebrahim Razmpa MD<sup>1</sup>, Babak Saedi MD<sup>•1</sup>, Farshid Mahbobi MD<sup>1</sup>

## Abstract

**Background:** We used the irradiated homograft rib cartilage as an augmentation tip support and Medpore alloplast for reconstruction of the dorsum in patients with saddle nose deformities. Thereafter, the safety and efficiency of this method was evaluated to determine if this can be a safe and efficient technique for patients with saddle nose deformities.

**Methods:** A total of 32 patients who suffered from saddle nose deformities due to past trauma or aggressive rhinoplasty underwent reconstruction using the Medpor prosthesis for dorsum reconstruction and irradiated rib cartilage as a columellar strut during the same technique. After at least one year follow up, patients' satisfaction and their aesthetic indexes were evaluated and compared with preoperative results.

**Results:** More than 84% of patients were satisfied from the results of the surgery and only one patient had a complication of the infection which resulted in removal of the prosthesis. There were statistically significant differences between most of the pre- and postoperative aesthetic indexes.

**Conclusion:** Despite the superiority of autogenous material in nose reconstruction, lack of such materials in revision rhinoplasty cases present challenges to surgeons. This study proposes the safety and efficiency of the Medpor alloplast for reconstruction of the dorsum and irradiated rib cartilage for the tip, at least for a short period of time.

**Keywords:** Alloplast, irradiated cartilage, Medpor, rhinoplasty, saddle nose

**Cite the article as:** Razmpa E, Saedi B, Mahbobi F. Augmentation Rhinoplasty with Combined use of Medpor Graft and Irradiated Homograft Rib Cartilage in Saddle Nose Deformity. *Arch Iran Med.* 2012; **15(4)**: 235 – 238.

## Introduction

Nasal plastic surgery is accepted as a complicated and efficient aesthetic surgery. Although the most prevailing use of this type of surgery is for cosmetic purposes, its other common use is for reconstructive reasons. Occasionally some patients, particularly traumatic cases, encounter many impediments among which tissue deficiency is the hardest hindrance to overcome.<sup>1</sup> Over time, many researchers have attempted to use different materials as a substitute for missing parts.

It has been demonstrated that autologous materials are superior to exogenous materials, however, lack of reliable tissue resources in most saddle nose deformities on the one hand, the morbidity of graft removal from distant sites, and time consuming nature of the procedure on the other hand, leads to attempts at different methods of substitution.<sup>1-7</sup>

The typical deformities of the saddle nose consist of inadequate dorsal height, decreased tip supports, and projection. Consequently, an augmentation procedure with dorsal graft and columellar strut graft as complementary parts of the routine septorhinoplasty is required.

There are two broad groups of graft materials: allografts and homografts. Apart from the types of material, the ideal material should be biocompatible, stable to re-absorption and resistant to infection. Among allografts, it is claimed that porous high-density

polyethylene (Medpor) has these characteristics.<sup>2, 5, 8-16</sup> Therefore, Medpor can be a good option for augmentation of the dorsum. However, in special urgent cases and the need to re-establish tip support, homografts are superior.<sup>3, 4, 13</sup> Among the diverse choices of materials, an irradiated homograft rib can be a good alternative because it can be easily shaped and replaced with the patients' own tissues, in addition to its non-immunogenic character and lower extrusion rate in the tip area.<sup>1, 13, 14</sup>

We used irradiated homograft rib cartilage as augmentation of the tip support and Medpor alloplast for reconstruction of the dorsum. We assessed the outcome and safety of this method in reconstruction of saddle nose deformity.

## Materials and Methods

### Study subjects

We enrolled 32 patients who suffered from saddle nose deformities due to past trauma or unsuccessful rhinoplasty. These patients underwent reconstruction by the same technique between May 2007 and January 2009 in an otolaryngology section of a tertiary referral center (Imam Khomeini Hospital complex). The consecutively enrolled patients had no histories of any systemic diseases (e.g., diabetes, immune deficiency, or rheumatologic diseases), hypersensitivity to Medpor, or substances used for preparation of the irradiated rib cartilage.

### Ethics approval

The protocol of this study was approved by the Institutional Review Board of the Tehran University of Medical Science. Detailed information about the study was given to the participants and a written informed consent was obtained from each one. All aspects

**Authors' affiliation:** <sup>1</sup>Otolaryngology Department, Tehran University of Medical Sciences, Tehran, Iran.

**Corresponding author and reprints:** Babak Saedi MD, Otolaryngology Research Center, Imam Khomeini Medical Center, Bagherkhan St., Chamran Highway, Tehran 141973141, Iran.

Fax: +98-216-658-1628, E-mail: saedi@tums.ac.ir

Accepted for publication: 13 July 2011

**Table 1.** Comparison between preoperative and postoperative aesthetic analyses.

Evaluated index	Preoperative Mean $\pm$ SD	Postoperative Mean $\pm$ SD	Difference Mean $\pm$ SD	P-value
Dorsum depression	6.25 $\pm$ 1.1	1.78 $\pm$ 0.79	4.47 $\pm$ 1.19	< 0.001*
Nasofrontal angle	139.3 $\pm$ 7.1	138.6 $\pm$ 5.4	0.75 $\pm$ 4.6	<0 .361
Nasolabial angle	92.4 $\pm$ 9.3	98.8 $\pm$ 8	6.44 $\pm$ 5.5	< 0.001*
Projection	56.1 $\pm$ 6.2	59.8 $\pm$ 3.3	2.7 $\pm$ 4.4	0.001*

**Table 2.** Comparison between preoperative and postoperative aesthetic analysis according to ideal values.

Evaluated index	Index status	Preoperative	Postoperative	P-value
Dorsum status	Appropriate	0	19(59.9%)	<0.001*
	Non-appropriate	32(100%)	13(40.6%)	
Nasofrontal angle	Appropriate	7(21.9%)	10(31.2%)	0.391
	Non-appropriate	25(78.1%)	22(68.8%)	
Nasolabial angle	Appropriate	14(43.3%)	12(37.5%)	0.611
	Non-appropriate	18(56.3%)	20(62.5%)	
Projection	Appropriate	13(40.6%)	5 (15.6%)	0.026*
	Non-appropriate	19(59.4%)	27(84.4%)	

of the study were conducted according to the Declaration of Helsinki. All materials used in this study were proven to be safe and approved by the FDA.

#### Procedures and materials

We used an endonasal rhinoplasty approach. However, in severely deviated noses, severely over-or under-projected noses, and cases of severe problems of the tip, an open approach with a similar technique was used. All procedures were performed by one of the senior authors under general anesthesia. The Medpor implants (Medpor surgical implants, Porex Surgical Inc., College Park, GA) were shaped with a #10 scalpel blade when necessary and it replaced in a pocket which can be create deep to the nasal dorsum periosteum. The height of the prosthesis was adapted according to the ideal dorsal height. No packing was used during surgeries, but an Aquaplast splint was positioned on the dorsum, which was removed after one week. Afterwards, tape was positioned over the nose and it was evaluated for the location of the prosthesis. Antibiotic prophylaxis (Cephalexin 500 mg, qid  $\times$  5 days) was administered to all patients and acetaminophen (325 mg, qid) was used as the sole analgesic. Subsequently, patients' nasal splints were removed after 7 days postoperatively and tapings were continued for 4 weeks thereafter.

The irradiated rib cartilages were adopted obtained from cadaveric rib cartilage whose donors were screened for HIV, HBsAg, and other infections. Rib cartilages were exposed to gamma ray radiation at doses of 30,000 to 60,000 Gy for the sterilization process. Consequently, the processed ribs were preserved in antibiotic solution before application. The columellar strut was constructed from pieces of processed rib cartilage. Its initial dimensions were 2 to 3 cm long, 2 to 3 mm wide, and 1 to 2 mm thick, such that it could be trimmed as a graft of different dimensions. It was placed into a pocket dissected with a curved Stevens scissor between the medial crura. The strut was loaded in the intercrural space, with slight force. The cephalic portion of the strut was attached to the midportion of the medial crura with two 4-0 nylon mattress sutures. The caudal edge of the strut was allowed to lie freely between the medial crura in a way that resembled a tongue-

in-groove. The graft was attached to the nasal spine with 4-0 nylon sutures, which were removed after 6 weeks.

The Medpor prosthesis was specially designed for the dorsum by the manufacturer. Its size was defined according to the volume of the defect and also its shape was altered during surgery.

#### Tests and assessment

In addition to demographic information, the type of procedure, its characteristics, and duration of nasal plastic surgery for all patients were documented. Surgical details such as open or closed approach, septoplasty, hump removal, osteotomy, or tip plasty was collected for all procedures. The nasal obstruction and patients' satisfaction were evaluated according to the Visual Analogue Scale (VAS) as 0 (worst status) and 10 (best status) during the pre- and postoperative periods. Patients completed a five-choice questionnaire that detailed a more accurate scaling of their satisfaction: 1 (completely unsatisfied), 2 (partially unsatisfied), 3 (partially satisfied), 4 (satisfied), and 5 (completely satisfied).

Additionally, pre- and postoperative digital standard photographs were taken to compare and re-evaluate the nasal tip projection, rotation and status of the dorsum with the preoperative values and views. Photographs were taken with a Canon Power Shot S5 digital camera and a Canon X12 Zoom lens to ensure proper and uniform photographic size. We used the same position for patients and photographer, according to the Frankfort horizontal line at a fixed distance of 1 m. The facial section between the horizontal planes running above the eyebrows and below the mentum was copied from the postoperative photograph. The tip projection, rotation, and dorsum status were measured as follows.

#### Nasal tip projection

We used Byrd's method for evaluating tip projection by drawing a line from the alar-cheek junction to the tip of the nose. If the upper lip projection was normal, a vertical line was drawn adjacent to the most projecting part of the upper lip. To achieve adequate tip projection, at least 50% of the horizontal line had to lie anterior to the vertical line. If 60% of the line lay anterior to it, the tip was

considered over projected and needed to be reduced. If 50% of the tip was anterior to the vertical line, it indicated a short nose with inadequate projection that needed augmentation. By utilizing Byrd's method, we considered normal projection to be in the range of  $55 \pm 5\%$ .

#### Nasal tip rotation

Adobe Photoshop 7.0 software (Adobe Systems Inc., San Jose, CA, USA) was used to measure the nasolabial angle between two lines drawn parallel to the upper lip and columella. Rotation in the range of  $90\text{--}95^\circ$  for men and  $95\text{--}110^\circ$  for women was considered normal.

#### Dorsum status

The dorsum status was measured by calculating the amount of maximal bulging or deepening over the dorsum with reference to a tangent line from Nasion (deepest point of nasal bone to) to tip defining point.

All measurements were performed by Adobe Photoshop 7 software, which provided an accurate analysis of the same facial sections in the postoperative photographs.

#### Statistical analysis

Data were analyzed using SPSS 11.5 for Windows (SPSS Inc., Chicago, IL, USA). We used the Chi square test to evaluate pre- and postoperative ratios in each group and ANOVA test to compare average data in three groups. The values were evaluated using descriptive statistical methods (mean  $\pm$  SD) and results were expressed at a significance level of  $P < 0.05$ .

## Results

During the study period, we enrolled 32 patients with a mean age of  $30.5 \pm 7$  years (range: 18–45), of which 10 (31.2%) were female and 22 (68.8%) were male. There were 23 (71.9%) patients who had trauma histories, 5 (15.6%) had previous rhinoplasty, and the remaining 4 (12.5%) patients had congenital deformities.

The method of surgery was the closed approach in 25 (78%) and open approach in 7 (21.9%) cases. In addition, 30 (93.8%) patients needed septoplasty. The mean duration of surgery was  $95 \pm 25$  minutes. The mean follow up period was  $25.2 \pm 4.9$  months.

Preoperatively, the mean patient VAS for nasal obstruction was  $4.9 \pm 2.6$  and  $1.9 \pm 0.8$  in the postoperative period, however, was not significant.

Table 1 shows the comparison of pre- and postoperative aesthetic indexes.

#### Paired sample t-test

These indexes were also evaluated according to their ideal values, as summarized in Table 2.

#### Chi-square test

As previously mentioned, the patient satisfaction rate was reported through two methods. Firstly, results were analyzed according to VAS ( $8.8 \pm 1.9$ ). Secondly, patients completed questionnaires, which indicated no patient dissatisfaction with the surgical outcome (Figure 1). There was no significant difference between the open and closed approach with regards to patient satisfaction and other evaluated variables.




Figure 1. Postoperative patient satisfaction results.

One postoperative infection resulted from trauma, which was managed by removal of the prosthesis. After six months, another surgery was performed and the patient's prosthesis was replaced. Prosthesis displacement in the cephalic portion occurred in 2 patients during the early postoperative period. Both patients recovered after taping for 2 weeks.

Figure 2 shows the preoperative pictures and postoperative results of 2 patients.

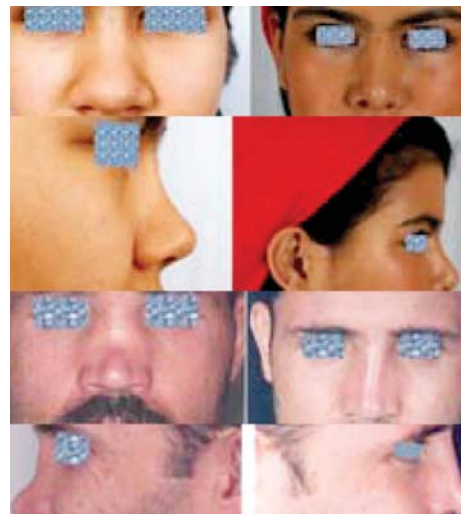

Figure 2. Pre- and postoperative views of two patients.

## Discussion

Saddle nose deformity as an outcome of past trauma is a difficult case to manage. There have been numerous proposed methods with which to overcome this difficulty. Most are based on using patient's own tissues, but regarding the lack of adequate tissues materials in complicated cases as well as donor site morbidity, the idea of using biocompatible synthetic materials has been proposed. Among different types of biocompatible materials, Medpor is an interesting option for alloplasts<sup>5,13–15</sup> and irradiated rib cartilage is a feasible homograft. Therefore, we have intended to compare the results of their co-utilization in a reconstructive procedure for saddle nose deformity.

The final outcome of this research gave acceptable results with minor complications. The stability and preparation simplicity of the porous high-density polyethylene allows for satisfactory results for reconstruction of the dorsum. However, there are particular forms of the Medpor prosthesis for augmentation of the nasal tip, of which the final feature is not natural; in particular, its

unusual tip recoil causes some difficulties for patients.<sup>13,14,17</sup>

Previously, different materials such as ivory, gold, and paraffin have been used to replace lost nasal tissues; however, all failed to achieve satisfactory results. Among these, Gor-Tex materials have had varying degrees of success with specific drawbacks.<sup>3,16</sup> Unlike other materials, Medpor has numerous advantages over other materials such as less extrusion, lack of surrounding capsule formation, and stability, which provide better reconstruction results. In addition, growth of soft tissue over and into the prosthesis can cause reduced migration and infection rate of the prosthesis.<sup>1-3,5,12-16</sup>

As with a study by Romo who had to remove the Medpor implants from his infected cases,<sup>16</sup> our attempts at conservative management of the infected cases failed, which resulted in removal of the implant. Although having considered the low rate of these phenomena, Medpor can be satisfactorily used in these complicated cases.

Because of the high rate of prosthesis rejection in the tip,<sup>14</sup> we used irradiated rib cartilage for tip augmentation as the columellar strut in the routine technique.<sup>18</sup> Therefore, during the follow up periods there were no complications with its use. Our study had good projection results, which were compatible with other reports.<sup>1,7,13,14</sup>

Although we used Medpor conservatively, Kim et al. have reported the successful use of this type of graft as a spreader graft.<sup>19</sup> Therefore, in the future, surgeons most probably can safely use it in other parts of the nose.

Park et al., among others, compared the long-term effects of Medpor usage in nasal plastic surgery with other procedures in different parts of the body and had acceptable results. However, none of the authors claimed that the usual graft materials can be spared forgotten in routine nasal plastic surgeries and superseded by synthetic materials.<sup>20</sup>

The primary measurement tool in this study, Photoshop 7 software, is an efficient tool for precise and objective measurement of rhinoplasty indexes.<sup>18</sup> This can be one of the major distinctions of this study, which has shown favorable results. The significant differences in evaluated aesthetic indexes and their change towards ideal values can lead to a better understanding of the outcome measurement of this type of analysis.

Our follow up period ( $25.2 \pm 4.9$  months) seems to be adequate for preliminary reports, however, longer follow up is needed to evaluate major concerns with Medpor, extrusion, and irradiated rib cartilage, its re-absorption.<sup>15</sup> Our results cannot disclaim the use of other graft materials, such as concha or rib cartilage, and the calvarias graft as good material sources for augmentation rhinoplasty.

Correction of a saddle nose is a challenging procedure. Despite the superiority of autogenous materials in nose reconstruction, lack of safe materials in revision rhinoplasty cases present challenges to surgeons. This study proposes the safety and efficiency

of the Medpor alloplast for reconstruction of the dorsum and irradiated rib cartilage for the tip, over a short time.

## References

1. Sykes JM, Patel KG. Use of Medpor implants in rhinoplasty surgery. *Operative Techniques in Otolaryngology Head and Neck Surgery*. 2008; **19**: 273 – 277.
2. Godin M, Della Torre T. The use of expanded polytetrafluoroethylene (e-PTFE) implants in rhinoplasty. *Operative Techniques in Otolaryngology*. 2008; **19**: 285 – 289.
3. Conrad K, Gillman G. A 6-year experience with the use of expanded polytetrafluoroethylene in rhinoplasty. *Plast Reconstr Surg*. 1998; **101**: 1675 – 1683.
4. Turegun M, Acarturk TO, Ozturk S, Sengezer M. Aesthetic and functional restoration using dorsal saddle shaped Medpor implant in secondary rhinoplasty. *Ann Plast Surg*. 2008; **60**: 600 – 603.
5. Brenner MJ, Hilger PA. Grafting in rhinoplasty. *Facial Plast Surg Clin North Am*. 2009; **17**: 91 – 113.
6. Romo T, Kwak ES. Nasal grafts and implants in revision rhinoplasty. *Facial Plast Surg Clin North Am*. 2006; **14**: 373 – 387.
7. Berghaus A, Stelter K. Alloplastic materials in rhinoplasty. *Current Opinion in Otolaryngology a Head and Neck Surgery*. 2006; **14**: 270 – 277.
8. Cenzi R, Farina A, Zuccarino L, Carinci F. Clinical outcome of 285 Medpor grafts used for craniofacial reconstruction. *J Craniofac Surg*. 2005; **16**: 526 – 530.
9. Öztürk S, Sengezer M, Coskun Ü, Zor F. An unusual complication of a Medpor implant in nasal reconstruction: a case report. *Aesthetic Plast Surg*. 2002; **26**: 419 – 422.
10. Shi RJ, Jiang CY, Wu QW. Rhinoplasty with Medpor surgical implant material. *Chinese J Otorhinolaryngol Skull Base Surg*. 2006; **6**: 203 – 204.
11. Romo T, Sclafani AP, Sabini P. Use of porous high-density polyethylene in revision rhinoplasty and in the platyrrhine nose. *Aesth Plast Surg*. 1998; **22**: 211 – 221.
12. Niechajev I. Porous polyethylene implants for nasal reconstruction: clinical and histologic studies. *Aesth Plast Surg*. 1999; **23**: 395 – 402.
13. Maas C, Monhian N, Shah S. Implants in rhinoplasty. *Facial Plast Surg*. 1998; **13**: 279 – 290.
14. Sajjadian A, Naghshineh N, Rubinstein R. Current status of grafts and implants in rhinoplasty: Part II. Homologous grafts and allogenic implants. *Plast Reconstr Surg*. 2010; **125**: 99e – 109e.
15. Peled Z, Warren A, Johnston P. The use of alloplastic materials in rhinoplasty surgery: a meta-analysis. *Plast Reconstr Surg*. 2008; **121**: 85 – 92.
16. Romo T, Choe KS, Sclafani AP. Secondary cleft-lip rhinoplasty utilizing porous high-density polyethylene. *Facial Plast Surg*. 2003; **19**: 369 – 377.
17. Nolst Trenité GJ, Gilbert J. Considerations in ethnic rhinoplasty. *Facial Plast Surg*. 2003; **19**: 239 – 246.
18. Sadeghi M, Saedi B, Sazegar AA. The role of columellar struts to gain and maintain tip projection and rotation: a randomized blinded trial. *Am J Rhinol Allergy*. 2009; **23**: 223 – 229.
19. Kim YH, Kim BJ, Jang TY. Use of porous high-density polyethylene (Medpor) for spreader or extended septal graft in rhinoplasty: aesthetics, functional outcomes, and long-term complications. *Ann Plast Surg*. 2011; **67**: 464 – 468.
20. Park JY, Kim SG, Baik SM, Kim SY. Comparison of genioplasty using Medpor and osteotomy. *Oral Surg Oral Med Oral Pathol Oral Radiol Endodontics*. 2002; **109**: e26 – e30.