

Original Article

Endoscopic Cyanoacrylate Injection for the Treatment of Bleeding Gastric Varices: The First Iranian Series

Seyed Alireza Taghavi MD¹, Ahad Eshraghian MD¹, Laleh Hamidpour MD^{•1}, Mohammad Jafar Moshfe MD¹

Abstract

Background: Gastric varices are a major cause of gastrointestinal bleeding and death in patients with portal hypertension. N-butyl-2-cyanoacrylate injection is a new method for controlling bleeding gastric varices. This study aims to investigate the prognosis and complications of cyanoacrylate therapy for bleeding gastric varices.

Methods: We conducted a prospective study between May 2009 and January 2010 at our center affiliated with the Shiraz University of Medical Sciences, Shiraz, Iran. All patients with gastric variceal bleeding were enrolled in the study. N-butyl-2-cyanoacrylate injection was performed for treatment of the bleeding, and patients underwent monthly endoscopies to determine the outcomes.

Results: There were 13 patients with portal hypertension and gastric variceal bleeding included in the study. Initial hemostasis was obtained in all patients but more than one injection was needed in seven patients. Two patients developed re-bleeding and two died of advanced cirrhosis and other accompanying diseases.

Conclusion: No major complications were observed after treatment with N-butyl-2-cyanoacrylate. This method can be safely used in treatment of gastric variceal bleeding.

Keywords: Endoscopic, gastric varice, N-butyl-2-cyanoacrylate, treatment

Cite this article as: Taghavi SA, Eshraghian A, Hamidpour L, Moshfe MJ. Endoscopic Cyanoacrylate Injection for the Treatment of Bleeding Gastric Varices: The First Iranian Series. *Arch Iran Med.* 2012; **15**(3): 157 – 161.

Introduction

Gastric varices are an important cause of gastrointestinal bleeding in patients with portal hypertension. Although gastric variceal bleeding is less prevalent than bleeding from esophageal varices, it is more severe, catastrophic, and has a higher mortality.¹

Porto-systemic shunt procedures, either surgical or radiological, are considered to be the most effective to stop bleeding from gastric varices. Unfortunately in a significant proportion of the patients these procedures are either contraindicated (those with varying degrees of encephalopathy), not readily available, or difficult to perform (portal vein thrombosis).

Although the management of gastric variceal bleeding is still challenging and associated with significant morbidity and mortality rates, introduction of the N-butyl-2-cyanoacrylate injection in 1987 added a new option to the small inventory of an endoscopist's arsenal for the treatment of this condition.²

This method is, at least in emergency cases, now considered a viable option for the treatment of gastric variceal bleeding in many centers around the world.³

Several studies have been conducted to evaluate the efficacy and safety of N-butyl-2-cyanoacrylate in the treatment of gastric variceal bleeding; however, there is no report from Iran.

This is the first Iranian study on the use of N-butyl cyanoacrylate for the management of acute gastric variceal bleeding. The aim is

to evaluate complications and prognosis of our single center experience with cyanoacrylate injections, as well as to comment on our personal experiences.

Materials and Methods

Patients

All patients that presented with acute gastric variceal bleeding to educational hospitals affiliated with the Shiraz University of Medical Sciences were enrolled. The first patient was treated May 2009 and the last in January 2010.

Inclusion and exclusion criteria

All patients underwent emergency endoscopies. Gastric variceal bleeding was diagnosed using these criteria: 1) clinical signs of bleeding (hematemesis, melena, coffee ground vomiting, or hematochezia); 2) endoscopic visualization of oozing or spurting, adherent blood clots, white nipple signs, or erosions from or on the gastric varice; and 3) presence of distinct large gastric varice with a red-color sign and no other identifiable source of bleeding.^{3,4}

Patients were excluded if they had previous endoscopic, surgical treatment, or transjugular intrahepatic portal systemic shunt for gastric variceal bleeding.

Procedures were performed in the retroflexed position using an Olympus GF-Q160 endoscope (Olympus Optical Co. Ltd, Tokyo, Japan) and a 23-gauge disposable injection needle (EIS 01943, Top Co.).

Procedure

N-butyl-2-cyanoacrylate (histoacryl blue, Braun, Melsungen, Germany) intravariceal injections were used. The injections were done on actively bleeding varices and/or those with stigmata of the bleeding. No prophylactic injections on the non-bleeding varices

Authors' affiliation: ¹Department of Internal Medicine, Gastroenterohepatology Research Center, Shiraz University of Medical Sciences, Shiraz, Iran.

•Corresponding author and reprints: Laleh Hamidpour, MD, Gastroenterohepatology Research Center, Namazi Hospital, Shiraz, Iran. P.O. Box: 71345-1744, Shiraz, Iran. Tel: +98-711-647-4316, Fax: +98-711-627-6212, E-mail: hamidpourlaleh@gmail.com

Accepted for publication: 13 July 2011

Table 1. Clinical characteristics of the patients.

Number of patients	13
Age (years)	44±9
Sex (M/F)	9/4
Underlying disease	
Liver cirrhosis	12
HBV	6
HCV	3
Cryptogenic	3
Non-cirrhotic	1
Ascitis	8
Encephalopathy	0
Presentation	
Melena	13
Hematemesis	13
Hematochezia	0
Mean hemoglobin before treatment	8.5±2.1

were performed.

Each injection contained 0.5 mL cyanoacrylate and 0.5 mL Lipiodol (Guerbet Laboratory, Aulnay-Sous-Bris, France). For larger varices, particularly those which re-bled after the first injection, higher concentrations of the glue (0.6 cyanoacrylate + 0.4 cc Lipiodol) were used. No more than six injections were performed in each session. Each injection was followed by flushing with 1 cc of 5% Dextrose Water (DW) to push the glue out of the needles. The needle was retained in the lumen of the varix for 30 seconds before withdrawal to prevent uncontrollable bleeding from the injection site. The effectiveness of the injections was assessed by gently touching the injected varices with a blunt catheter. A hard fill was accepted as a sign of an effectively obliterated vessel. Protective goggles were used for the patients, endoscopist, and assistants to prevent eye damage. Continuous monitoring of the oxygen saturation was done for all patients.

A routine CXR that included the upper abdomen was taken three hours after the procedure to check for the presence of contrast material (Lipiodol) in the gastric wall as well as to rule out pulmonary emboli from the injected material.

Patients' information were collected regarding age, sex, presentation to the emergency room, vital signs, blood transfusions, causes

of portal hypertension, grade and size of the varices. The patients were followed monthly and we performed follow up endoscopies three months after initial endoscopic treatment.

Data were analyzed using SPSS software version 16.

Ethics and consent

Considering the risks associated with the procedure, a detailed discussion of the method as well as potential complications and alternative treatments was undertaken with the patients or substituted decision maker and a written informed consent was obtained for each patient.

This study was approved by the Ethics Committee of Shiraz University of Medical Sciences and conducted in accordance with the Helsinki declaration (Edinburgh revision, 2000).

Results

There were 13 patients with acute gastric variceal bleeding treated with endoscopic injection of N-butyl cyanoacrylate in our center. All of these patients had portal hypertension. Twelve patients had liver cirrhosis and one patient had idiopathic portal hypertension. Six patients had HBV related liver cirrhosis, three had cir-

Table 2. Results of n-butyl cyanoacrylate injection for gastric variceal bleeding.

Types of bleeding	
Spurting	3
Oozing	5
Fibrin cap	5
Initial hemostasis	100%, more than one injection was needed in 7 patients to completely stop the bleeding
Post treatment hemoglobin	10±1.4
Need for blood transfusion	6
Re bleeding rate	2/13
Mortality rate	2/13, one in the first admission with advanced liver disease, the second during an admission 14 months after the first bleeding, sepsis + advanced liver disease.

rhosis due to HCV infections, and three others had cryptogenic liver cirrhosis. Clinical characteristics of the patients are outlined in Table 1.

These patients were referred to our endoscopy unit with clinical signs of gastrointestinal bleeding such as melena, hematemesis, and hematochezia after upper GI endoscopy. Gastric varices were diagnosed as the source of GI bleeding. After cyanoacrylate injections, we followed the patients for re-bleeding, complications, and mortality. The median time of follow up was 16 months.

There were no immediate re-bleedings in the injected varices. However, two patients developed upper GI bleeding from new fundal varices 14 months after cyanoacrylate injection. These two patients were treated with a re-injection of cyanoacrylate. One had no re-bleeding in his follow up, but the other who was admitted at the time of the second bleeding died due to advanced cirrhosis. Two patients developed chest and abdominal discomfort for eight hours after endoscopic therapy that spontaneously resolved with no additional treatment. No sign of de-oxygenation or myocardial or mesenteric ischemia was found in these cases. Four patients underwent upper GI endoscopy about 1–2 months after injection and injected varices were found to be stable.

One of the patients died three days after cyanoacrylate injection due to advanced liver disease and acute renal failure. Results of endoscopic treatment are summarized in Table 2.

Discussion

Variceal bleeding is a potentially fatal complication of liver cirrhosis that affects an estimated 20% to 30% of cirrhotics within two years of diagnosis.⁵ Gastric variceal bleeding is responsible for nearly 10% to 20% of variceal bleeding in patients with portal hypertension.⁶

Compared to esophageal varices, bleeding from gastric varices are more severe, poorly controlled, associated with greater need for blood transfusion, and have worse outcomes.^{7,8} Sclerotherapy and band ligation have been established to be less effective in acute control of gastric variceal bleeding.⁹

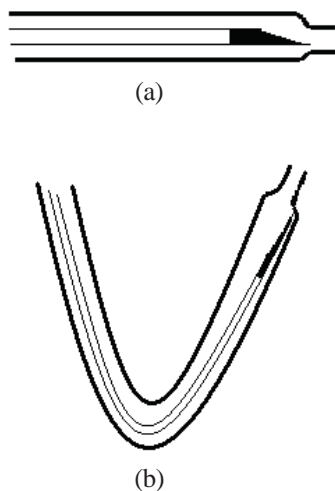


Figure 1. a) Disposable endoscopic injection needle with harrowed distal end, **b)** The same needle in the bent position (protruding from a retroverted endoscope), the narrow distal end may prevent movement of the needle catheter out of the outer sheath.

Transjugular intrahepatic portosystemic shunt (TIPS) and/or balloon-occluded retrograde transvenous obliteration are used in the treatment of gastric variceal bleeding, although they are not risk free and need a high degree of experience and expertise.¹⁰

Endoscopic injection of cyanoacrylate was first introduced by Soehendra et al. in 1986.¹¹ Afterwards, this method was utilized as the most effective endoscopic treatment for gastric variceal bleeding. Several studies were conducted to evaluate the short-term and long-term outcomes of patients treated with cyanoacrylate injection.^{12–14} Belletrutti et al. confirmed the safety of cyanoacrylate injection in the management of gastric variceal bleeding in a North American patient population.¹⁵ Another large group of Chinese patients showed the effectiveness of this method.¹⁶

Other studies compared cyanoacrylate injection versus TIPS in the management of bleeding gastric varices.¹⁷ Procaccini et al. reported less long-term morbidity in patients treated with cyanoacrylate compared to patients treated with TIPS insertion.¹⁸ The re-bleeding rate was lower in gastric variceal bleeding treated with cyanoacrylate injection compared to those managed with band ligation.¹⁹ The superiority of cyanoacrylate injection over band ligation was also confirmed in another study by Lo et al.²⁰

The success rate of controlling gastric variceal bleeding by endoscopic injections of cyanoacrylate appeared higher than other sclerosing agents according to previous trials.^{21,22} A recent study showed that endoscopic cyanoacrylate injection was similar to balloon-occluded retrograde transvenous obliteration (BRTO) in treatment of active gastric variceal bleeding, but the re-bleeding rate was lower in the BRTO group.²³ They concluded that BRTO could be a rescue method after initial treatment with cyanoacrylate injection.

These studies have suggested that endoscopic injection of cyanoacrylate is effective and safe for treating gastric variceal bleeding. Yet, there are some complications that must be considered. Infective endocarditis,²³ adhesive extrusion resulting in a bleeding ulcer and subsequent hemorrhagic shock,²⁴ encephalopathy after the procedure,¹⁸ superior mesenteric vein thrombosis,¹⁵ fever, and infection¹⁹ are among complications of endoscopic injections of cyanoacrylate. There is also a case report of life threatening pericarditis after cyanoacrylate injection for the treatment of esophageal varices.²⁵

Our methodology is different in a few aspects from previous experiences with cyanoacrylate injection for the varices. Instead of flushing with Lipiodol contrast, we used 5% DW. The main reason for this change is the high viscosity of the contrast medium, which makes the injection difficult and lengthy. With the substitution of 5% DW, we were able to flush the catheter much more rapidly, and we did not encounter any problems with occlusion of the catheters or higher rebleeding rates.

Several previous guidelines and articles have suggested using metallic spiral needles exclusively for the injection of the glue,¹⁸ mainly due to concerns for possible interaction of the glue with the catheter and rapid occlusion. We used the usual plastic disposable catheters, which are cheaper and more readily available. The only point that must be considered when using these catheters is that many of them had a narrowed funnel shaped end, which may prevent the movement of the needle when the needle is used in a retroverted position. An easy solution is to cut the narrowed end and measure the desired length of the movement in the handle to give the optimal length of needle protrusion at the injection time

(Figure 1).

Excellent coordination between the endoscopist and assistants is a necessary considering the time sensitivity of the procedure. The protocol for needle insertion, injection of the glue, flushing, and withdrawal should be carefully reviewed and understood by all parties involved. We also recommend measuring the volume of the fluid necessary to fill the needle's lumen before the procedure to prevent injection of an unnecessarily large volume of 5% DW, which may potentially dilute the glue.

The possibility of a need for replacement of the catheter (occlusion) or the need for additional injections to prevent catastrophic bleeding should be considered and equipment and glue should be available at the bedside.

Since blood usually pools in the fundus, which may potentially occlude the view of the varices, a change in the position of the patient for better visualization, or to obtain a better injection angle, is a frequent occurrence. Careful planning to protect the patient's airways is mandatory. The necessity for prophylactic endotracheal intubation should be considered in all patients.

Blood oozing from the site of injection is frequent and should not be interpreted as a need for further treatment unless it is severe or does not stop after a few minutes of observation.

Despite the fact that adhesion of the needle and/or scope to the varices is highly unlikely, the fear of this happening usually promotes a sooner withdrawal of the needle from the varice, which may potentially increase the bleeding from the injection site. Use of a chronometer and a preset time for withdrawal will prevent this problem.

Based on excellent results, cyanoacrylate injection for the management of gastric variceal bleeding is rapidly growing. Our report on the 13 patients with gastric variceal bleeding is the first report from Iran. No major complications were observed among our patients and all developed initial homeostasis after the successful procedures. We conclude that this method can be safely used in patients with gastric variceal bleeding.

Conflict of interest: *Nothing to declare.*

References

1. Helmy A, Hayes PC. Current endoscopic therapeutic options in the management of variceal bleeding. *Aliment Pharmacol Ther.* 2001; **15**: 575 – 594.
2. Soehendra N, Grimm H, Nam VC, Berger B. N-butyl-2-cyanoacrylate: A supplement to endoscopic sclerotherapy. *Endoscopy.* 1987; **19**: 221 – 224.
3. Ramond MJ, Valla D, Mosnier JF, Degott C, Bernuau J, Rueff B, et al. Successful endoscopic obturation of gastric varices with butyl cyanoacrylate. *Hepatology.* 1989; **10**: 488 – 493.
4. Hou MC, Lin HC, Kuo BI, Lee FY, Schmidt CM, Lee SD. Clinical implications of the white nipple sign and its role in the diagnosis of esophageal variceal hemorrhage. *Am J Gastroenterol.* 1996; **91**: 2103 – 2109.
5. de Francis R, Primignani M. Natural history of portal hypertension in patients with cirrhosis. *Clin Liver Dis.* 2001; **5**: 645 – 663.
6. Ryan BM, Stockbrugger RW, Ryan JM. A pathophysiologic, gastroenterologic, and radiologic approach to the management of gastric varices. *Gastroenterology.* 2004; **126**: 1175 – 1189.
7. Trudeau W, Prindiville T. Endoscopic injection sclerotherapy in bleeding gastric varices. *Gastrointest Endosc.* 1986; **32**: 264 – 268.
8. Chey WD, Elta GH. Natural history of gastric varices. *Gastroenterology.* 1993; **105**: 599 – 602.
9. Sarin SK, Lahoti D, Saxena SP, Murthy NS, Makwana UK. Prevalence, classification and natural history of gastric varices: a long-term follow-up study in 568 portal hypertensive patients. *Hepatology.* 1992; **16**: 1343 – 1349.
10. Matsumoto A, Takimoto K. Gastric fundal varices: new aspects of

nonsurgical treatment in Japan. *Nat Clin Pract Gastroenterol Hepatol.* 2006; **3**: 4 – 5.

11. Soehendra N, Nam VC, Grimm H, Kemperneers I. Endoscopic obliteration of large oesophageal gastric varices with bucrylate. *Endoscopy.* 1986; **18**: 1825 – 1826.
12. Kind R, Gugliemi A, Rodella L, Lombardo F, Catalano F, Ruzzenente A, et al. Bucrylate treatment of bleeding gastric varices: 12 years' experience. *Endoscopy.* 2000; **32**: 512 – 519.
13. Greenwald BD, Caldwell SH, Hespeneheide EE, Patrie JT, Williams J, Binmoeller KF, et al. N-2-butyl cyanoacrylate for bleeding gastric varices, a United States pilot study and cost analysis. *Am J Gastroenterol.* 2003; **98**: 1982 – 1988.
14. Rengstorff DS, Binmoeller KF. A pilot study of 2-octyl cyanoacrylate injection for treatment of gastric fundal varices in humans. *Gastrointest Endosc.* 2004; **59**: 553 – 558.
15. Belletrutti PJ, Romagnuolo J, Hilsden RJ, Chen F, Kaplan B, Love J, et al. Endoscopic management of gastric varices: efficacy and outcomes of gluing with N-butyl-2-cyanoacrylate in a North American patient population. *Can J Gastroenterol.* 2008; **22**: 931 – 936.
16. Cheng LF, Wang ZQ, Li CZ, Cai FC, Huang QY, Linghu EQ, et al. Treatment of gastric varices by endoscopic sclerotherapy using butyl cyanoacrylate: 10 years' experience of 635 cases. *Chin Med J (Engl).* 2007; **120**: 2081 – 2085.
17. Mahadeva S, Bellamy MC, Kessel D, Davies MH, Millson CE. Cost effectiveness of n-butyl-2-cyanoacrylate (Histoacryl) glue injections versus transjugular intrahepatic portosystemic shunt in the management of acute gastric variceal bleeding. *Am J Gastroenterol.* 2003; **98**: 2688 – 2693.
18. Procaccini NJ, Al-Osaimi AM, Northup P, Argo C, Caldwell SH. Endoscopic cyanoacrylate versus transjugular intrahepatic portosystemic shunt for gastric variceal bleeding: A single-center U.S. analysis. *Gastrointest Endosc.* 2009; **70**: 881 – 887.
19. Tan PC, Hou MC, Lin HC, Liu TT, Lee FY, Chang FY, et al. A randomized trial of endoscopic treatment of acute gastric variceal hemorrhage: N-butyl-2-cyanoacrylate injection versus band ligation. *Hepatology.* 2006; **43**: 690 – 697.
20. Lo GH, Lai KH, Cheng JS, Chen MH, Chiang HT. A prospective, randomized trial of butyl cyanoacrylate injection versus band ligation in the management of bleeding gastric varices. *Hepatology.* 2001; **33**: 1060 – 1064.
21. Oho K, Iwao T, Sumino M, Toyonaga A, Tanikawa K. Ethanolamine oleate versus butyl cyanoacrylate for bleeding gastric varices: A non-randomized study. *Endoscopy.* 1995; **27**: 349 – 354.
22. Kitano S, Wada H, Yamaga H, Hashizume M, Koyanagi N, Iwanaga T, et al. Comparative effects of 5% ethanolamine oleate versus 5% sodium morrhuate for sclerotherapy of oesophageal varices. *J Gastroenterol Hepatol.* 1991; **6**: 476 – 480.
23. Hong CH, Kim HJ, Park JH, Park DI, Cho YK, Sohn CI, et al. Treatment of patients with gastric variceal hemorrhage: Endoscopic N-butyl-2-cyanoacrylate injection versus balloon-occluded retrograde transvenous obliteration. *J Gastroenterol Hepatol.* 2009; **24**: 372 – 378.
24. Marques P, Maluf-Filho F, Kumar A, Matuguma SE, Sakai P, Ishioka S. Long-term outcomes of acute gastric variceal bleeding in 48 patients following treatment with cyanoacrylate. *Dig Dis Sci.* 2008; **53**: 544 – 550.
25. Chen YY, Shen TC, Soon MS, Lai JH. Life-threatening pericarditis after N-butyl-2-cyanoacrylate injection for esophageal variceal bleeding: Case report. *Gastrointest Endosc.* 2005; **61**: 487 – 489.

Appendix 1

Practical guide for injection of cyanoacrylate for treatment of gastric variceal bleeding.

- Obtain informed consent by explaining the success rate, risks, possible complications, and alternatives to the procedure.
- Think of possible aspiration risk and necessity for prophylactic incubation for airway protection.
- Review the sequence of the procedure and terminology for blunt touching, puncture, injection of the glue, and flushing with your assistant.
- Measure the volume needed to fill the sclerotherapy needle by injecting 5% DW until it spills from the end (the usual volume is about 0.8 to 1 mL).

- Cut the narrow distal end of the needle with a knife (do not use scissors) if necessary. If you cut the distal end, make sure how much the assistant should push the handle in to protrude the appropriate length of the needle out of the sheath.
- Prepare and label at least three pre-filled syringes with the mixture of cyanoacrylate and Lipiodol, also prepare three syringes filled with required volume of 5% DW and label all syringes in sequence.
- Further glue and additional needles should be readily available at the bedside.
- Use protective goggles for yourself, the patient, assistant, and anyone standing around the bed.
- Although any endoscope can be used, a large channel scope with elevator in the working channel will greatly facilitate the process.
- Always re-evaluate the esophageal varices as the more common source of bleeding
- After finding the culprit vessel (which should be treated first), try to find the best position for the scope which is both stable and enables the varix to be punctured as perpendicularly as possible.
- Test the trajectory of the needle with a closed catheter.
- Puncture the vessel with a direct hit of the needle (i.e.: the needle should be out of the sheath for you to see the puncture, don't do the puncture by putting the end of the closed needle on target and then pushing the needle out, you may inject the glue to the lumen or submucosally this way).
- Inject the glue and immediately flush with predetermined volume of 5% DW.
- Keep the needle in the vessel for at least 30 seconds and then withdraw. Close the needle, withdraw it from the working channel, and flush with large amount of air if it is going to be reused. Be careful about possible late occlusion of an already used needle.
- Expect some oozing or bleeding and be prepared to flush or clear the field with suction.
- More than one injection is usually needed to obliterate a serpentinuous or large vessel.
- Touch the injected vessel gently with the tip of a blunt catheter to make sure that the lumen is obliterated.